

# From Diabetes to Dialysis: Exploring the Acute Complications of Uncontrolled Pediatric Type 2 Diabetes during the COVID-19 Pandemic

Natalie Bush, MS<sup>3</sup>, Aniko Nowakowski, MS<sup>3</sup>, James Gardner, MD<sup>1,2</sup>, Daniel S. Hsia, MD<sup>1,2,3</sup>  
1- LSU-NO School of Medicine 2- OLOL Children's Hospital 3- Pennington Biomedical Research Center

## Introduction

- The COVID-19 pandemic led to severe, acute presentations of chronic disease not only in adults but also in children due to the strained healthcare system and limited access to routine care.
- Pediatric patients with type 2 diabetes (T2DM) rarely present with associated acute kidney injury (AKI) severe enough to require dialysis.
- Diabetes accounts for only 0.1% of end-stage renal disease (ESRD) in children and adolescents.
- This case series explores two patients with new-onset T2DM who developed severe AKI requiring dialysis at OLOL Children's Hospital in 2021.

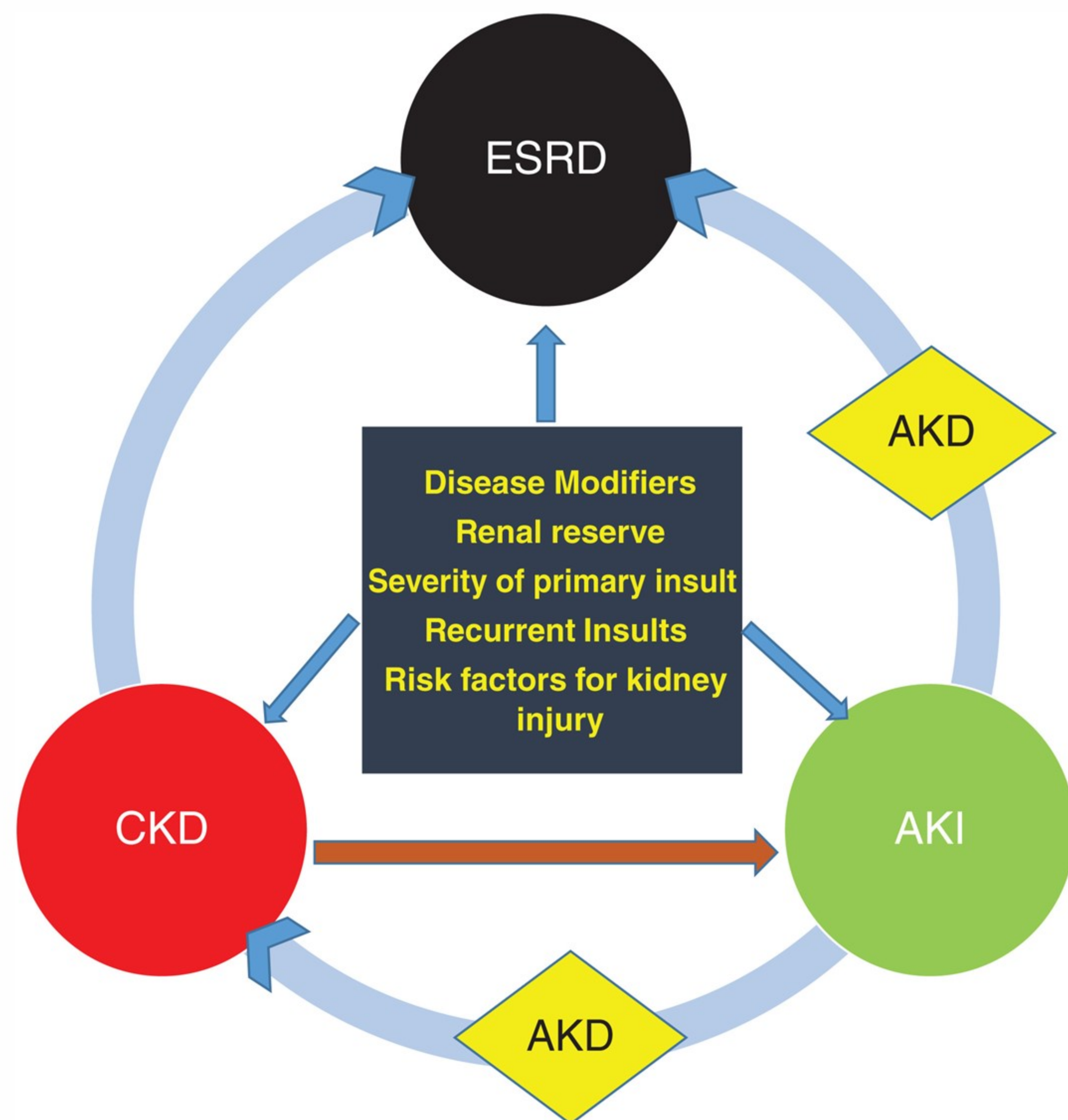


Figure 1. Renal outcomes after an episode of AKI. Nephrology, Vol: 23, Issue: 11, Pages: 969-980, 27 May 2018

## Case Presentations

### Patient 1:

- In April 2021, a 14-year-old female with a history of obesity (BMI= 43.1 kg/m<sup>2</sup>) presented with hyperglycemia and diabetic ketoacidosis associated with several episodes of emesis, fatigue, and polydipsia for two days.
- In the ED she was tachycardic (128 BPM) and tachypneic (RR= 36). Her initial labs are shown in **Table 1**. She was started on IV fluids and insulin and admitted to the ICU.
- She had worsening acute kidney injury (Cr 2.77 mg/dL) and began continuous renal replacement therapy (CRRT) on day 2. She remained intubated for the first week of dialysis due to poor respiratory status. She received intermittent dialysis treatments starting on day 8 until day 15 (**Figure 2**).
- She was discharged home on hospital day 30 with amlodipine and insulin.
- At her nephrology follow-up 11 days later, BUN/Cr was 8 mg/dL/0.74 mg/dL, and she reported adherence to her medications.
- Now two years later, she has a HbA1c of 5.6% on Victoza. She is followed by her PCP, a pediatric endocrinologist, and a pediatric nephrologist.

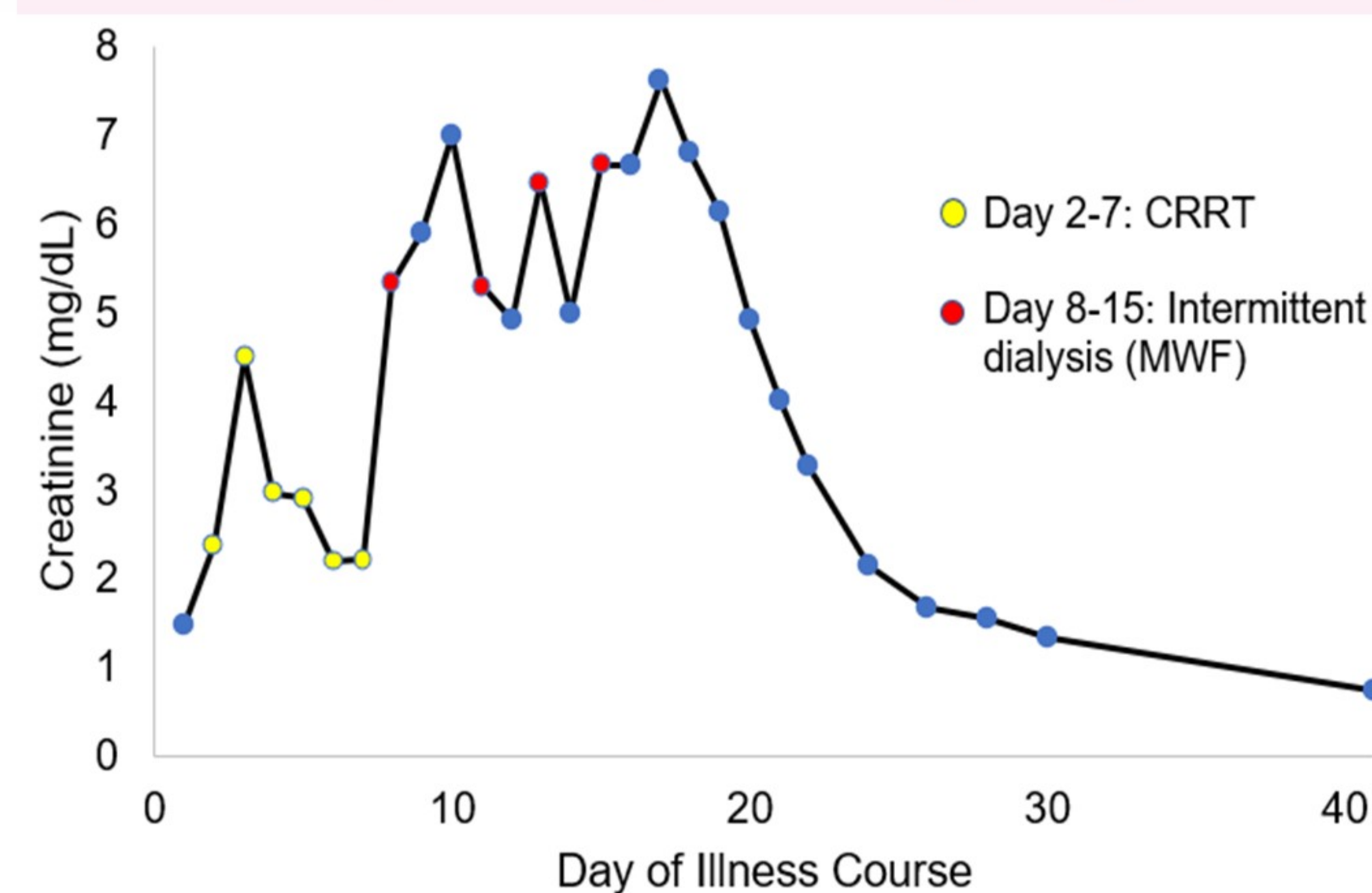


Figure 2. Patient 1's creatinine over their illness course.

### Patient 2:

- In January 2021, a 16-year-old female with history of obesity (BMI=46.1 kg/m<sup>2</sup>), metabolic syndrome, and recent COVID-19 infection (2 months prior to presentation) presented with DKA and hyperosmolar hyperglycemic syndrome (HHS).
- Her initial labs are shown in **Table 2**. CT scan of the abdomen and pelvis showed acute necrotizing pancreatitis. Despite fluid administration, creatinine continued to increase (6.1 to 7.2 mg/dL) and urine output (UOP) was minimal (<50 mL).
- The patient required intubation and mechanical ventilation. CRRT was initiated on day 3 due to significant renal failure and electrolyte derangements. She received sustained low-efficiency dialysis (SLED) from day 10-21 before transitioning to intermittent dialysis (**Figure 3**).
- Over the course of her 46-day hospitalization, renal function gradually improved and dialysis was discontinued on day 29. She was discharged on amlodipine, gabapentin, and insulin.
- Four months after discharge, she was started on lisinopril for HTN. She is followed by pediatric nephrology and endocrinology. Her blood sugars continue to remain elevated, and the patient reports occasional non-adherence to medications.

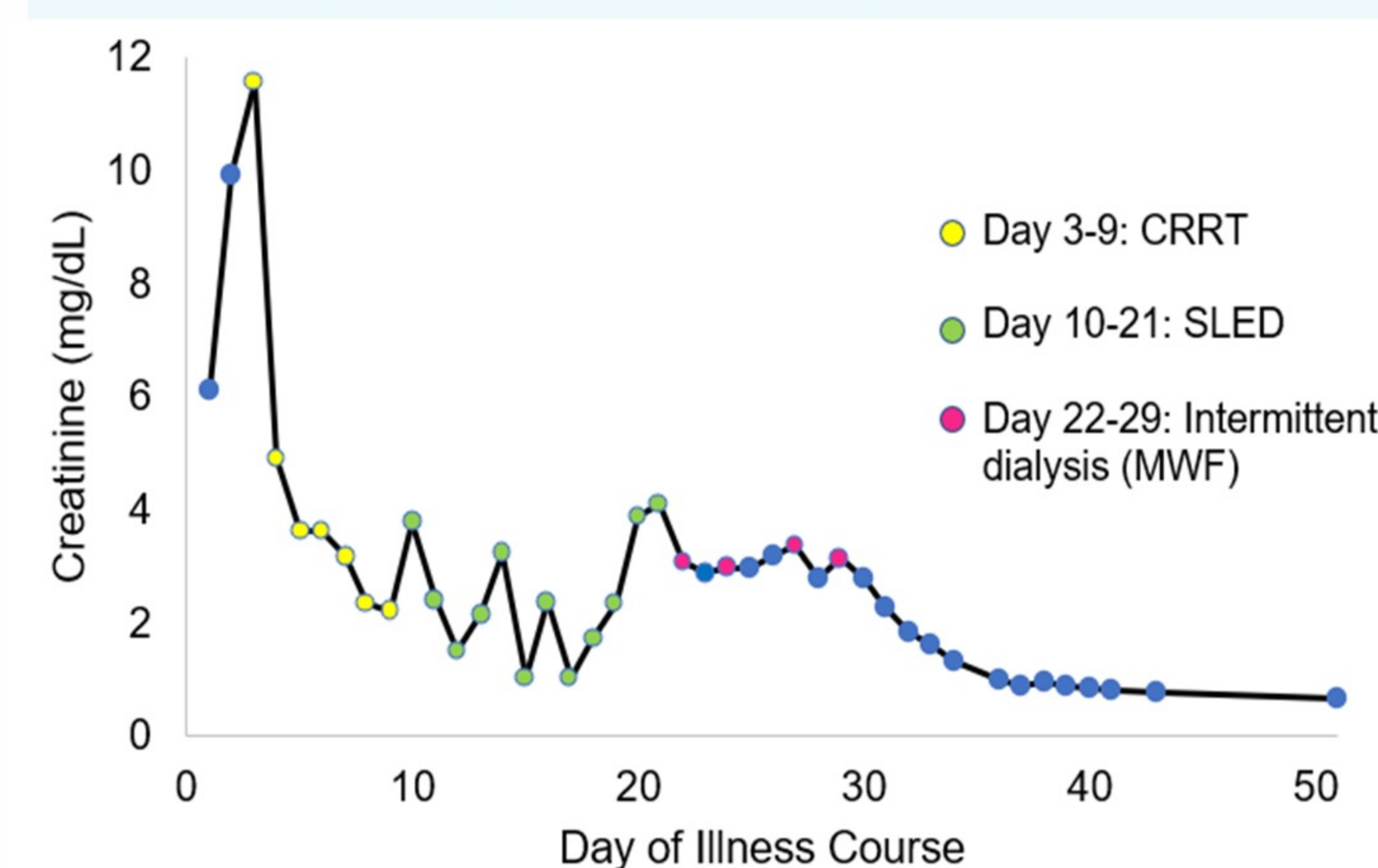


Figure 3. Patient 2's creatinine over their illness course.

## Discussion & Conclusion

- Severe AKI may be related to delayed presentation of DKA or HHS.
- These cases include severe presentations of acute complications in two children with type 2 diabetes during the COVID-19 pandemic.
- Their clinical course shows the importance of swift management of AKI to change the course of diabetic kidney disease (DKD) (**Figure 1**).
- These cases highlight the importance of provider awareness for the need for dialysis in managing pediatric patients with severe presentations of DKA or HHS.

Table 1. Patient 1's significant lab values at presentation.		Table 2. Patient 2's significant lab values at presentation.	
Amylase	723 U/L	Amylase	1231 U/L
Lipase	3901 U/L	Lipase	4274 U/L
Glucose	493 mg/dL	Glucose	>2000 mg/dL
pH	6.852	pH	7.080
HCO <sub>3</sub>	<5 mmol/L	HCO <sub>3</sub>	9 mmol/L
AST	74 U/L	AST	20 U/L
ALT	104 U/L	ALT	27 U/L
BUN	16 mg/dL	BUN	45 mg/dL
Creatinine	1.47 mg/dL	Creatinine	6.1 mg/dL
HbA1c	12.0%	HbA1c	12.3%
Triglycerides	392 mmol/L	Triglycerides	563 mmol/L

## References

- Dart AB, Sellers EA, Dean HJ. Kidney disease and youth onset type 2 diabetes: considerations for the general practitioner. *Int J Pediatr.* 2012;2012:237360. doi: 10.1155/2012/237360. Epub 2012 Jan 18.
- Rangaswamy D, Sud K. Acute Kidney injury and disease: Long-term consequences and management. *Nephrology*, Vol: 23, Iss: 11, Pages: 969-980, 27 May 2018. <https://doi.org/10.1111/nep.13408>.
- Parajuli, Biraj DM; Kumar Angurana, Suresh DM, FCCP, FIMSA; Baalaaji, Mullai DM; Williams, Vijai DM. Acute Kidney Injury in Children With Diabetic Ketoacidosis: A Real Concern. *Pediatric Critical Care Medicine*, Jun 2019;20(6):p 590-591.
- Donaghue KC, Chiarelli F, Trotta D, Allgrove J, Dahl-Jorgensen K. Microvascular and macrovascular complications associated with diabetes in children and adolescents. *Pediatric Diabetes.* 2009;10(12):195-203.
- Copeland KC, Zeitler P, Geffner M, et al. Characteristics of adolescents and youth with recent-onset type 2 diabetes: the TODAY cohort at baseline. *Journal of Clinical Endocrinology and Metabolism.* 2011;96(1):159-167.