

## Introduction

Pediatric femur fractures are the most common orthopedic surgery requiring hospitalization along with monitoring for 12-24 months after discharge (Kamienki). Flexible intramedullary nailing is a common technique for the treatment of pediatric femur fractures. Flexible IM nailing has yielded shorter time to weight bearing (as tolerated) and return to activity when compared to spica casting and external fixation (Barlas, Buechsenschuetz, Flynn). Two flexible IM nails are inserted approximately 2.5 cm above the distal femoral physis through the cortical bone into the medulla. These nails are passed through the medulla in either an C- or S-shaped configuration (Hosalkar). These configurations produce three points of fixation: the proximal nail crossing, the maximal point of separation, and the distal nail crossing. Literature specifies that the point of maximal nail separation should be at the fracture site to provide the best fixation.

Two aspects of the surgical technique have been emphasized: canal fill and nail contour/separation at the fracture site. The combined diameter of the two IM nails have been proposed to fill 80% of the canal to decrease malunion rates (Maher), but a recent article showed no increase in malunion rate between canal fill rates between 60-80% (Shaha). No previous studies have assessed the importance of nail contour and/or nail separation at the fracture site.

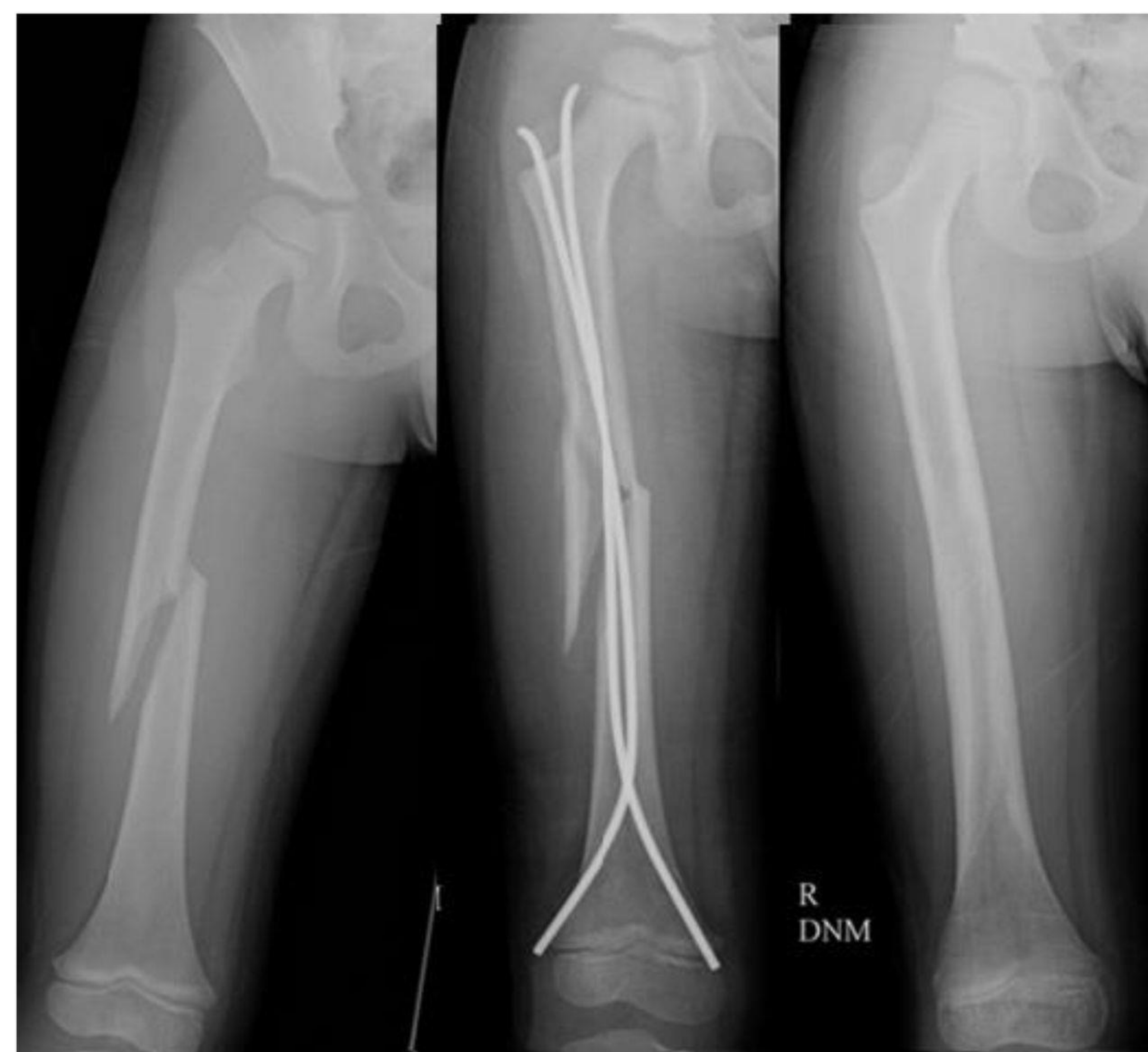The purpose of this study was to compare outcomes of pediatric femur fractures that had maximal nail separation at the fracture site to those that did not have maximal nail separation at the fracture site. We hypothesize that fractures with maximal nail separation at the fracture site will show callus formation earlier, have a lower rate of malunion, have a lower rate of nonunion and refracture, have less change in angulation postoperatively, have lower rates of supplemental casting, and have faster weight bearing and return to activities compared to fractures not located at the site of nail separation. We also hypothesize that most pediatric femur fractures treated with flexible nails will not fulfil the recommended nail morphology in the described technique and that midshaft fractures will be located at the site of maximal nail separation more often than fractures in the proximal third and/or distal third.

## Methods

A retrospective chart review was conducted of 101 pediatric patients who underwent IM nailing for femur fractures. Patient outcomes were separated based on distance of maximal nail separation in regard to fracture site. A univariate analysis was performed by dividing the cohort into three separate groups based on maximal nail separation relative to the fracture site (distal to site, at fracture site, and proximal to site). Outcomes such as surgery length, length of hospitalization, time to callus formation, time to weight bearing, malunion rate, nonunion rate, refracture, and unplanned return to OR were compared.

## Surgical Outcomes

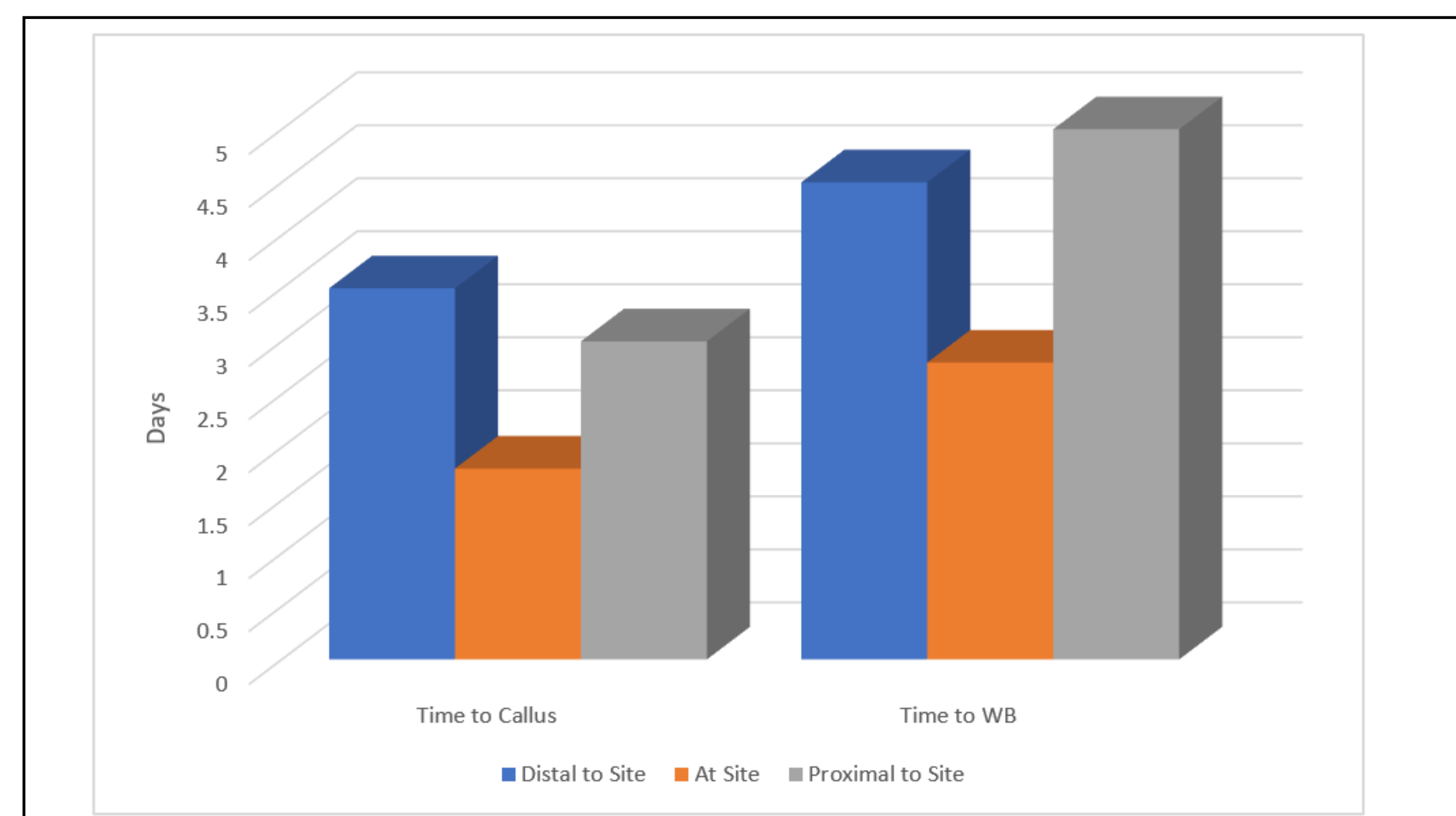
	Distal to Site (n = 55)	At Site (n = 32)	Proximal to Site (n = 14)	p-values
Casted (rate percentage)	16.4	15.6	57.1	0.003
Surgery Length (min)	103	83	114	0.034
Time to Callus (days)	34	27	29	0.140
Time to Weight Bearing (days)	35	30	33	0.609



## Surgical Technique

While intramedullary nailing of adult femur fractures utilizes one rigid nail, pediatric femur fractures require two flexible intramedullary nails in order to protect the patent growth plate. The nails are crossed in an S-configuration with the maximum point of nail separation over the fracture site. This S-configuration forms three sites of tension: the proximal nail crossing, the point of maximum nail separation, and the distal nail crossing. These three sites of tension are not achieved when the point of maximum nail separation is not at the fracture site.

## Surgical Outcomes: Time to Callus Formation and Time to Weight Bearing



## Conclusions

IM nailing with maximal nail separation at the fracture site in pediatric femur fractures is associated with shorter times in the operating room along with lower postoperative casting rates. However, it is not related to avoidance of postoperative complications such as malunion, nonunion, or refracture rates. Nor is it related to postoperative goals such as quicker callus formation or time to weight-bearing. These findings suggest that IM nailing with maximal nail separation may be preferable in regard to shorter operations and avoidance of casting.

## References

- Barlas K, Beg H: Flexible intramedullary nailing versus external fixation of paediatric femoral fractures. *Acta Orthop Belg* 2006;72(2):159-163. 7.
- Buechsenschuetz KE, Mehlman CT, Shaw KJ, Crawford AH, Immerman EB: Femoral shaft fractures in children: Traction and casting versus elastic stable intramedullary nailing. *J Trauma* 2002; 53(5):914-921. 8.
- Flynn JM, Luedtke LM, Ganley TJ, et al: Comparison of titanium elastic nails with traction and a spica cast to treat femoral fractures in children. *J Bone Joint Surg Am* 2004;86(4):770-777.
- Hosalkar HS, Pandya NK, Cho RH, Glaser DA, Moor MA, Herman MJ. Intramedullary nailing of pediatric femoral shaft fracture. *J Am Acad Orthop Surg*. 2011 Aug;19(8):472-81. doi: 10.5435/00124635-201108000-00003. PMID: 21807915.
- Kamienki MC. Pediatric Femur Fractures. *Orthop Nurs*. 2020 Mar/Apr;39(2):107-111. doi: 10.1097/NOR.0000000000000641. PMID: 32218005.
- Mahar A, Sink E, Faro F, et al. Differences in biomechanical stability of femur fracture fixation when using titanium nails of increasing diameter. *J Child Orthop*. 2007;1:211-215.
- Shaha JS, Cage JM, Black SR, Wimberly RL, Shaha SH, Riccio AI. Redefining Optimal Nail to Medullary Canal Diameter Ratio in Stainless Steel Flexible Intramedullary Nailing of Pediatric Femur Fractures. *J Pediatr Orthop*. 2017;37(7):e398-e402. doi:10.1097/BPO.0000000000001064