

# Neurosyphilis, Lymphogranuloma Venereum, and *N. Gonorrhoea* reveal importance of appropriate STI testing and follow-up

Sarah Corley (MS3), Caila Knighton (MS3), Hope Oddo Moise, MD.  
Section of Infectious Diseases, Department of Internal Medicine, LSU School of Medicine, New Orleans, LA.



## Introduction

Sexually transmitted infections are an incredibly significant public health concern. Throughout 2020, there were over two million cases of chlamydia, gonorrhea and syphilis alone reported in the United States [1]. This is despite large infrastructures devoted to both public education and provider education of proper screening and testing.

Part of decreasing the number of sexually transmitted infections in our communities lies heavily in appropriate screening. The CDC acknowledges that it is very important to perform comprehensive STI screening at all possible contact locations regardless of condom use including genital, anal and oropharyngeal sites in patients who present with a sexually transmitted infection. [1] Three of the most tested for and therefore reported STI's include Chlamydia, Gonorrhea and Syphilis. All of these are important to diagnose early on as the infections can have dangerous sequelae if allowed to progress.

*Chlamydia trachomatis* screening recommendations via nucleic acid amplification tests (NAAT) are considerably broad and tend to prioritize resources towards females including, for example, screening any female under the age of 25 that is sexually active and screening females over 25 with increased risk. Regarding males, there is little evidence for screening men who have sex with women; however, it is suggested to annually screen men who have sex with men at all contact sites regardless of condom use in addition to screening every three to six months if the patient is at increased risk. [1] Females are prioritized due to various critical outcomes associated especially with serovars D-K including pelvic inflammatory disease, ectopic pregnancies and even infertility. Fortunately, adequate screening programs have been shown to decrease the rate of adverse events such as pelvic inflammatory disease. [2]

Furthermore, a subtype of *C. trachomatis* called Lymphogranuloma Venereum (LGV) caused by serovars L1, L2, and L3 can also be detected via NAAT. There are specific tests via PCR to distinguish LGV from other serovars of *Chlamydia trachomatis*; however, they are not widely available and slower than NAAT testing. This subtype presents differently from serovars D-K in that the presentation is generally more severe, and therefore diagnosis of LGV versus other serovars of *C. trachomatis* is based off of the degree of symptoms. Some more mild symptoms include a painless genital ulcer and painful inguinal lymphadenopathy. More intense symptoms include anal LGV commonly presenting as severe proctocolitis especially in men who have sex within communities of high HIV prevalence. [3]

*Neisseria gonorrhoea* has very similar screening guidelines as *C. trachomatis* including NAAT screening of any female under the age of 25 that is sexually active, screening females over 25 with increased risk and screening men who have sex with men at least yearly and if at increased risk then every three to six months [1]. *N. Gonorrhoea*, like *C. trachomatis* can cause pelvic inflammatory disease in females if left untreated. [4]

Both *N. Gonorrhoea* and *C. Trachomatis* are tested for via NAAT of swabbed contact areas including oral, rectal and genital sites [1]. Often for routine screening, these swabs are done via the patient. As such, appropriate swabbing technique and location is important.

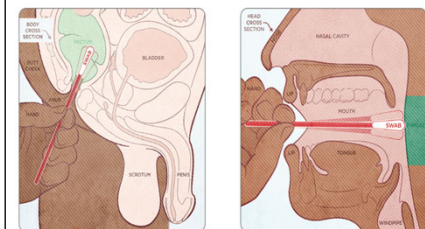


Figure 1: An example of a pamphlet given to patients demonstrating the appropriate locations to swab for STI's during routine screening. [6]

Syphilis, which is caused by *Treponema pallidum*, has screening which is recommended for all women at increased risk, all men who have sex with women that are at increased risk and men who have sex with men at least yearly and, if at an increased risk, then every three to six months. Syphilis screening is also recommended for all pregnant women at the first prenatal visit due to the severe congenital ramifications [1]. The symptoms and manifestations of syphilis depend largely upon the stage of infection. In primary syphilis, patients often present with a painless genital chancre. Secondary syphilis manifests as a maculopapular rash characteristically involving the palms and soles and condyloma lata. Tertiary syphilis has very severe symptoms including gummas, aortitis, and neurosyphilis which has various clinical manifestations including ocular syphilis and otosyphilis. Importantly, neurosyphilis can occur at any stage of syphilis [5].

In order to diagnose syphilis, both a non-treponemal and a treponemal test must be attained in order to avoid false positives and negatives. Examples of non-treponemal tests are Venereal Disease Research Laboratory (VDRL) or rapid plasma regain (RPR). Examples of treponemal tests are T. pallidum passive particle agglutination (TP-PA) and Fluorescent Treponemal Antibody-Absorption (FTA-Abs). Non-treponemal tests can be followed for response to disease treatment. Often, the treponemal tests will stay positive for life. If a non-treponemal test is negative and treponemal if positive, the patient should not be treated unless the patient has had a risk for re-infections since treatment. If both non-treponemal and treponemal tests are negative, then the patient does not need to be treated. [5]

## Patient Presentation

A 38-year-old male presented to the emergency department with complaints of a painful penile ulcer for four weeks. Upon further review of systems the patient also noted right-sided hearing loss (chart review revealed patient had been following with audiology for several months for new onset sensorineural hearing loss), paresthesia, blurry vision and painful inguinal lymphadenopathy. Notably, six months prior to presentation, the patient was diagnosed with secondary syphilis due to a diffuse maculopapular rash and clinically treated with IM penicillin; however, RPR titers post-treatment were not ordered. One week before ED presentation, the patient visited his primary care physician and had a urine PCR screening for STIs. His testing returned positive for Chlamydia, and he was treated with azithromycin.

Regarding the patient's past medical history, the patient has a history of back surgery and liposuction. The patient is sexually active with two male partners, and he endorses insertive penetrative sex with consistent condom use as well as oral sex. The patient's current medications included Truvada for pre-exposure prophylaxis, terbinafine and hydrocortisone cream for genital itching.

The patient was admitted to the inpatient medicine team, at which time RPR titers were found to be 1:128 which was the same result as titers before treatment of his secondary syphilis six months ago. Due to the titer results and concerning neurological symptoms, neurosyphilis was suspected and a lumbar puncture was ordered which showed zero white blood cells, five red blood cells, 37 mg/dL of protein, and 54 mg/dL of glucose. An MRI was also ordered which incidentally showed a 5x5x5 mm lesion slightly infringing on the left optic nerve consistent with a microadenoma or Rathke cleft cyst. Due to the patient's complaints of blurry vision, ophthalmology was consulted and upon examination appreciated only mild horizontal right gaze nystagmus but did not appreciate any other signs of ocular syphilis or Argyll Robertson pupils.

In regard to the patient's chronic right sided sensorineural hearing loss, the patient had been diagnosed with Meniere's disease previously. The patient had been prescribed hydrochlorothiazide/triamterene without improvement, and then he was lost to follow-up in the ENT clinic. Due to the patient's confounding neurological symptoms, the diagnosis of otosyphilis was suspected, and IV penicillin G was given for fourteen days. After treatment, both the patient's hearing loss and right gaze nystagmus recovered.

During workup, the patient was also tested for various sexually transmitted infections including HIV, Gonorrhea, and Chlamydia at the ulcer, rectal and pharyngeal sites. The ulcer showed a positive PCR for Chlamydia and in combination with the tender inguinal lymphadenopathy, was diagnosed as lymphogranuloma venereum. The patient was appropriately treated with doxycycline for three weeks. While awaiting PCR results of the ulcer for HSV, the patient was also treated empirically for HSV with valacyclovir for seven days though the PCR eventually returned as negative after treatment was completed. Furthermore, NAAT testing of a rectal swab revealed rectal Gonorrhea which was treated with ceftriaxone intramuscularly.

## Treatment Recommendations

The recommendations for syphilis treatment depend upon the stage of disease in which the patient presents. For primary or secondary syphilis, it is appropriate to treat the patient with 2.4 million units of penicillin intramuscularly. This is also the appropriate treatment for early latent syphilis. For tertiary and late latent syphilis, the patient can be treated with 2.4 million units of penicillin intramuscularly for 3 doses, each one week apart. For neurosyphilis, ocular syphilis, or otosyphilis patients should be treated with two weeks of IV penicillin G. [5]

Following treatment of syphilis, the CDC recommends monitoring of a nontreponemal to assess treatment efficacy. Titers should show at least a four fold decrease after treatment in order to confirm adequate clearance. It is important to note that the nontreponemal test utilized must be the same one used prior to treatment. If serologic tests are indicating that treatment was not effective, it is appropriate to presumptively treat again, especially if the patient has persistent risk factors for acquiring syphilis. [5]

The recommendation for chlamydia treatment is doxycycline for 7 days. There has been a fairly recent shift away from using single dose Azithromycin as treatment due to elevated levels of resistance. Following treatment of chlamydia, the CDC does not suggest routine re-testing to check for clearance of infection for various reasons including concern for false positives and misinterpretation of effectiveness of antibiotics in the face of continual re-infection. [2]

The recommendations for treatment of LGV differ slightly in that the treatment is doxycycline for 21 days. Furthermore, three months after treatment the CDC recommends that patient should be re-tested for chlamydia to ensure adequate treatment. If the patient cannot follow up in three months, the patient should be tested at the next earliest visit within a year. [3]

The recommendations for *N. Gonorrhoea* treatment is a single dose of intramuscular ceftriaxone. Previously, it used to be recommended that if a patient tested positive for gonorrhea to treat for Chlamydia trachomatis as well; however, this has changed in recent years due to emergence of resistance. After treatment of urogenital or rectal infection, *N. Gonorrhoea* clearance testing is not recommended. Though, it is recommended to test 7-14 days after treatment for a pharyngeal infection. [4]

## Conclusions

With these guidelines in mind, this patient was treated as detailed in the following. For the patient's neurosyphilis/otosyphilis, he was given IV penicillin G for 14 days and received RPR titers six months later that showed greater than a four-fold decrease indicating sufficient treatment (from 1:128 to 1:4). For the patient's LGV, he was given a fourteen-day course of doxycycline and re-tested at five months post treatment which was negative. For the patient's rectal gonorrhea, the patient was given a single dose of intramuscular ceftriaxone.

This case demonstrates that it is incredibly important swab for STI's at all possible contact locations regardless of condom use including genital, anal, and pharyngeal sites. Furthermore, this case demonstrates the important of appropriate treatment selection and follow-up testing after treatment.

## References

1. STI screening recommendations. Centers for Disease Control and Prevention. <https://www.cdc.gov/std/treatment-guidelines/screening-recommendations.htm>. Published June 6, 2022. Accessed September 2, 2022.
2. Chlamydial infections - STI treatment guidelines. Centers for Disease Control and Prevention. <https://www.cdc.gov/std/treatment-guidelines/chlamydia.htm>. Published July 22, 2021. Accessed September 2, 2022.
3. Lymphogranuloma Venereum (LGV) - STI treatment guidelines. Centers for Disease Control and Prevention. <https://www.cdc.gov/std/treatment-guidelines/lgv.htm>. Published July 22, 2021. Accessed September 2, 2022.
4. Gonococcal infections among adolescents and adults - STI treatment guidelines. Centers for Disease Control and Prevention. <https://www.cdc.gov/std/treatment-guidelines/gonorrhea-adults.htm>. Published September 21, 2022. Accessed September 2, 2022.
5. Syphilis - STI treatment guidelines. Centers for Disease Control and Prevention. <https://www.cdc.gov/std/treatment-guidelines/syphilis.htm>. Published March 30, 2022. Accessed September 2, 2022.
6. STI testing self-collection kit. <https://www.stanfordchildrens.org/content-public/pdf/sti-testing-self-collection-kit-instructions.pdf>. Published 2019. Accessed October 2, 2022.