

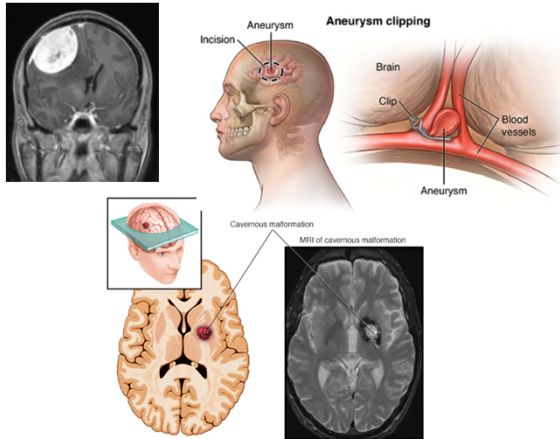


Management of Anticoagulation Therapy After Craniotomy

Kierany B. Shelvin, MS, John M. Wilson MD, Sarah E. Lawhon MD MPH, George A. Crabill MD, Ellery Hayden, Olivia Gilbert, James Alan Velander MD
Louisiana State University Health Sciences Center, Department of Neurosurgery, New Orleans, LA, USA

Introduction

- In the in-patient setting, physicians routinely administer anticoagulation (AC) therapy to treat venous thromboembolism (VTE). However, AC therapy is often held in neurosurgical patients undergoing craniotomies due to the risk of intracranial hemorrhage (ICH) associated with this operation.
- A craniotomy is a procedure involving the removal of the skull.
 - Examples:
 - Meningioma resection
 - Aneurysm clipping
 - Cavernous malformation resection



- In addition to ICH, these patients are at an increased risk for post-operative VTE. It is estimated that 50% of patients experience VTE post-craniotomy.
 - Both ICH and VTE are serious complications that can lead to significant morbidity or death.
- Currently, there is no standard protocol for VTE therapy following craniotomy. This continues to challenge neurosurgeons when determining the most appropriate management of anticoagulation therapy after craniotomy to simultaneously mitigate the risks of ICH and VTE.

Aim: In this study, we reviewed the time frame of AC therapy administration as well as the incidence of ICH and other complications following AC therapy in patients after craniotomy.

Methods

We performed a retrospective chart review of all craniotomy patients from August 2017 and July 2021. Patients were selected if they received anticoagulation therapy following a VTE. Additionally, demographics and clinical data were collected including age, gender, reason for operation, day and time of AC administration, and type of AC received.

Results

- Forty patients met the inclusion criteria. 50% male and 50% female. Average age 49.35.
 - The most common indication for starting anticoagulation was a deep venous thromboembolism and pulmonary embolism.
 - The initial type of anticoagulation used in 27 patients was unfractionated heparin (67.5%), followed by a novel oral anticoagulant 8 (20%), low molecular weight heparin 4 (10%) and warfarin at (2.5%).
 - The range of initiation of anticoagulation therapy after surgery was from post-op day 2 to post-op day 107. The average time of AC therapy administration was post-op day 10.
 - Five of the forty patients (12.5%) experienced complications following anticoagulation therapy with three of the five experiencing an intracranial hemorrhage. None of the patients who experienced complications required revisional surgery.
 - Three of the five patients developed a new intracranial hemorrhage.
 - One of the five patients developed Heparin-Induced Thrombocytopenia (HIT) and responded to Argatroban therapy.
 - One of the five patients developed a tracheostomy hemorrhage.
 - Once the patients with complications were stable, their anticoagulation therapy was restarted.

Conclusions

We conclude that our results display evidence for a benefit to anticoagulation therapy after craniotomy. Moreover, our results appear to exhibit the potential for safe administration of AC therapy earlier after craniotomy than previously observed.

Discussion

- VTE is the most common preventable post-operative complication leading to mortality.
- The need for a standard protocol for the therapeutic administration of anticoagulation has become more imperative
- Routinely, it has become common for neurosurgical patients to be given LMWH or UFH as VTE therapy.
- Our study resulted with favorable insight to the safe therapeutic administration of anticoagulation following craniotomy; however, the best time frame to initiate the anticoagulation remains unclear.

Limitations

- As a retrospective chart review, our study lacked a comparison group which would need to be included in future studies to further confirm the validity of our study.
- Our sample size was small due to the low incidence of therapeutic anticoagulation use following the total number of craniotomies within our institution.
- In the future, it may be beneficial to collaborate with other institutions to execute a prospective study to increase the sample size, include comparison groups, and control for bias and confounding variables.
- Additionally, we found that there was no standard to the choice of AC therapy. It was given based on the surgeon's preference.
 - A prospective study of specific AC therapy given after craniotomy would aid in the development for a more standard protocol of AC therapy administration after neurosurgery.

References

- Brain Aneurysm Clipping | Famous Neurosurgeon in Bangalore. Published July 4, 2021. Accessed October 2, 2022. <https://neurowellness.in/brain-aneurysm-clipping/>
- Cavernous malformations - Symptoms and causes. Mayo Clinic. Accessed October 2, 2022. <https://www.mayoclinic.org/diseases-conditions/cavernous-malformations/symptoms-causes/syc-20360941>
- Meningioma | Information, Treatment & Surgery Melbourne. Dr David Oehme Melbourne Neurosurgeon. Accessed October 2, 2022. <https://www.doneurosurgery.com/meningioma.html>
- CDC. Learn About Healthcare-Associated Venous Thromboembolism | CDC. Centers for Disease Control and Prevention. Published October 22, 2018. Accessed October 2, 2022. <https://www.cdc.gov/ncbddd/dvt/ha-vte.html>
- de Melo Junior JO, Lodi Campos Melo MA, da Silva Lavradas LA, et al. Therapeutic anticoagulation for venous thromboembolism after recent brain surgery: Evaluating the risk of intracranial hemorrhage. *Clin Neurol Neurosurg.* 2020;197:106202. doi:10.1016/j.clineuro.2020.106202
- Rinaldo L, Brown D, Bhargava A, et al. Venous thromboembolic events in patients undergoing craniotomy for tumor resection: Incidence, predictors, and review of literature. *Journal of neurosurgery.* 2019;132:1-12. doi:10.3171/2018.7.JNS181175