

# THE MEASUREMENT AND ANALYSIS OF AXIAL DEFORMITY AT THE KNEE

**Kenneth A. Krackow, M.D.**

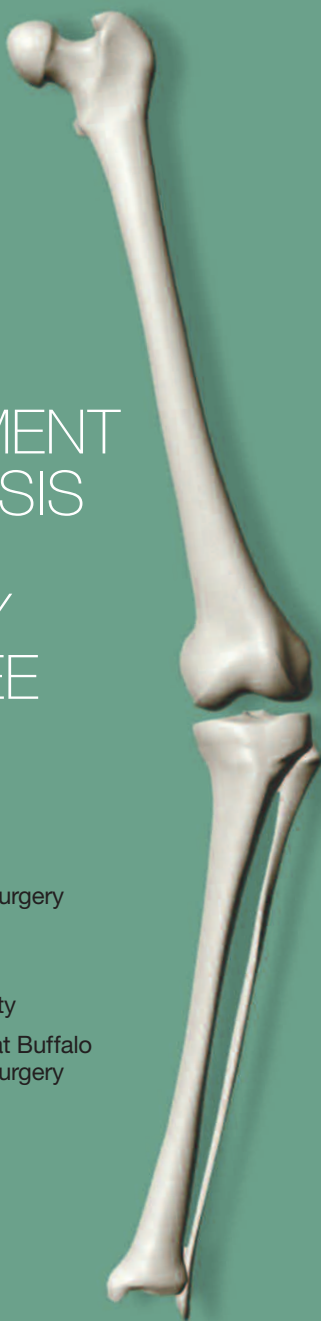Clinical Director,  
Department of Orthopaedic Surgery

Kaleida Health System  
Buffalo General Hospital

Professor and Full Time Faculty

State University of New York at Buffalo  
Department of Orthopaedic Surgery

**Homer  
Stryker**  
Center



# THE MEASUREMENT AND ANALYSIS OF AXIAL DEFORMITY AT THE KNEE

**Kenneth A. Krackow, M.D.**

Clinical Director,  
Department of Orthopaedic Surgery

Kaleida Health System  
Buffalo General Hospital

Professor and Full Time Faculty

State University of New York at Buffalo  
Department of Orthopaedic Surgery

# TABLE OF CONTENTS

<b>PREFACE</b>	i
<b>UNIT 1</b>	
Lower Extremity Alignment Terminology	1
<b>UNIT 2</b>	
Measurement of Overall Varus/Valgus Deformity at the Knee	7
<b>UNIT 3</b>	
Medial Lateral Tibiofemoral Translation – Subluxation	15
<b>UNIT 4</b>	
Extra-articular Deformity	17
<b>UNIT 5</b>	
Characterizing Deformity About the Knee	23
<b>UNIT 6</b>	
Instructional Examples	30
<b>EXAMPLE 1</b>	
Varus Deformity of the Femur and Tibia	31
<b>EXAMPLE 2</b>	
Varus Deformity of the Tibia	41
<b>EXAMPLE 3</b>	
Varus Deformity at the Femur with Minor “Compensation” at the Tibia	49
<b>EXAMPLE 4</b>	
Valgus Deformity at Both the Femur and Tibia	55
<b>EXAMPLE 5</b>	
Valgus Deformity at the Femur and Tibia	61
<b>EXAMPLE 6</b>	
Valgus Deformity at the Femur and Tibia	67
<b>EXAMPLE 7</b>	
Extra-articular Varus Angulation of the Tibia	73
<b>EXAMPLE 8</b>	
Valgus Deformity at the Femur and Extra-articular Varus Tibial Angulation	81
<b>EXAMPLE 9</b>	
Extra-articular Varus Angulation of the Femur	89
<b>EXAMPLE 10</b>	
Valgus Deformity of the Femur with Extra-articular Valgus Tibial Angulation	97
<b>UNIT 7</b>	
Online Interactive Practice	105
<b>REFERENCES</b>	106



**Kenneth A. Krackow, M.D.**

Dr. Krackow is a graduate of the Duke University Medical School in Durham, North Carolina. After a General Surgery Internship, he completed his Orthopaedic Residency at Johns Hopkins University in Baltimore, Maryland.

Currently, Dr. Krackow is Professor of Orthopaedic Surgery at the State University of New York at Buffalo. He is also Clinical Director of Orthopaedic Surgery, Kaleida Health, Buffalo, New York. He practices at both Kaleida Health and Buffalo General Hospital.

## PREFACE

This booklet is intended to be used principally by orthopaedic residents and fellows as an instructional tool. By combining instruction, illustrated examples, and problems, it provides a comprehensive overview of knee alignment—a difficult topic to teach and explain successfully. The content of this booklet appears to be quite clear; however, it is in practical application where the challenges arise. Repetition and practice are the keys not only to learning how to assess an X-ray and to perform a proper alignment analysis but, more importantly, they are critical to retaining these skills. This booklet provides the reader with the ability to practice application of knee alignment principles within the textbook itself as well as within an interactive format provided by an online computer simulation module. We hope this booklet will provide the reader with the information and experience-based opportunity to help achieve a level of mastery on this subject that will continue throughout his or her entire career.

## ABOUT THE HOMER STRYKER CENTER

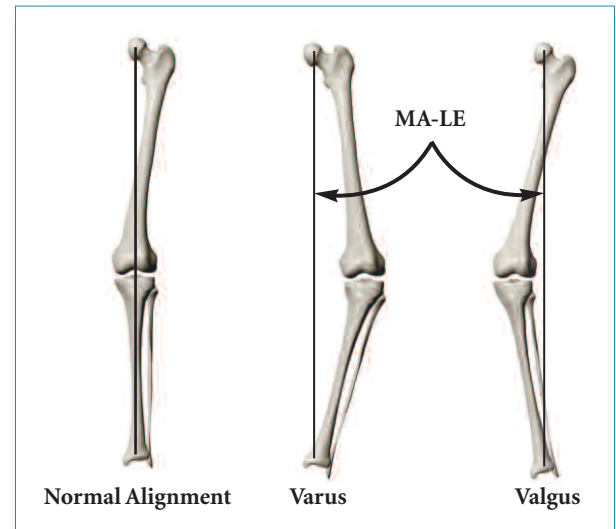
The Homer Stryker Center is dedicated to improving patient outcomes through education and research. The Center offers courses in orthopaedic bioskills and surgical simulation as well as didactic education and discussion groups. Our intention is to work with an internationally recognized faculty to develop exceptional educational material using modern education technologies.

# UNIT 1

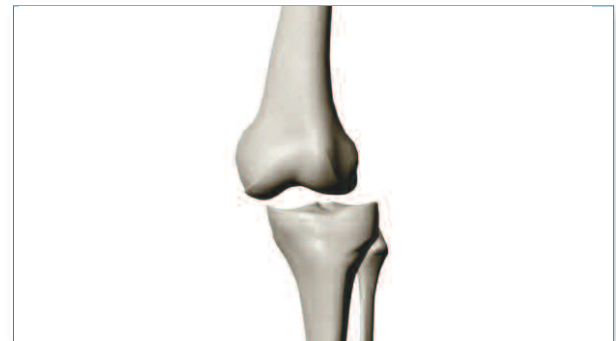## Lower Extremity Alignment Terminology

A standard method for determining **normal alignment** of the knee is by drawing a line in the A/P plane that begins at the center of the femoral head, passes through the center of the knee, and continues to the center of the ankle (**Figure 1.1**). This line is often referred to as the **mechanical axis of the lower extremity (MA-LE)**. If the line passes medially to the knee center, a **varus deformity** is present; if the line passes laterally to the knee center or center of the distal femur, a **valgus deformity** exists.

Distinctions can be made between the knee center and center of the distal femur. In cases of medial or lateral subluxation of the knee, for example, they may represent 2 different points. They may also be different from the center of the proximal tibia. **Figure 1.2** shows a lateral tibial subluxation, where the center of the distal femur and the center of the knee at different points.



**Figure 1.1**  
Normal mechanical alignment and mechanical axis of the lower extremity in common deformities.



**Figure 1.2**  
Lateral tibial subluxation.

Several other lines (or axes) are used to describe lower extremity alignment; all are drawn in the A/P plane. These are not “axes” in a true sense, although the nomenclature has found its way into general orthopaedic terminology. These axes include:

**1. Mechanical axis of the femur (MAF):**

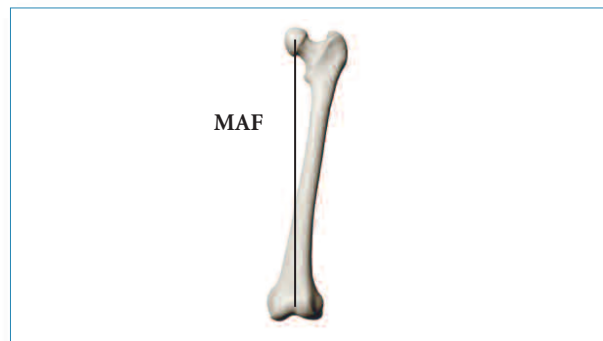A line from the center of the femoral head to the center of the distal femur or center of the knee (**Figure 1.3**).

**2. Femoral shaft axis (FShA):**

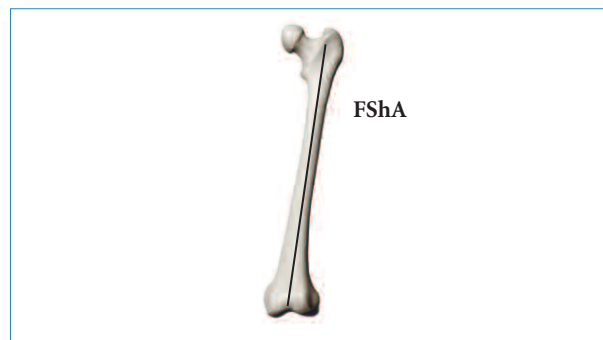A line drawn from the center of the proximal femur to the center of the distal femur or center of the knee, indicating the overall position of the femoral shaft (**Figure 1.4**).

**3. Tibial shaft axis (TShA) and Mechanical axis of the tibia (MAT):**

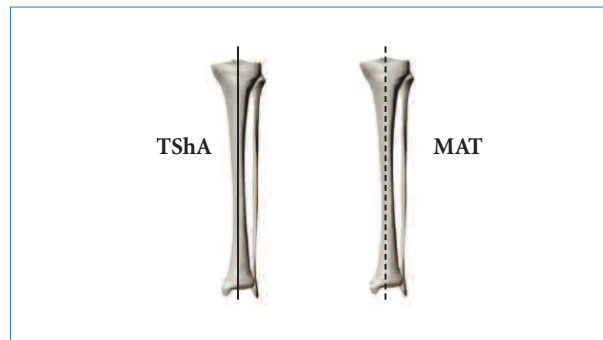
These 2 terms are often used interchangeably, and both describe a line extending from the center of the proximal tibia to the center of the ankle (**Figure 1.5**).



**Figure 1.3**



**Figure 1.4**



**Figure 1.5**

#### 4. Anatomic tibiofemoral angle:

The angle formed when the line that forms the femoral shaft axis is extended through the distal femur to form an angle between the femoral shaft axis and the tibial shaft axis (**Figure 1.6**). The angle is represented by numbers that supplement the normal angle of alignment (e.g., 3°, 6°, etc.) and indicates the extent of anatomic misalignment or deformity.

#### 5. Mechanical tibiofemoral angle (or mechanical axis deviation):

The angle formed when the line that forms the mechanical axis of the femur is extended through the distal femur to form an angle between the mechanical axis of the femur and the tibial shaft axis (**Figure 1.7**). As with the anatomic tibiofemoral angle, this angle is represented by numbers that supplement the normal angle of alignment (e.g., 3°, 6°, etc.) and indicates the extent of mechanical misalignment or deformity.

#### Comments

The descriptions that follow are based on some assumptions that may not be completely precise in an actual clinical setting including 1) that the knee is seen in full extension, and 2) that the knee extremity is seen in neutral rotation.

Additionally, our measurements are represented as being made on a long standing radiograph, showing essentially all of each tibia and femur. The femoral head and ankle would ideally be shown, which may not be the case; alternative management will be indicated.

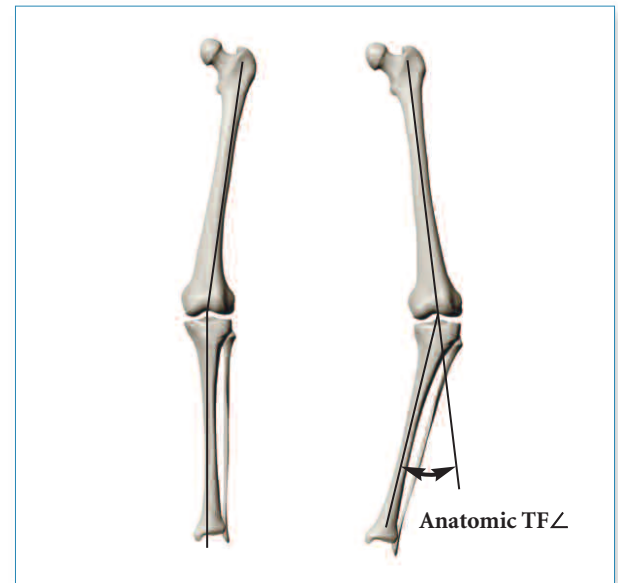

Figure 1.6

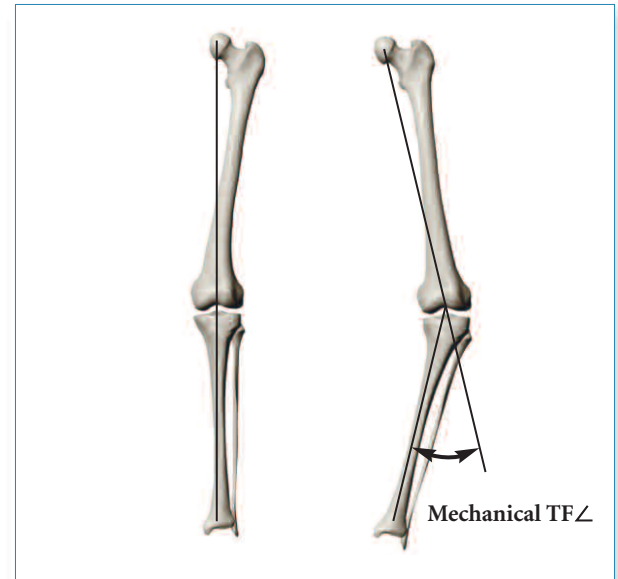

Figure 1.7

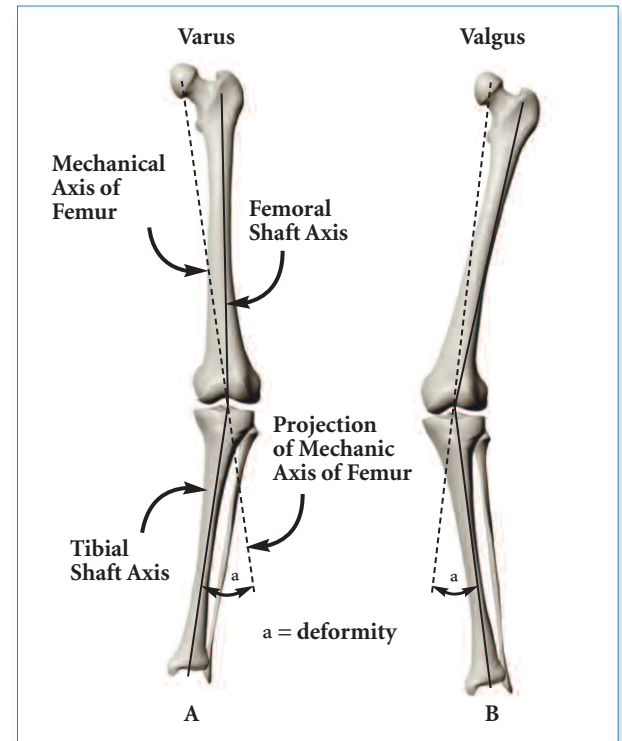
## UNIT 2

### Measurement of Overall Varus/Valgus Deformity at the Knee

#### 2.1 Measurement when the long standing films indicate the center of the femoral head and the center of the ankle

Our definition of normal alignment is when a line drawn from the center of the hip to the center of the knee continues toward and transverses the center of the ankle. The question we want to answer is, "When this is not the case, how much deformity exists?". To answer, we draw a straight line from the center of the femoral head to the center of the knee (the mechanical axis of the femur) and project that line beyond the knee downward, ideally until the level of the ankle. The angle formed by the portion of the line projected beyond the knee and the tibial shaft axis represents the degree of deformity (a).

The angle formed by the portion of the line projected beyond the knee and the tibial shaft axis represents the degree of deformity (a). **Figure 2.1** shows how this deformity is measured; 2.1(A) represents a varus deformity, and 2.1(B), a valgus deformity.



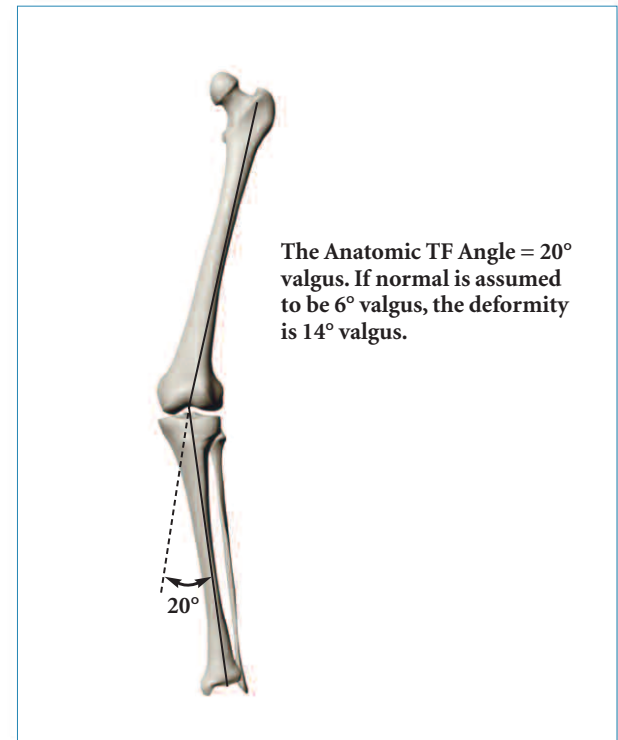
**Figure 2.1**  
Measurement of lower extremity deformity.



Note that deformity has been described and quantified without using the mechanical axis of the lower extremity (the line from the femoral head to the ankle). We have observed that a majority of orthopaedic residents find the presence of this line confusing, and it provides no useful information for planning purposes.

## 2.2 Measurement when the femoral head is not visible on long standing lower extremity radiographs

Our measurements thus far have been based on the center of the femoral head; we have not used the “normal tibiofemoral angle,” which includes the femoral shaft. Certain characteristics, however, may impede visibility of the femoral head, including height, obesity, and radiograph quality. In these cases, the tibiofemoral angle that is present is measured and compared to an assumed value (such as  $6^\circ$  valgus), and the difference is taken as the amount of deformity. This concept is illustrated in **Figure 2.2**. The measured tibiofemoral angle is  $20^\circ$  valgus and, when compared to the assumed  $6^\circ$  valgus, leaves the estimated deformity at  $14^\circ$  valgus.

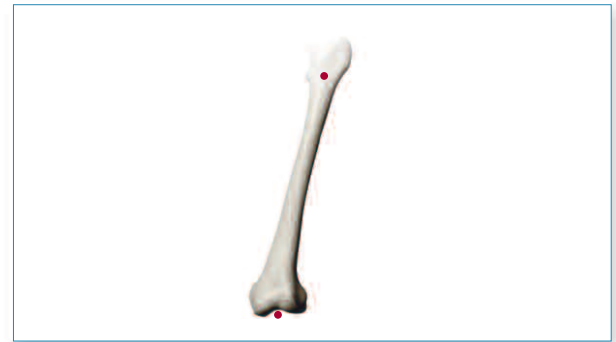

**Figure 2.2**  
Measurement of lower extremity deformity when femoral head is not visible - using the anatomic tibio-femoral angle.

Why did we select 6° of valgus as the ‘normal’ or ‘average’ tibiofemoral angle? There is little disagreement that the value should be between 5 and 7° of valgus. The works of others (Krackow<sup>1</sup>, Moreland et. al<sup>2</sup>, Yoshioka et. al<sup>3</sup>, Chao et. al<sup>4</sup>) suggest approximately 5.5 to 6°; therefore, for accuracy and simplicity, 6° is recommended. There are certain instances with arthroplasty patients in which normal valgus may be different, such as 2 to 4°. Examples are the presence of a total hip replacement, hip dysplasia with femoral anteversion, etc.

The distal and proximal points for the femoral shaft axis are characterized somewhat differently. The distal point can be clear if no uncertainty exists regarding the center of the knee. One suggestion is to use the midpoint at the superior aspect of the intercondylar sulcus. This point can also be thought of as the functional center of the distal femur and relates directly to patellar tracking, as it is midway between the medial and lateral condyles.

The proximal point is not as clearly defined. One suggestion is to use the midpoint of the proximal aspect of the femur, in the region of the lesser trochanter **(Figure 2.3)**. Draw a transverse line just above or below the lesser trochanter; its endosteal midpoint represents the desired point. This makes it relatively easy to approximate the overall course of the femoral shaft. In the case of femoral bowing, place a mark at the proximal femur and use the line defined by connecting the proximal and distal marks.

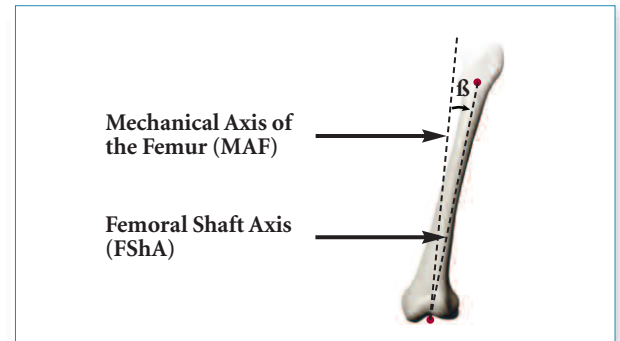


**Figure 2.3**  
**Drawing femoral shaft axis when the femoral head is not visible.**

## Important Consideration

When discussing normal knee alignment, it is necessary to take into account that an individual's normal tibiofemoral angle is determined solely by the femur, and equals the angle between the mechanical axis of the femur (MAF) and femoral shaft axis (FShA) (Figure 2.4). This angle is also the individual's anatomic tibiofemoral angle. The ability to see the tibia is not necessary to obtain this angle; therefore, a neutrally rotated A/P view of the entire femur can be used to determine a patient's ideal tibiofemoral angle.

A second important consideration is that of an indistinct ankle joint. An unpublished study of long standing lower extremity radiographs (LSLE) showed that a line drawn from the center of the proximal tibia to the center of the ankle crosses the tibial metaphysis approximately 50% of the way (medial-lateral) to the midpoint. Therefore, marking the distal tibia to indicate the tibial shaft axis at the midpoint across the visible end of the tibia seems appropriate.



**Figure 2.4**

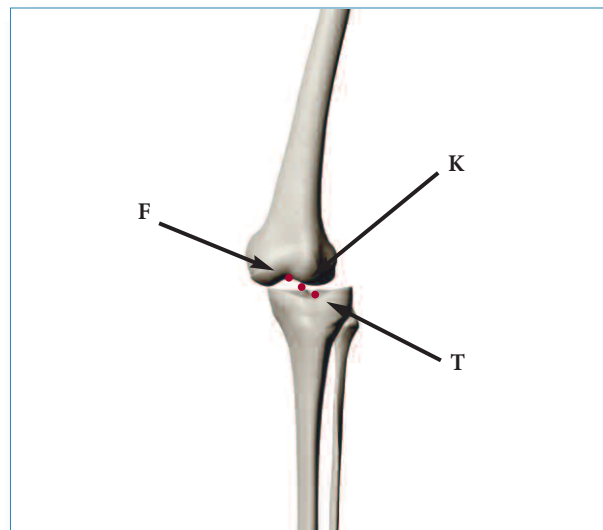
**Location of the mechanical axis of the femur and the femoral shaft axis. The angle between these two lines is the *ideal* anatomic tibial femoral angle in this case.**

## UNIT 3

### Medial Lateral Tibiofemoral Translation – Subluxation

Additional elements to knee pathology and deformity are clearly present when viewing a radiograph with medial-lateral tibiofemoral subluxation. Clinical implications are dependent on how this translation is quantified. In general, we are asking how this translation affects various measurement conventions. Specifically, we want to know if the various lines drawn that reference the center of the knee are going to give similar, mildly different, or significantly different determinations with respect to tibiofemoral angle measurements and deformity assessments.

This question is addressed in **Figure 3.1**. The choices implied are to draw the femoral and tibial axes connected to the middle point (K), the center or 'midpoint' of the knee), or to the distal femoral (F) or proximal tibial (T) point.



**Figure 3.1**  
Location of the center of the knee.

## UNIT 4

### Extra-articular Deformity

It is sometimes necessary to analyze X-rays with significant extra-articular deformity secondary to fracture or developmental considerations (**Figure 4.1**). The previous analyses largely ignored the intermediate shape of the respective tibial and femoral shafts.

These cases can be analyzed using modern computer programs, tracing paper, or basic trigonometry/geometry, which is explained below.

*Extra-articular approximation theorem:*

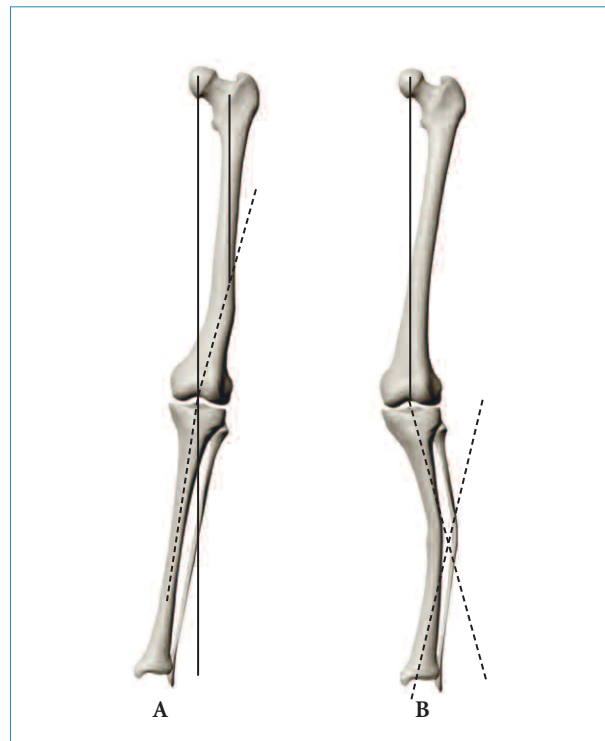
A tibial or femoral shaft extra-articular deformity of a certain angular amount creates a corresponding deformity at the knee in approximate proportion to the percentage of the way that deformity is located toward the knee.

#### **Example 1 (Figure 4.1-A):**

A  $10^\circ$  varus deformity 80% of the way from the hip to the knee, or 20% of the way above the knee, would impart an approximately  $8^\circ$  varus deformity at the knee, which would be 100% on the femoral side.

#### **Example 2 (Figure 4.1-B):**

A  $10^\circ$  varus deformity 80% of the way from the ankle to the knee, or 20% of the way below the knee, would impart an approximately  $8^\circ$  varus deformity at the knee, which would be 100% on the tibial side.



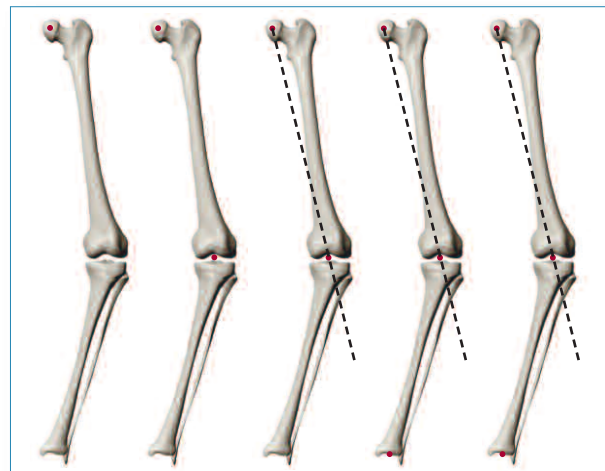
**Figure 4.1**  
Measurement of extra-articular deformity.

The approximation relates to the angle and length differences noted when drawing lines from the apex of an isosceles triangle to its base. Drawing a line from the vertex to the midpoint of the base creates a bisection of both the base and the vertex angle. Drawing lines to the points which define a trisection of the base length does not. However, it does provide 3 equal angles at the vertex of the triangle.

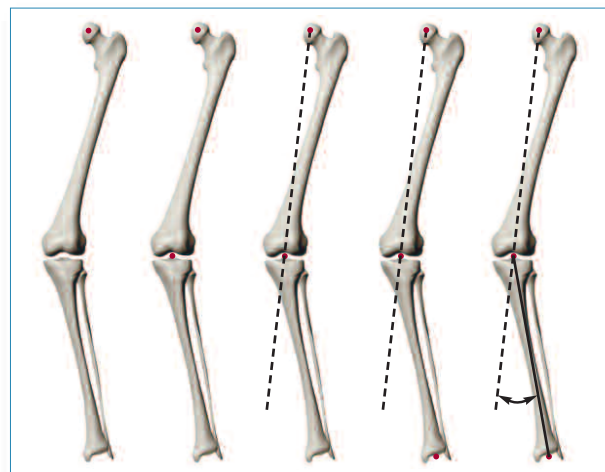
### Summary: Measurement of Varus/Valgus Deformity

If the femoral head is visible (**Figure 4.2**):

1. Locate the center of the knee and center of the femoral head.
2. Draw a line connecting these two points.
3. Locate (or approximate) the center of the ankle.
4. Draw a line connecting the center of the knee to the center of the ankle.
5. Measure the angle between the 2 lines. A measurement of  $0^{\circ}/180^{\circ}$  implies no deformity; otherwise, the observed angle is the angle of varus or valgus present (valgus if foot is lateral, varus if foot is medial).



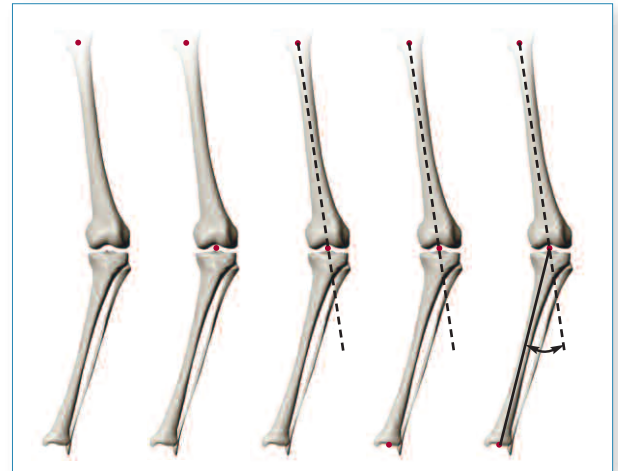
**Figure 4.2 (Varus)**  
An uncomplicated varus deformity.



**Figure 4.2 (Valgus)**  
An uncomplicated valgus deformity.

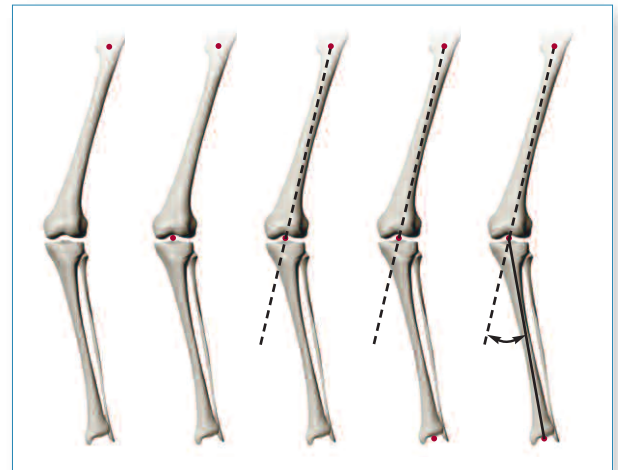
If the femoral head is not visible (**Figure 4.3**):

1. Locate the midpoint of the proximal femur in the region of the lesser trochanter.
2. Locate the center of the knee.
3. Draw a line from the proximal femur to the center of the knee.
4. Locate (or approximate) the center of the ankle.
5. Draw a line from the center of the knee to the center of the ankle.
6. Measure the angle between the 2 lines and label as varus or valgus, depending on position of tibia (pointed inward or laterally).
7. Compare the measured angle to a normal value (i.e., 6° valgus).



**Figure 4.3 (Varus)**

**Varus deformity with the femoral head not visible.**



**Figure 4.3 (Valgus)**

**Valgus deformity with the femoral head not visible.**

## UNIT 5

### Characterizing Deformity About the Knee

Determination of a varus/valgus deformity only tells us that the deformity exists; details such as its location are not revealed. Additional analyses, utilizing joint-line orientation, allow prediction of outcomes of particular osteotomy methods and anticipation of certain TKA problems. Previous discussion has only considered knee position as a center-point (i.e., centered on the mechanical axis). Deformity can be characterized according to 4 'origins':

#### 1. Deformity on the Femoral Side of the Joint

Due either to developmental abnormality or to attrition of bone very close to the joint as a result of fracture, degenerative wear, avascular necrosis, collapse, etc.

#### 2. Deformity on the Tibial Side of the Joint

Due either to developmental abnormality, degeneration, etc.

#### 3. Deformity Within the Joint Itself

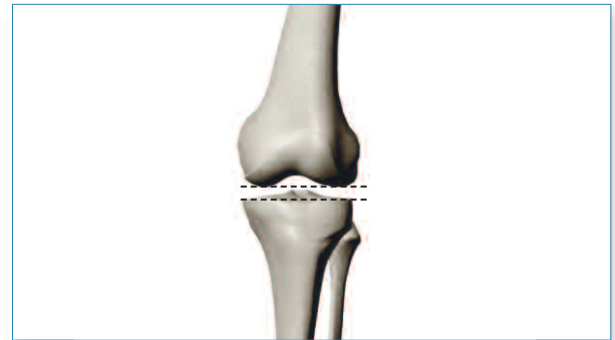
Due to asymmetric wear.

#### 4. Deformity Due to Discreet Extra-articular Angulation

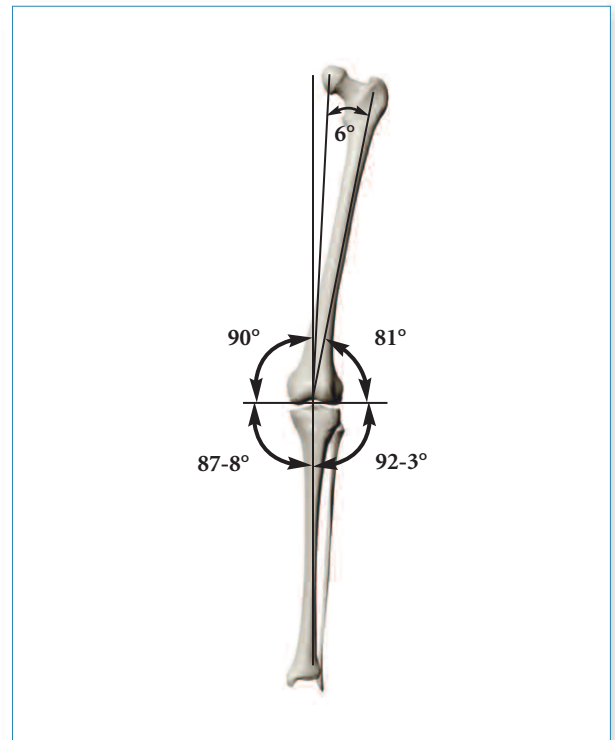
Generally exemplified by new angulation after fracture or osteotomy.

Considering these origins of deformity requires establishing standards for normal (average) values indicating joint line orientation, with any variation alluding to the deformities just described. In **Figure 5.1**, the normal articular cartilage space (medial vs. lateral) is approximately equal – lines across the distal femoral condyles and across the medial and lateral tibial plateaus are essentially parallel.

In **Figure 5.2**, the overall joint line is typically slightly different from perpendicular (2 to 3°, on average).



**Figure 5.1**  
Joint lines added.

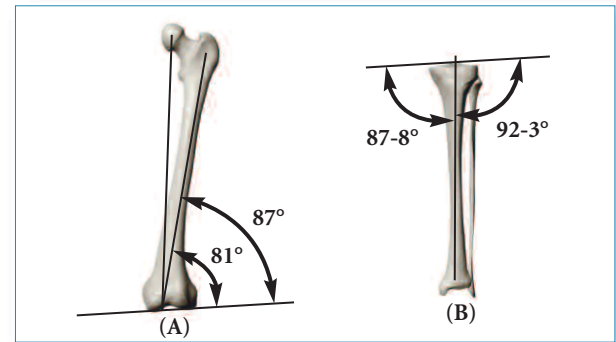


**Figure 5.2**  
Representative angles for a non-deformed knee.



The normal femoral joint angle (FJA) is 2 to 3° valgus to the mechanical axis of the femur, or 8 to 9° valgus to the normal femoral shaft axis (**Figure 5.3-A**). The normal tibial joint angle (TJA) is 2 to 3° varus to the mechanical axis of the tibia (equivalent to the tibial shaft axis) (**Figure 5.3-B**). Smaller numbers are typically used when describing these terms (e.g., a 3° varus TJA vs. a medial TJA of 87°).

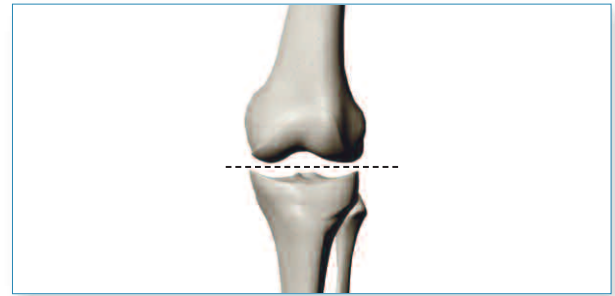
Here the joint line is being measured relative to the tibial shaft axis and the mechanical axis of the femur. Recall that the mechanical axis of the femur is a conceptual line that does not exist on a radiograph (it must be drawn), as opposed to the femoral shaft axis. Comparison of the joint line to the femoral shaft is often the simplest measure. Comparison with the mechanical axis of the femur requires a visible femoral head center on the radiograph. When not visible, the previous assumption that the angle between the mechanical axis of the femur and the femoral shaft axis is 6° must be used. Thus, the joint line is actually compared to the femoral shaft axis, and the 6° assumption is added. This value is subsequently added to the normal 2 to 3° angulation present between the mechanical axis and an otherwise perpendicular joint.



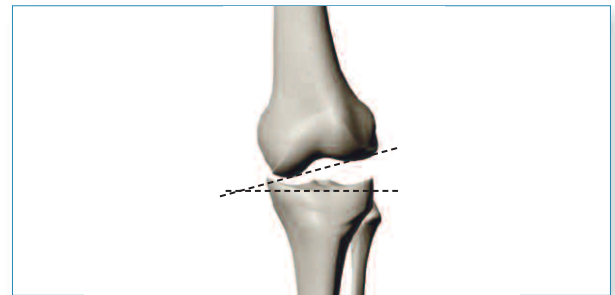
**Figure 5.3**  
Femoral (A) and tibial (B) joint angles.

**Asymmetry within the joint line can be drawn different ways:**

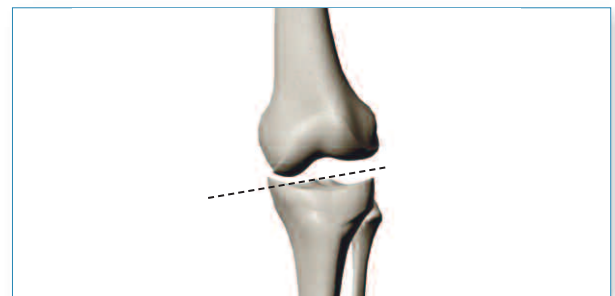
1. A single line, with no distinction for any joint line asymmetry (**Figure 5.4**).
2. Two lines, showing the intra-articular asymmetry (bony distal femoral joint line and proximal tibial joint line, (**Figure 5.5**).
3. A single line that bisects the bony joint lines shows joint line asymmetry (**Figure 5.6**).



**Figure 5.4**  
One line to indicate the joint line.



**Figure 5.5**  
Two lines, the bony distal femoral joint line and proximal tibial joint line, forming an intra-articular angle due to joint wear and/or ligament instability.



**Figure 5.6**  
The same physical situation as in Figure 5.5 only with a single joint line to represent the mean overall position of the joint line. This method is used in our examples and problems.

When dealing with cases of varus/valgus deformity with extra-articular elements, the analysis can be relatively straightforward by answering a sequence of questions:

### **1. How much varus/valgus deformity exists?**

**Answer:**

*Construct the mechanical axis of the femur and tibial shaft axis; measure and label the angle between them.*

### **2. How much of the deformity is:**

**a. In the distal femur (as it currently lies)?**

**b. In the proximal tibia (as it currently lies)?**

**c. Within the joint space (if asymmetric, and a separate evaluation is desired)?**

**Answers:**

*a. Draw the femoral joint angle (FJA) and compare to standard (2 to 3° valgus).*

*b. Draw the tibial joint angle (TJA) and compare to standard (2 to 3° varus).*

*c. Draw the intra-articular angle (IAA) and compare to standard (0°).*

### **3. How much of the tibial or femoral deformity is due to shaft angulation?**

**Answers:**

*a. Measure angulation in the shaft.*

*b. Determine its proportional distance away from the hip or ankle.*

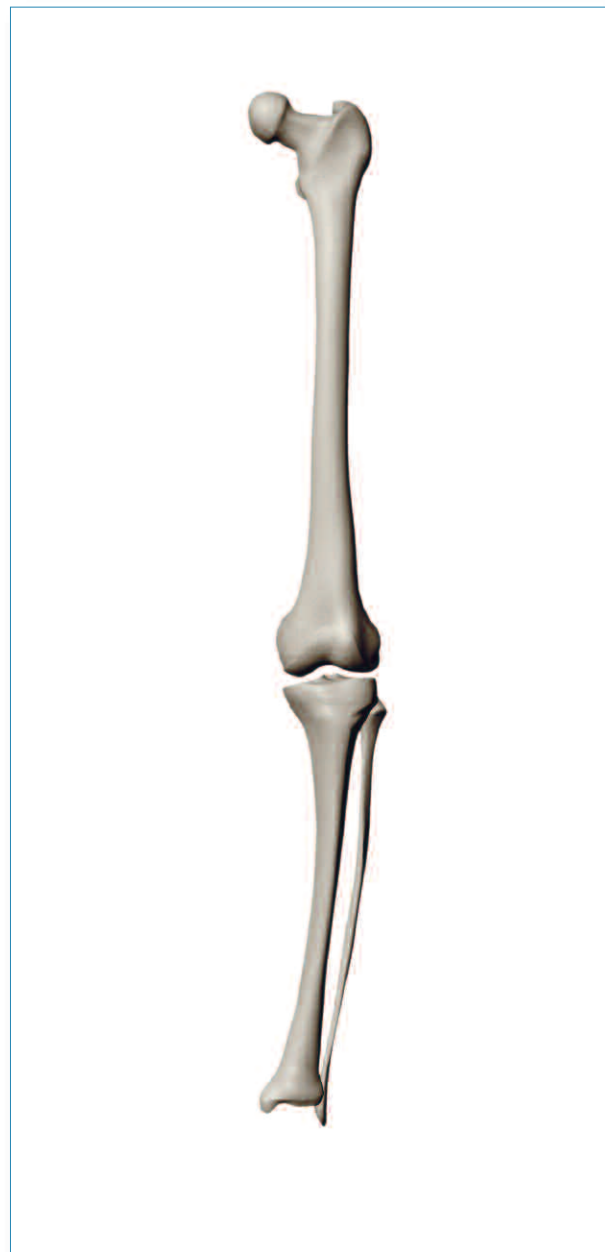*c. Multiply the proportion with the shaft angulation and compare to the deformity angles obtained during FJA, TJA, and IAA comparisons (Question 2, above).*

## UNIT 6 INSTRUCTIONAL EXAMPLES

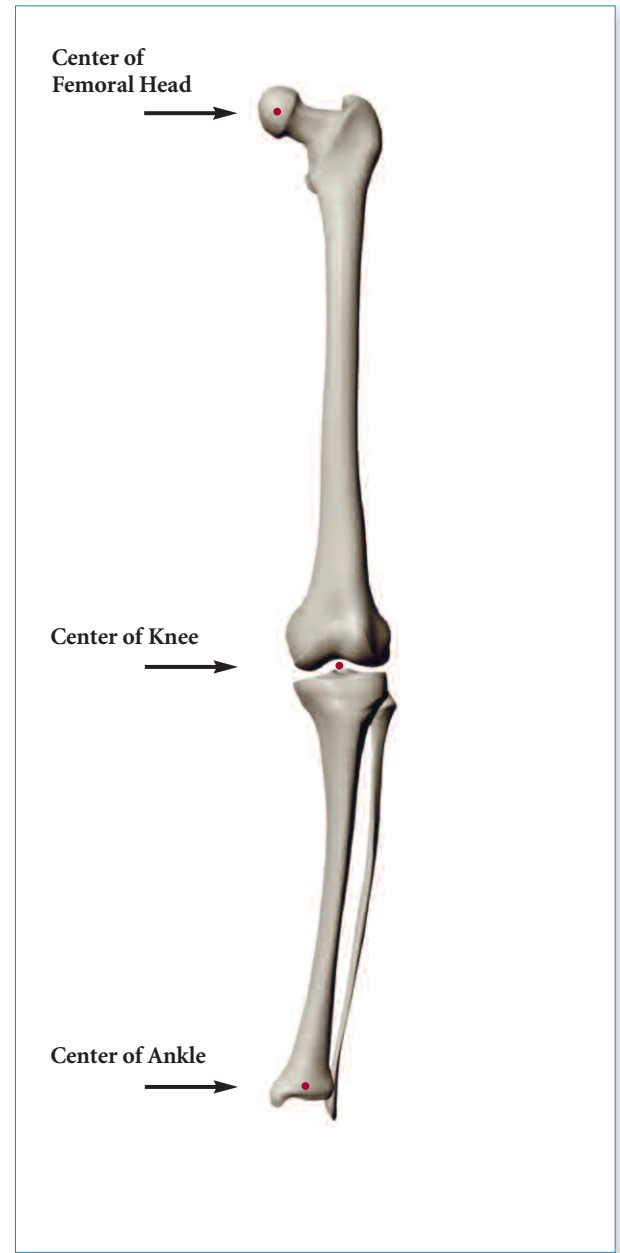
**The alignment analyses are shown step-by-step in the following 10 examples.**

## EXAMPLE 1

### Varus Deformity of the Femur and Tibia

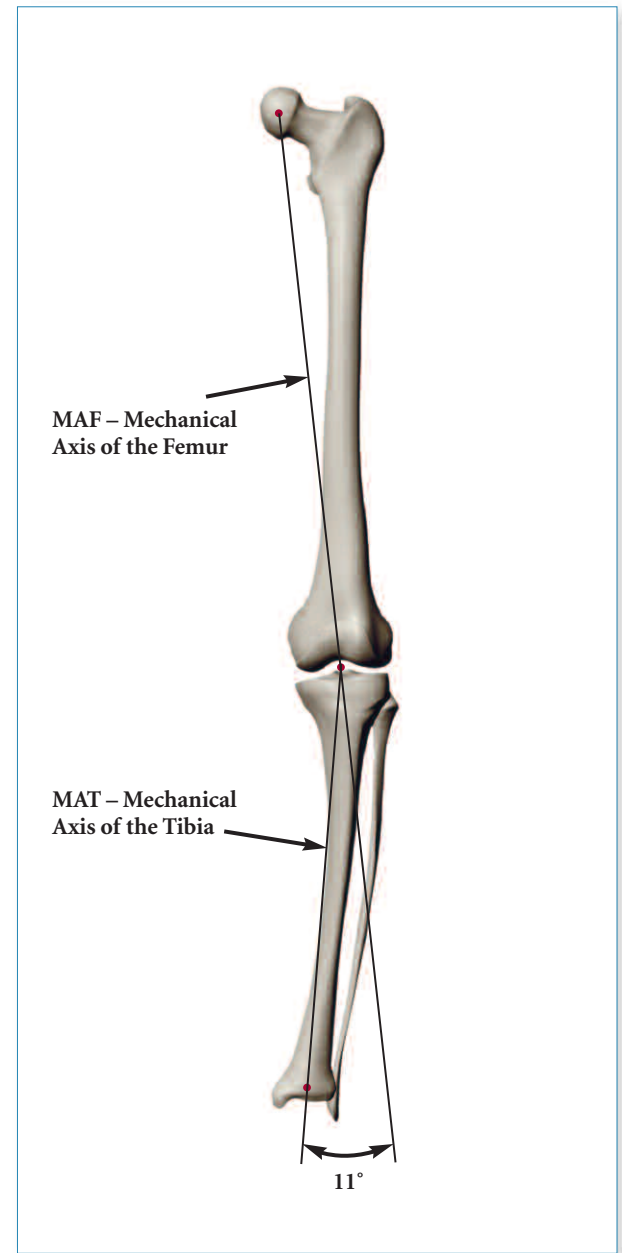


- ▶ Identify the center of the femoral head, knee, and ankle.



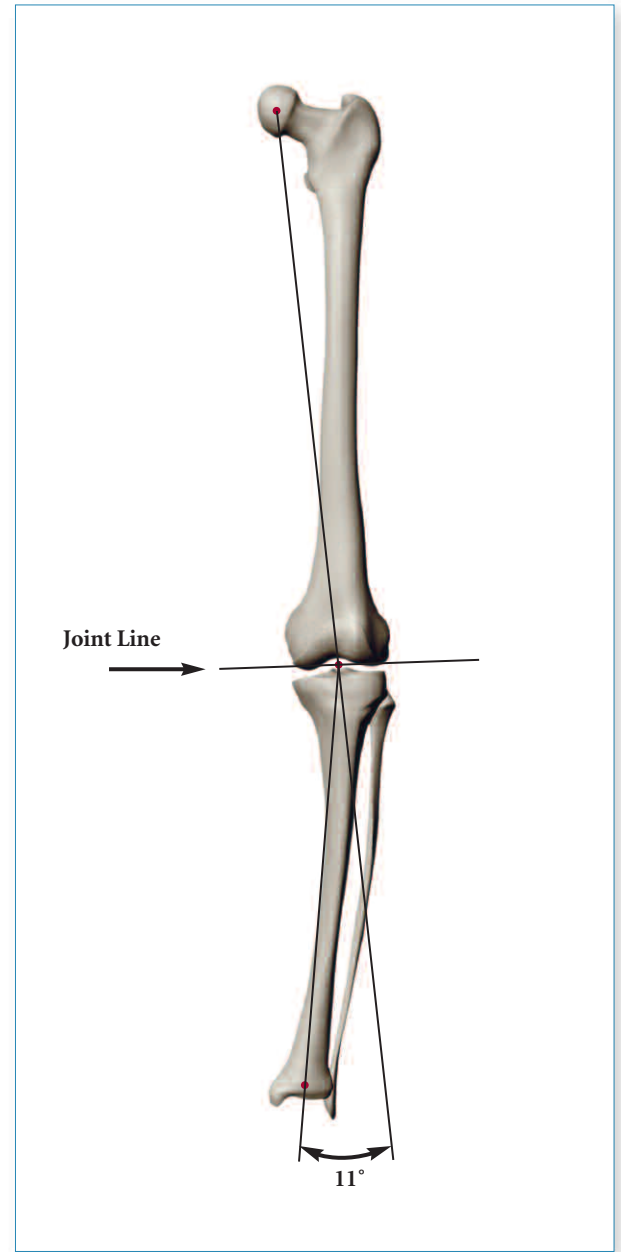
**Example 1A**

- ▶ The axes are marked, and an overall varus deformity of  $11^\circ$  is measured.



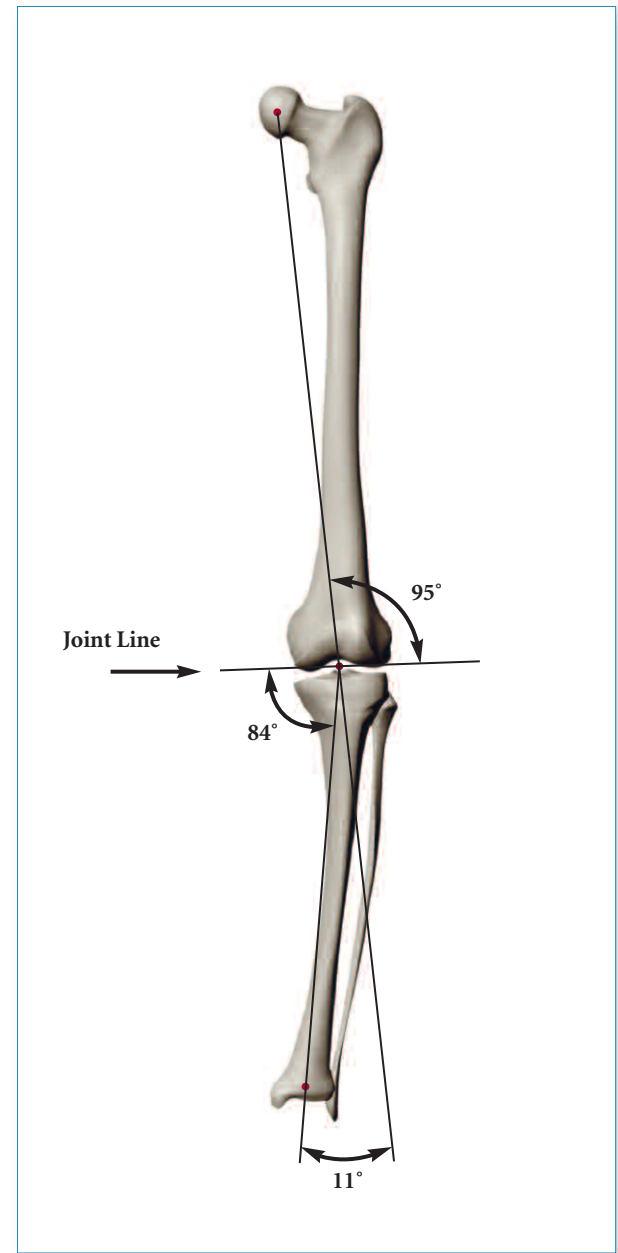
**Example 1B**

► Add the joint line.



**Example 1C**

- ▶ The joint angles (FJA, TJA) are measured and compared to normal joint angles.
- ▶  $\emptyset$  FJA = Observed FJA compared to  $87^\circ$  lateral.
- ▶  $\emptyset$  TJA = Observed TJA compared to  $87^\circ$  medial.
- ▶ The overall deformity shown here is  $11^\circ$  varus. The femoral joint angle (FJA) is normally  $87^\circ$ . Since the femoral joint angle shown here is  $95^\circ$ , there is an "error", or deviation, that we call the  $\emptyset$  FJA. In this case, the  $\emptyset$  FJA is  $8^\circ$ . Therefore, we have an  $8^\circ$  varus deformity at the femur.
- ▶ The tibial joint angle (TJA) is normally  $87^\circ$ . Since the angle in this example is  $84^\circ$ , the  $\emptyset$  TJA is equal to  $3^\circ$ . This results in a deformity at the tibia of  $3^\circ$  varus.
- ▶ To analyze and check your work, make sure the sum of the  $\emptyset$  FJA and the  $\emptyset$  TJA are equal to the overall deformity;  $\emptyset$  FJA and  $\emptyset$  TJA = overall deformity;  $8^\circ$  varus and  $3^\circ$  varus =  $11^\circ$  varus.
- ▶ We can also summarize saying this example shows an  $11^\circ$  overall varus deformity of which  $8^\circ$  is in the distal femur and  $3^\circ$  is in the proximal tibia.

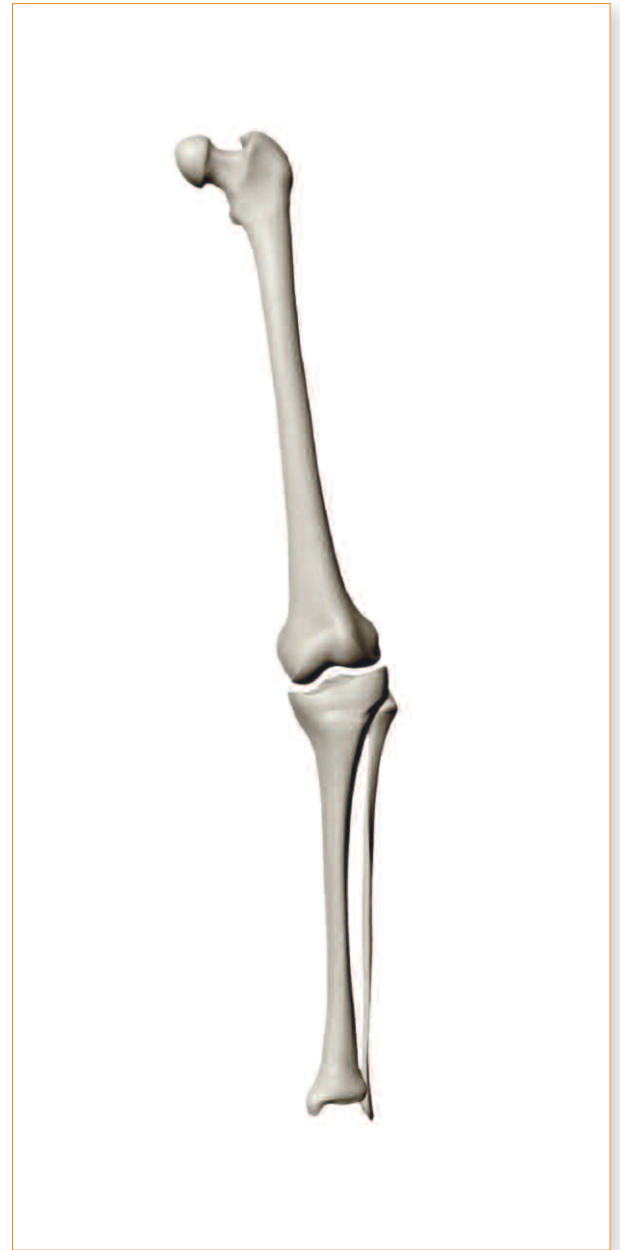


**Example 1D**

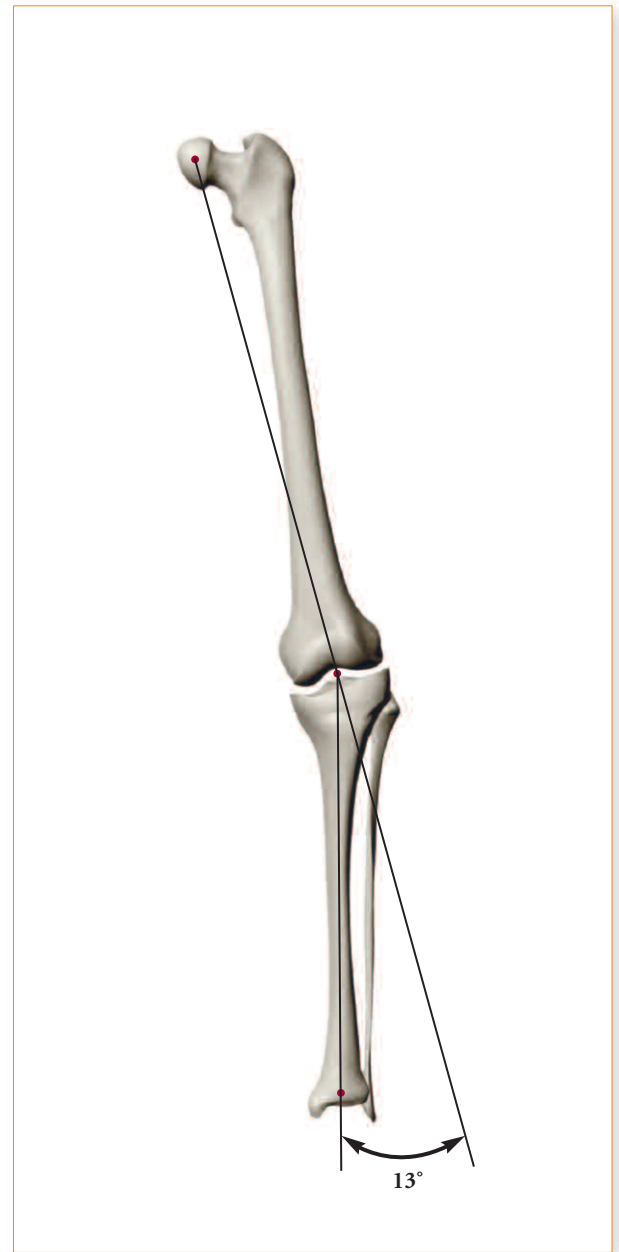

## EXAMPLE 2

### Varus Deformity of the Tibia

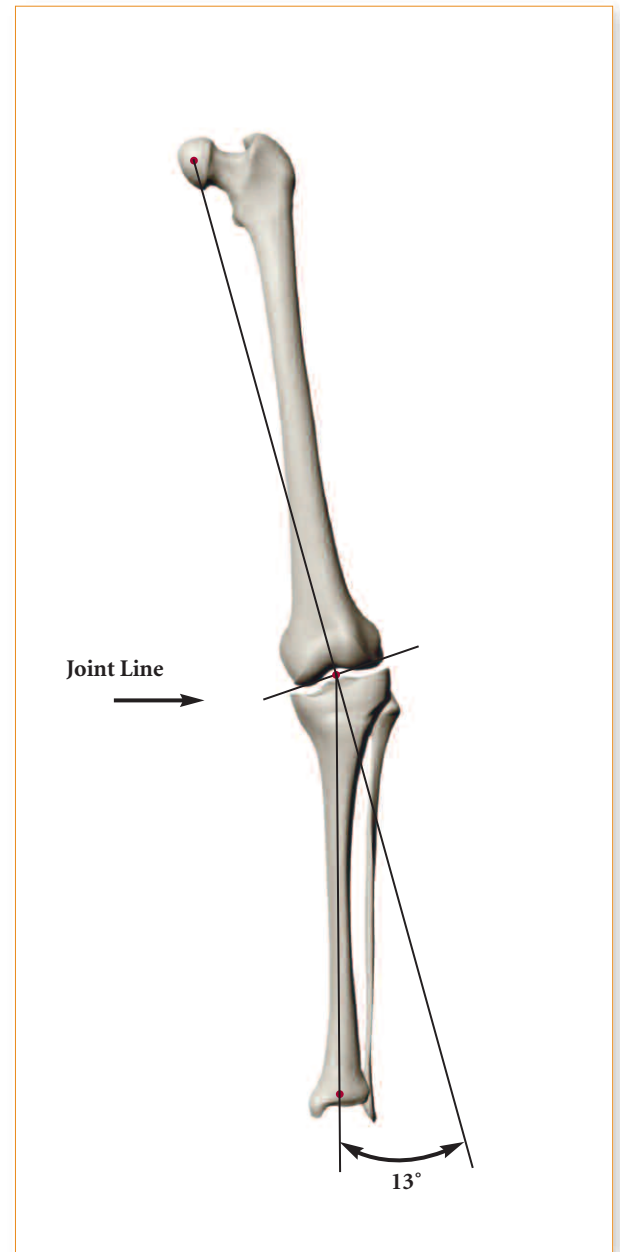


- ▶ The axes are marked and the overall deformity is shown to be in 13° of varus.



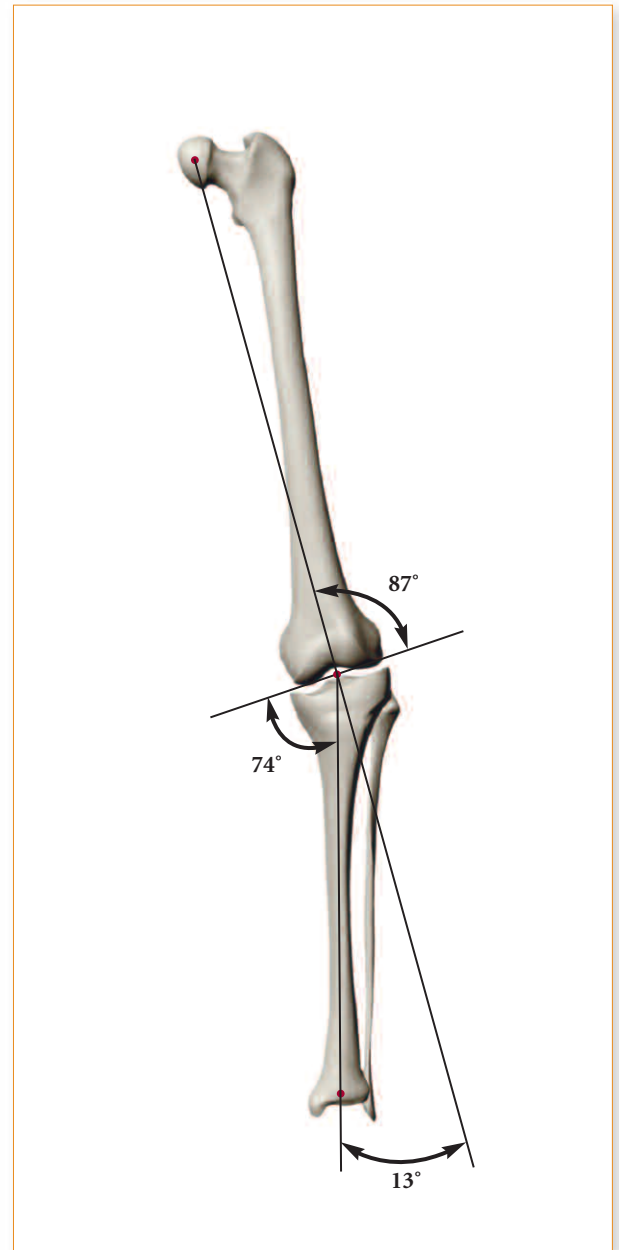
**Example 2A**

- ▶ Add the joint line.



**Example 2B**

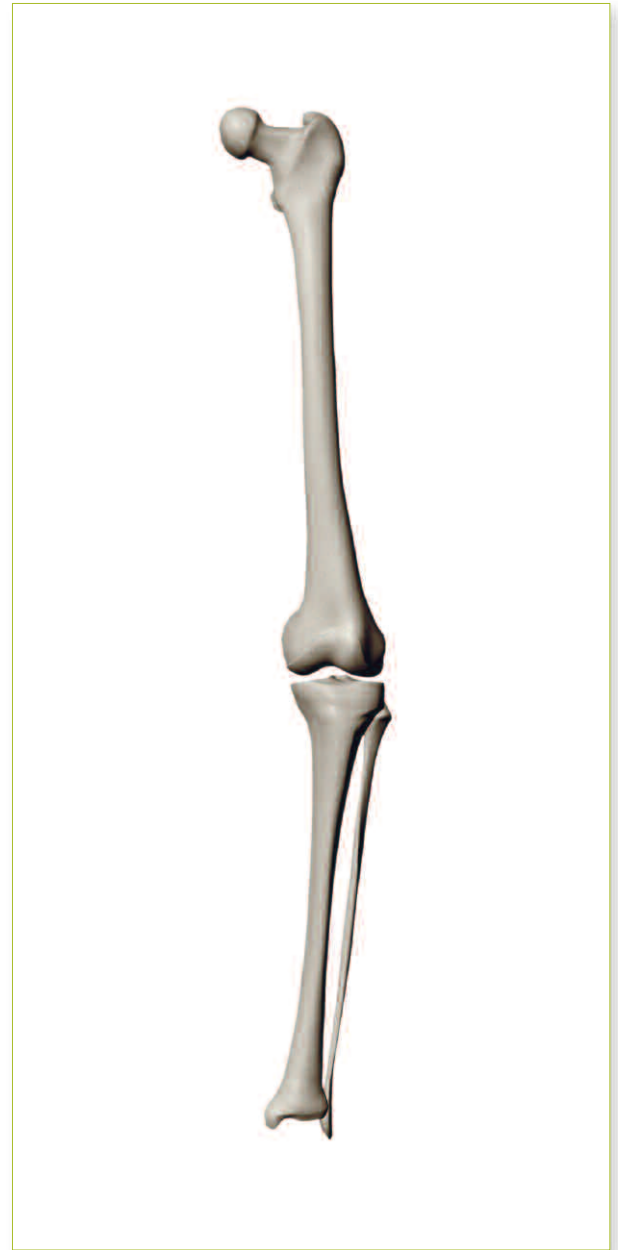
- ▶ Determine all the important angles.



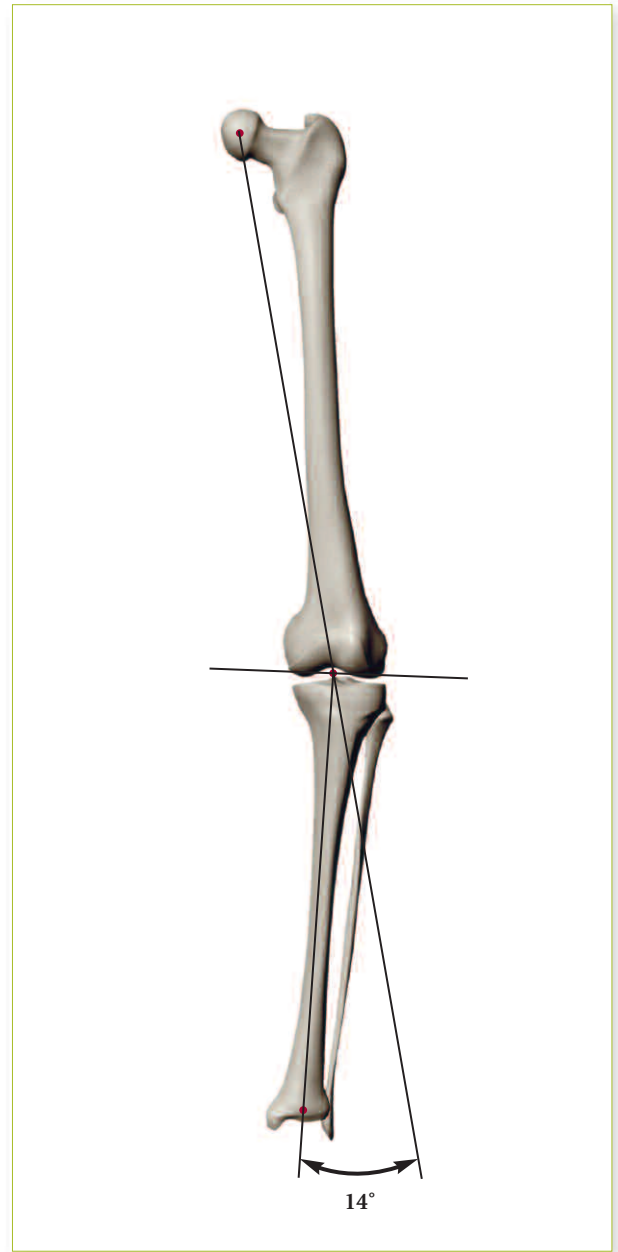
**Example 2C**

## EXAMPLE 3

**Varus Deformity at the Femur with Minor  
"Compensation" at the Tibia**

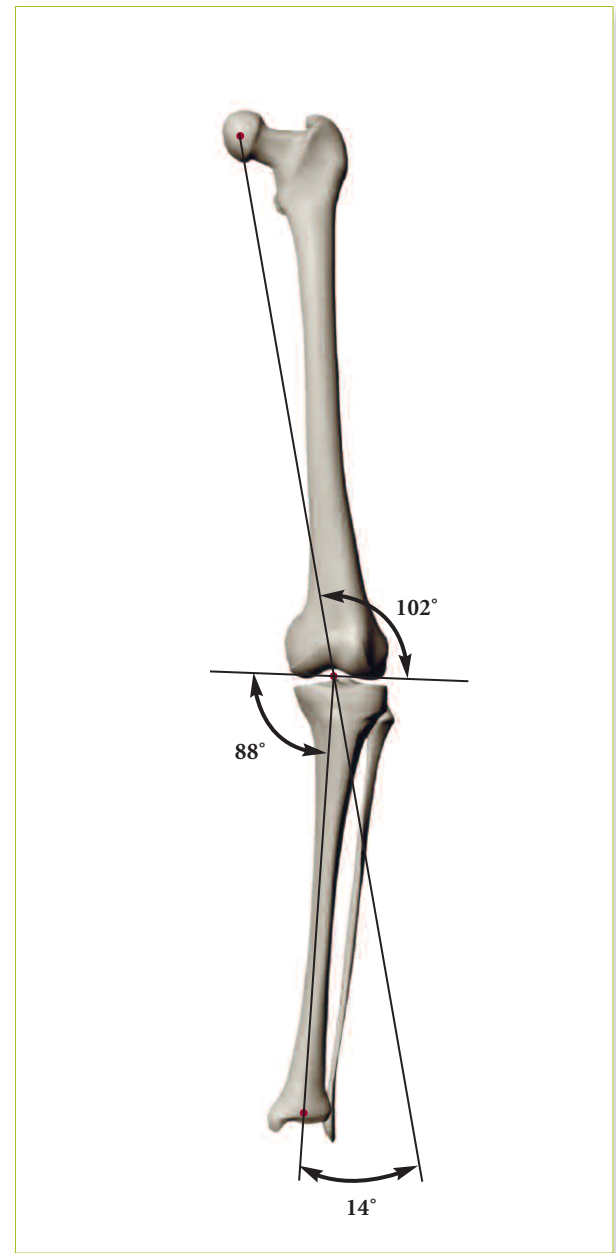


- ▶ The axes are marked and the overall deformity is indicated to be 14° varus.



**Example 3A**

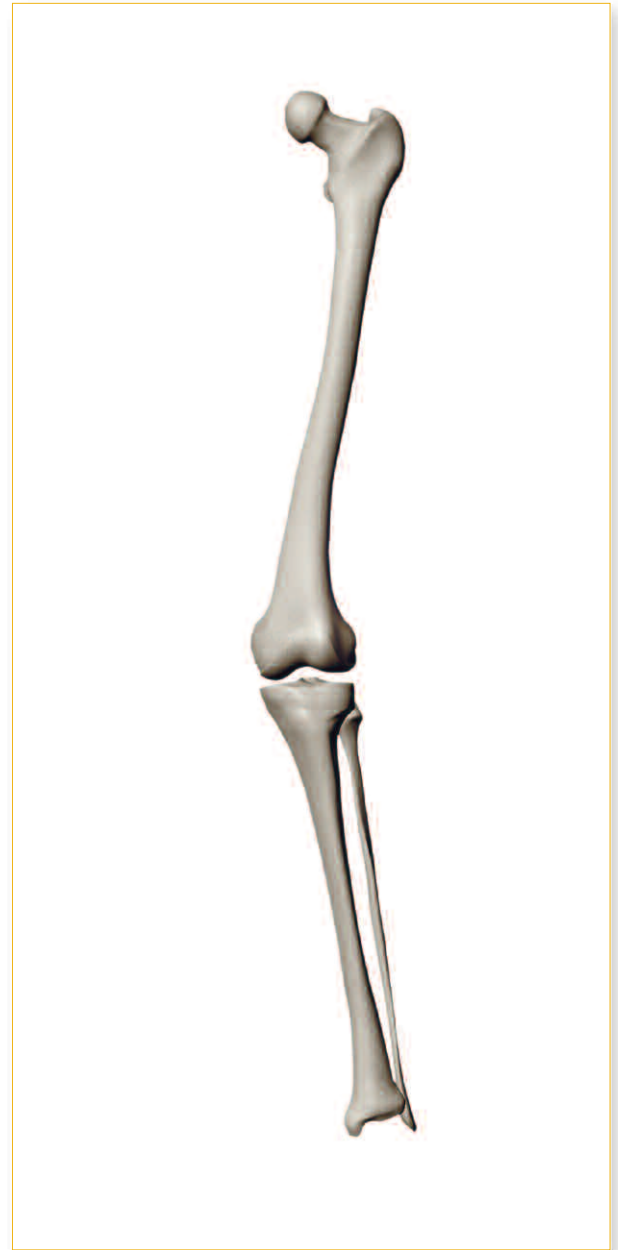- ▶ Determine all the important angles.
- ▶ The overall deformity is  $14^\circ$  varus.
- ▶ The FJA here is  $102^\circ$ . Because the normal FJA is  $87^\circ$ , and angle of  $102^\circ$  represents a  $\Delta$  FJA of  $15^\circ$  varus, or a varus deformity of  $15^\circ$  in the femur.
- ▶ The TJA here is  $88^\circ$ . Because the normal TJA is  $87^\circ$ , an angle of  $88^\circ$  represents a  $\Delta$  TJA of  $1^\circ$  valgus. Therefore, the deformity in the tibia is 1 of valgus angulation.
- ▶  $\Delta$  FJA +  $\Delta$  TJA = Overall Deformity.
- ▶  $15^\circ$  varus and  $1^\circ$  valgus =  $14^\circ$  varus.
- ▶ Therefore, the overall varus deformity is  $14^\circ$  because there is  $15^\circ$  of varus deformity from the femur and  $1^\circ$  of valgus compensation at the tibial side.



**Example 3B**

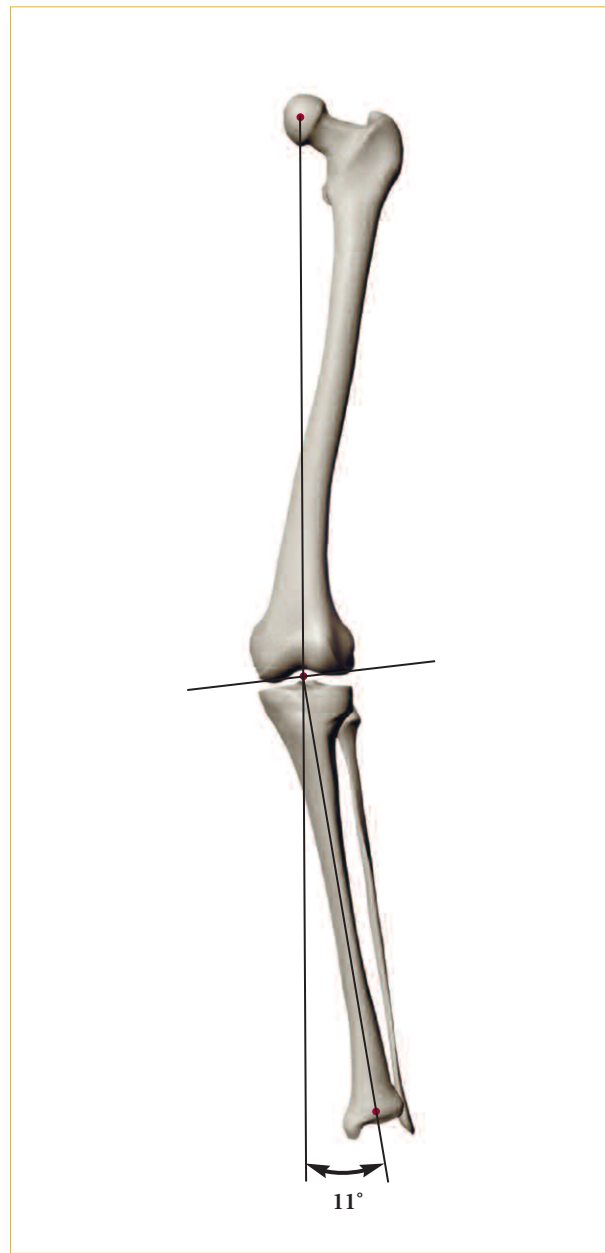
## EXAMPLE 4

**Valgus Deformity at Both the Femur and Tibia**



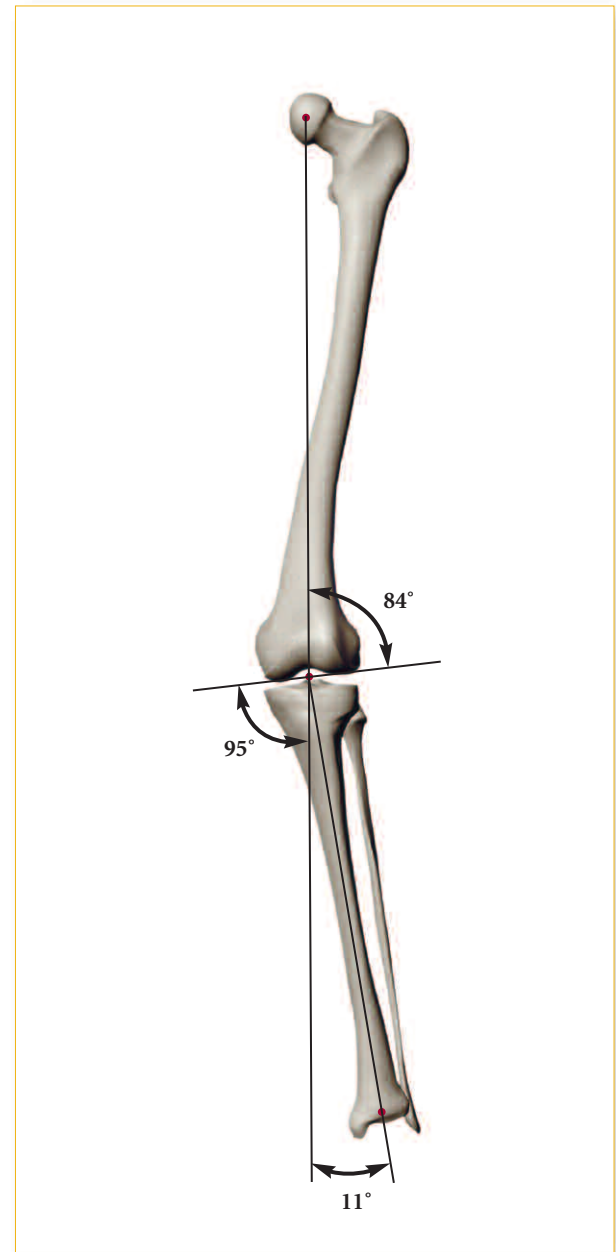


- ▶ The axes are marked and the overall deformity is indicated to be 11° of valgus.



**Example 4A**

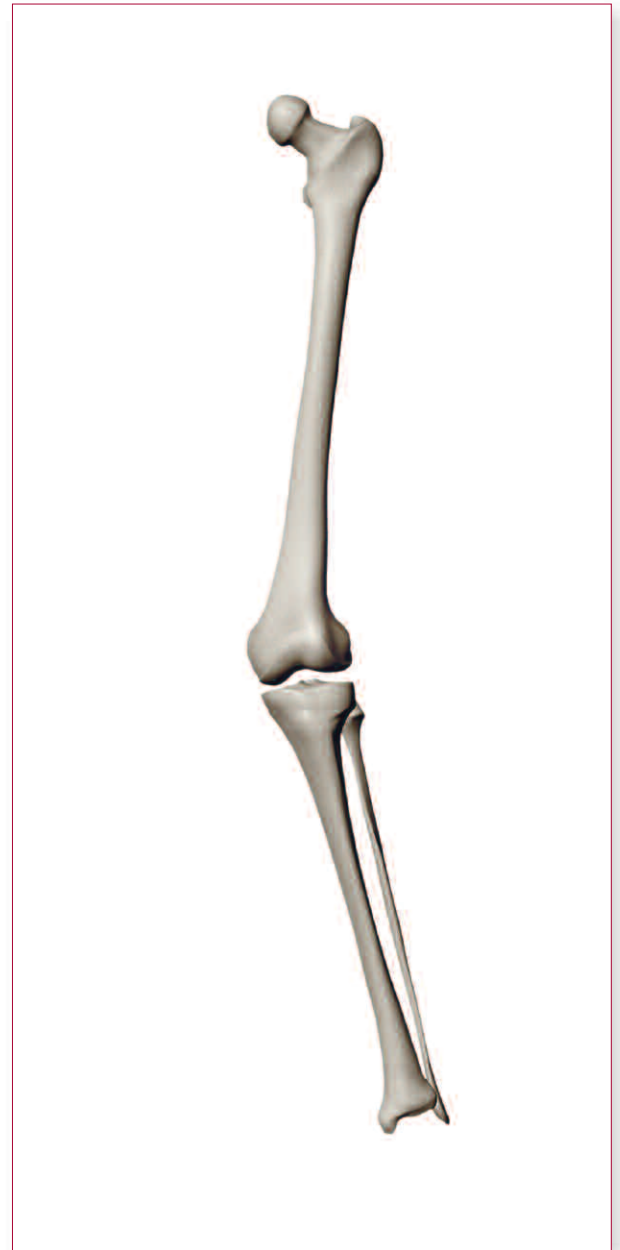- ▶ Determine all the important angles.
- ▶ The overall deformity is  $11^\circ$  valgus.
- ▶ The FJA is  $84^\circ$ . Normally, the FJA is  $87^\circ$ . Therefore,  $84^\circ$  represents a  $\Delta$  FJA of  $3^\circ$ . This also equals a  $3^\circ$  valgus deformity at the femur.
- ▶ The TJA is  $95^\circ$ . Since the normal TJA is  $87^\circ$ , an angle of  $95^\circ$  represents a  $\Delta$  TJA of  $8^\circ$ . Thus, there is an  $8^\circ$  valgus deformity at the tibia.
- ▶  $\Delta$  FJA and  $\Delta$  TJA = overall deformity.
- ▶  $3^\circ$  valgus and  $8^\circ$  valgus =  $11^\circ$  valgus.
- ▶ There is an overall valgus deformity of  $11^\circ$ ,  $3^\circ$  from the femur and  $8^\circ$  from the tibia.



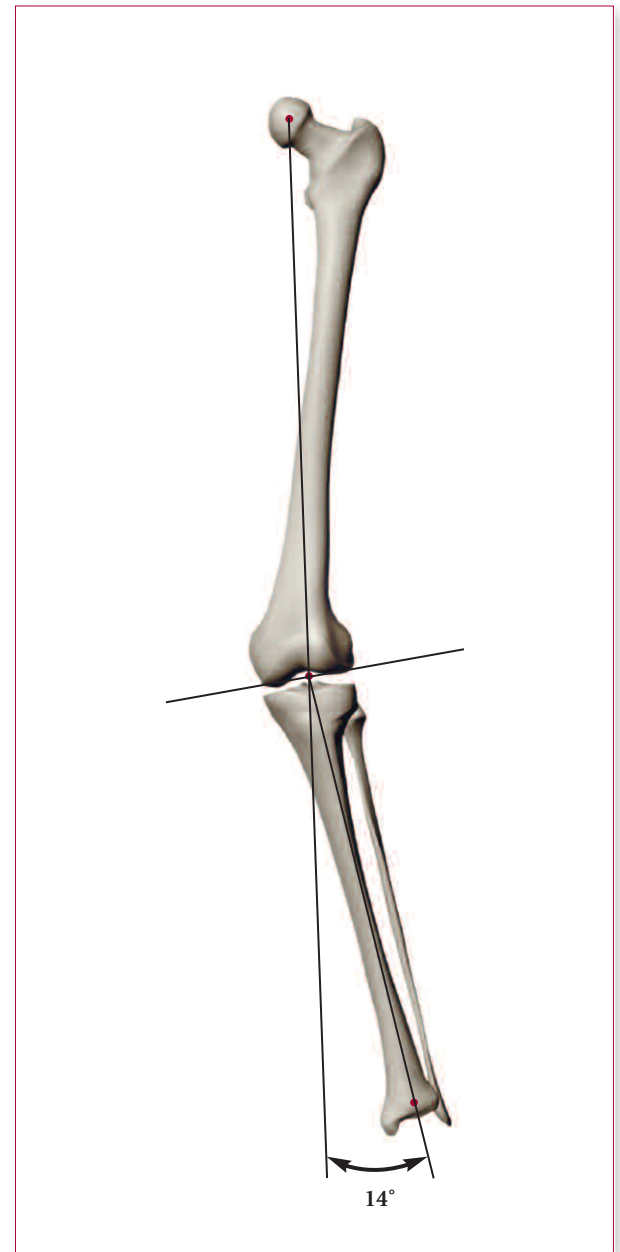
**Example 4B**

## EXAMPLE 5

### Valgus Deformity at the Femur and Tibia

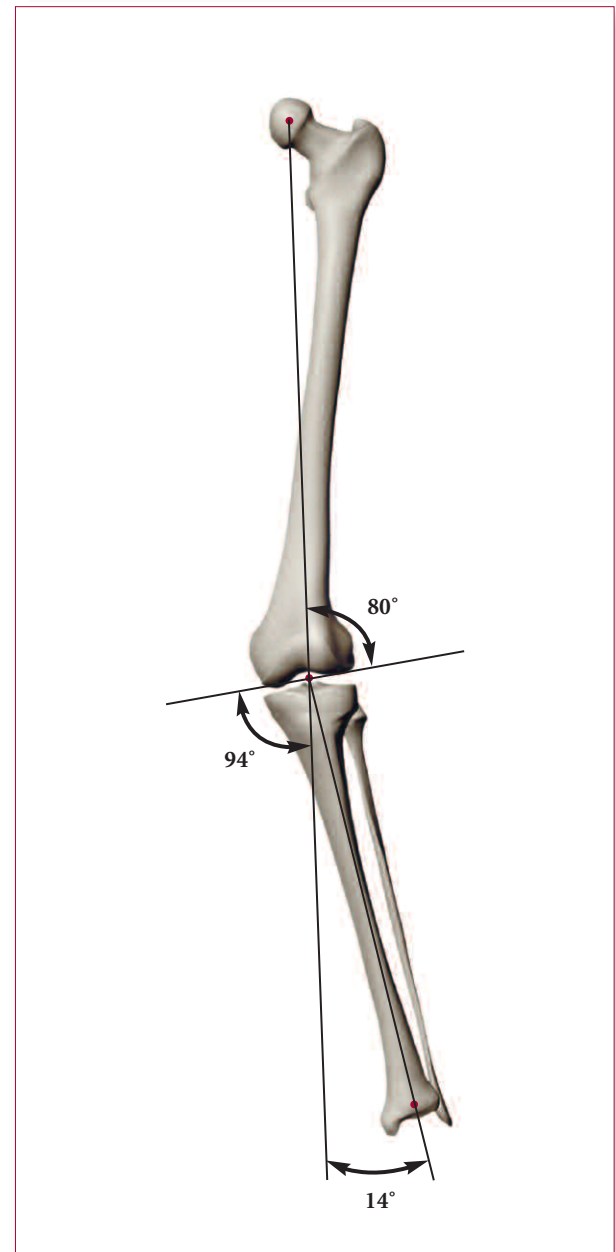


- ▶ The axes are marked and the overall deformity is indicated to be 14° valgus.



**Example 5A**

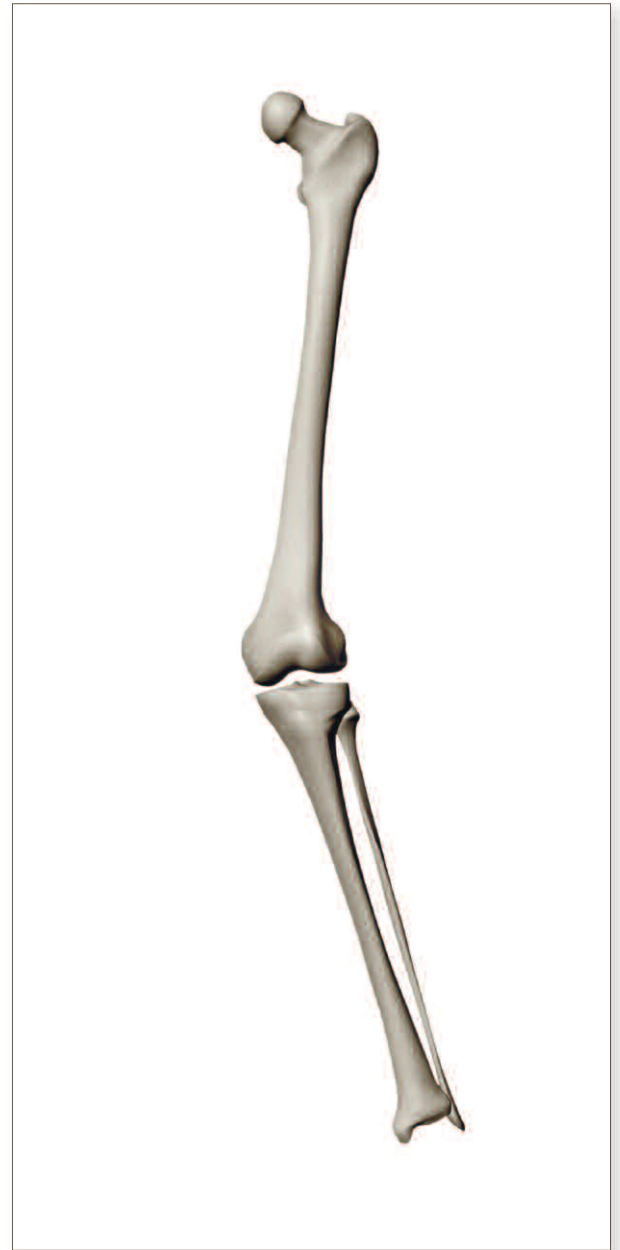- ▶ All important angles are determined.
- ▶ The overall deformity is  $14^\circ$  valgus.
- ▶ The FJA is  $80^\circ$ . Normally, the FJA is  $87^\circ$ . Therefore,  $80^\circ$  represents a  $\Delta$  FJA of  $7^\circ$ , indicating a  $7^\circ$  valgus deformity at the femur.
- ▶ The TJA is  $94^\circ$ . Normally, the TJA is  $87^\circ$ . Therefore,  $94^\circ$  represents a  $\Delta$  TJA of  $7^\circ$ , indicating a  $7^\circ$  valgus deformity at the tibia.
- ▶  $\Delta$  FJA and  $\Delta$  TJA = overall deformity.
- ▶  $7^\circ$  valgus and  $7^\circ$  valgus =  $14^\circ$  valgus.
- ▶ There is an overall deformity of  $14^\circ$  valgus, with half from the femur and half from the tibia.



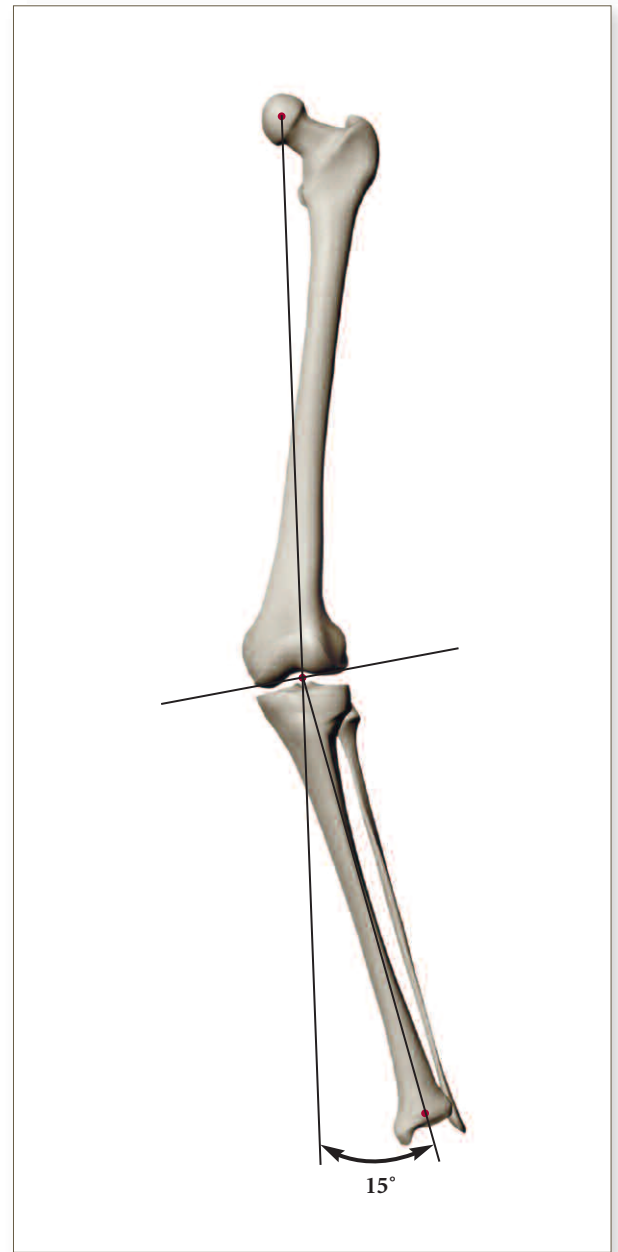
**Example 5B**

## EXAMPLE 6

### Valgus Deformity at the Femur and Tibia

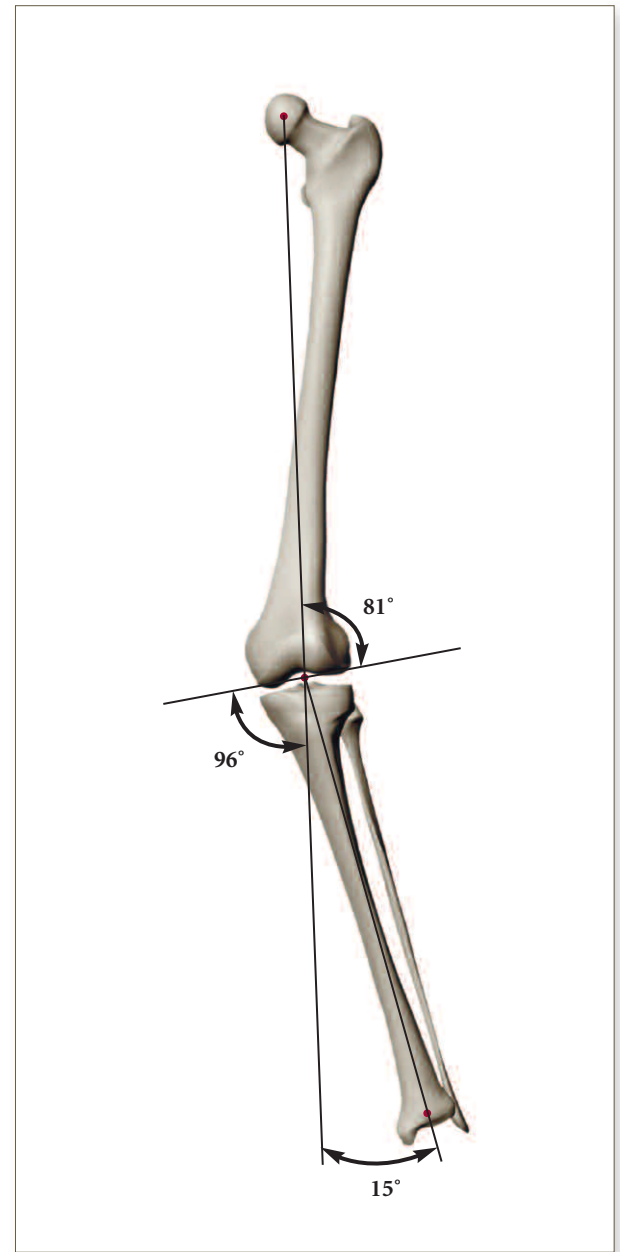


- The axes are marked and the overall deformity is indicated to be 15° valgus.



**Example 6A**

- ▶ All important angles are measured.
- ▶ The overall deformity is 15° valgus.
- ▶ The FJA is 81°. Normally, the FJA is 87°. Therefore, 81° represents a  $\Delta$  FJA of 6° and a valgus deformity at the femur of 6°.
- ▶ The TJA is 96°. Normally, the TJA is 87°. Therefore, 96° represents a  $\Delta$  TJA of 9°. Thus, there is a 9° valgus deformity at the tibia.
- ▶  $\Delta$  FJA and  $\Delta$  TJA = overall deformity.
- ▶ 6° valgus and 9° valgus = 15° valgus.
- ▶ There is a 15° valgus overall deformity, with 6° from the femur and 9° from the tibia.

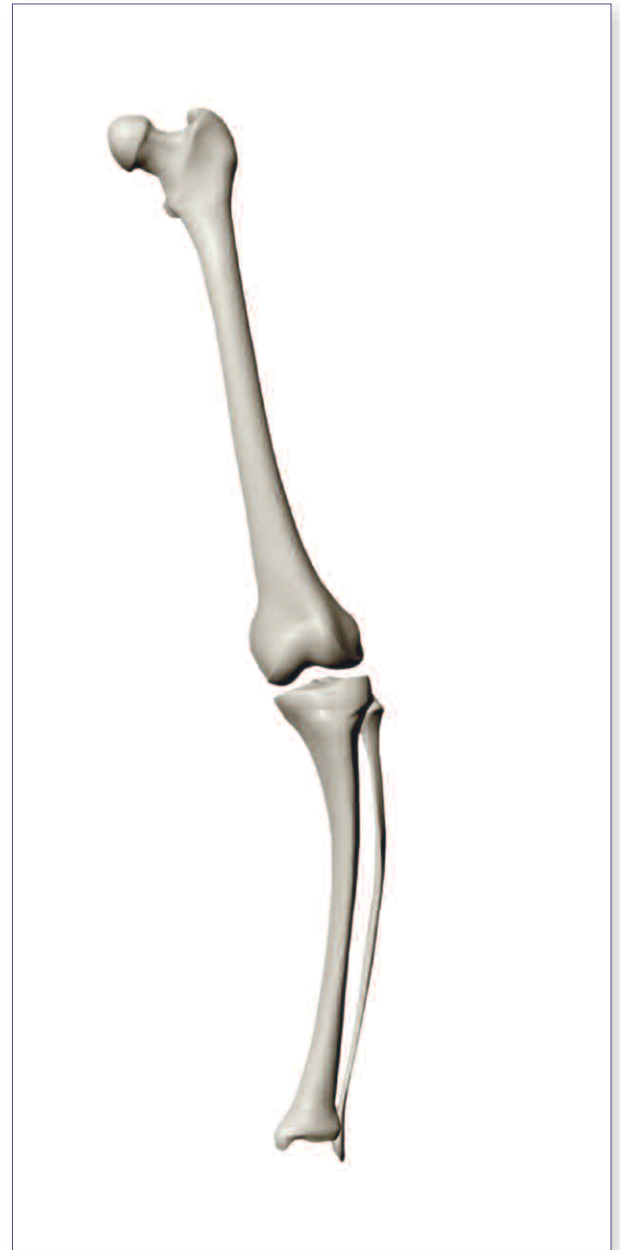


**Example 6B**



## EXAMPLE 7

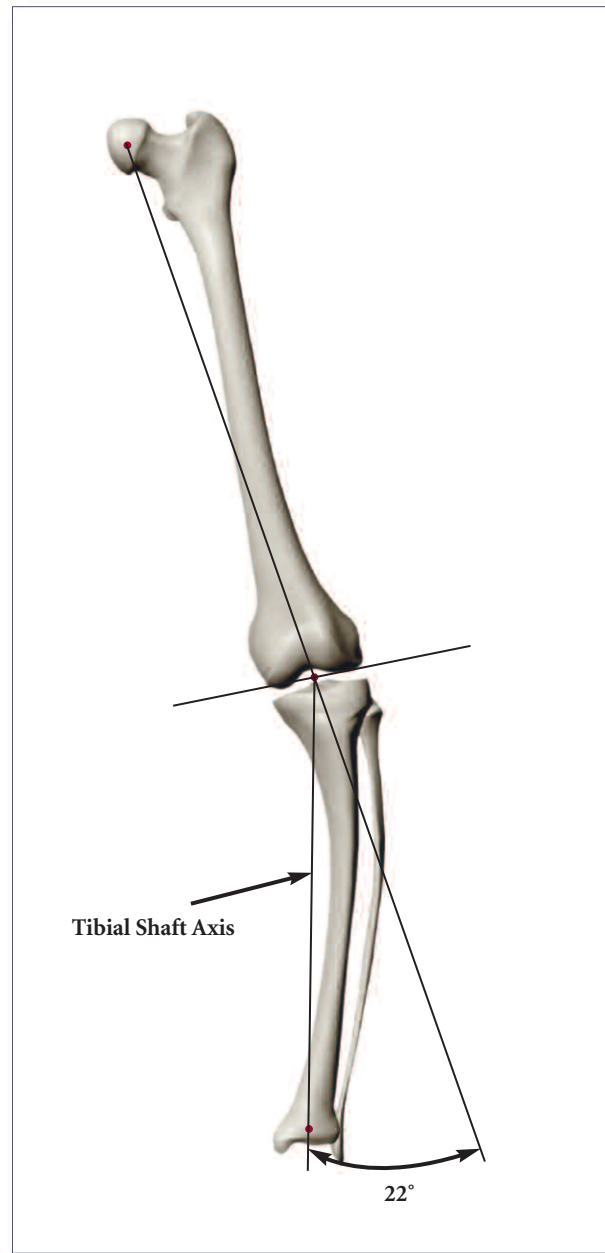
### Extra-articular Varus Angulation of the Tibia



- ▶ The axes are marked and the overall deformity is indicated to be 22° varus.

**Note:**

The mechanical axis of the tibia is drawn from the center of the proximal tibia to the center of the ankle, ignoring the shaft angulation.

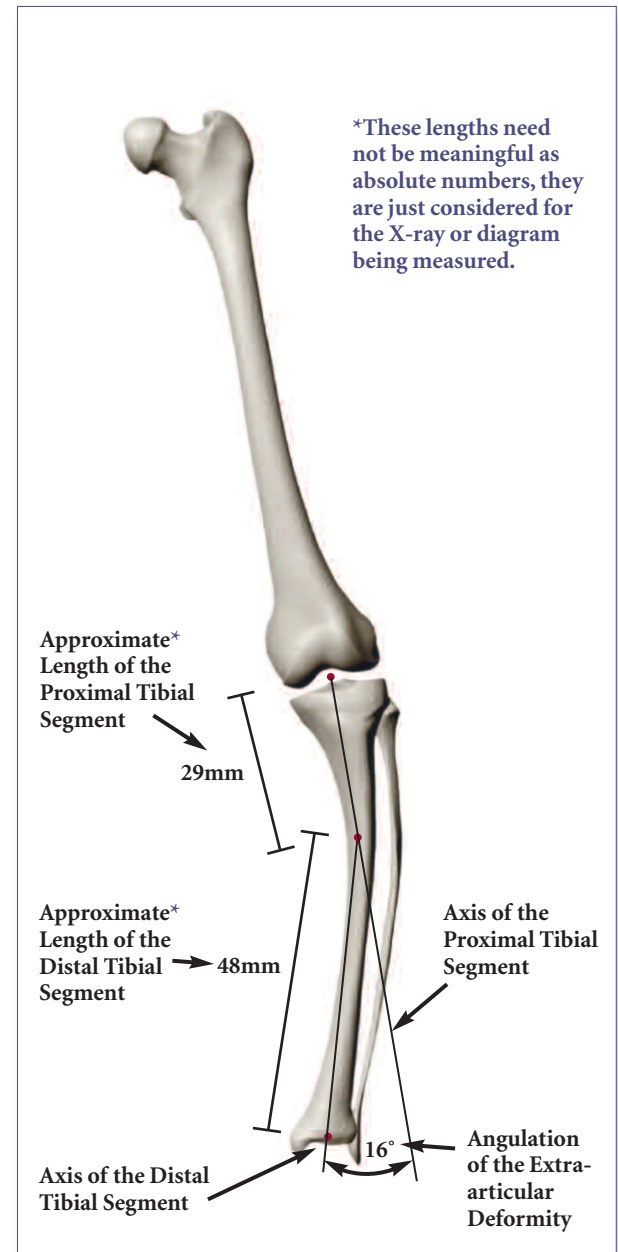


**Example 7A**

- ▶ The angulation at the extra-articular deformity is 16°.
- ▶ The proportional distance from the ankle to the knee is calculated as follows:
 
$$\frac{48}{48+29} = \frac{48}{77} = 62\%;$$
 therefore, 62% of 16° equals 9.92° which is about 10°.
- ▶ Thus, the contribution of extra-articular angulation to the overall knee alignment is about 10°.

**Note:**

The length units used in the proportional distance are meaningless here because they “cancel” due to proportionality.

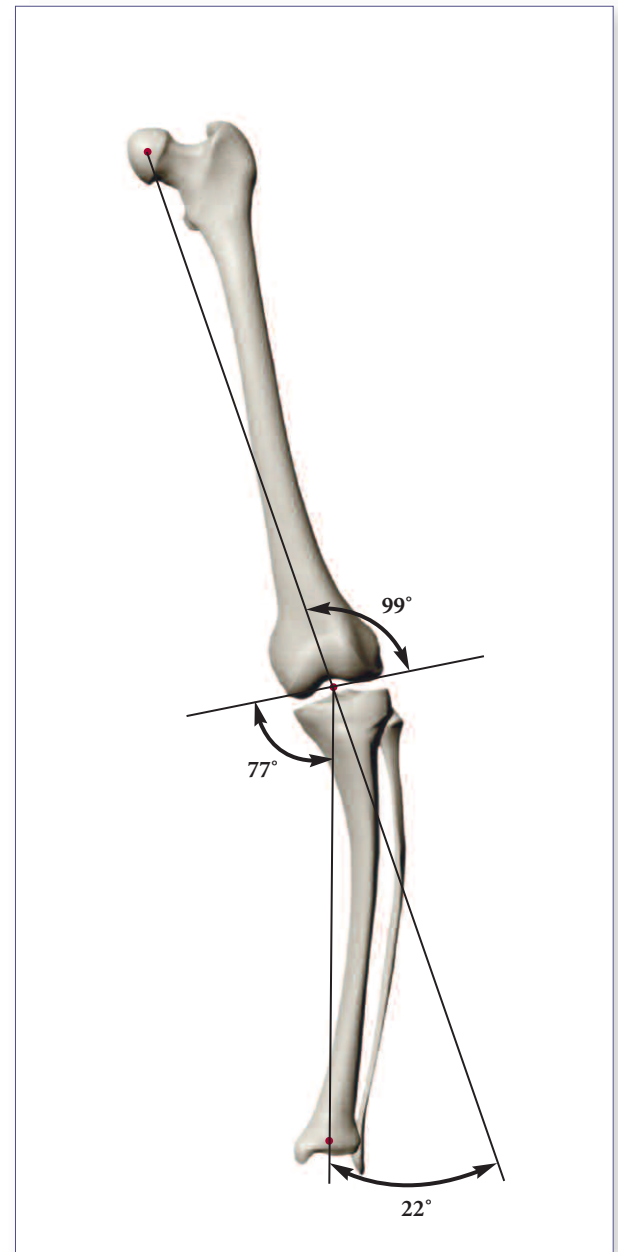


**Example 7B**

- ▶ All the important angles are determined.
- ▶ The overall deformity is 22° varus.
- ▶ The FJA is 99°. Normally the FJA is 87°. Therefore, 99° represents a  $\Delta$  FJA of 12° and indicates a 12° varus deformity at the femur.
- ▶ The TJA is 77°. Normally, the TJA is 87°. Therefore, 77° represents a  $\Delta$  TJA of 10° and indicates a 10° varus deformity at the tibia.
- ▶  $\Delta$  FJA and  $\Delta$  TJA = overall deformity.
- ▶ 12° varus and 10° varus = 22° varus.
- ▶ The tibial extra-articular angulation of 16° (derived from the calculation on the previous page) contributed 10° of varus to the knee alignment. Therefore, the 10° overall tibial contribution is due essentially solely to the extra-articular deformity.

**Summary:**

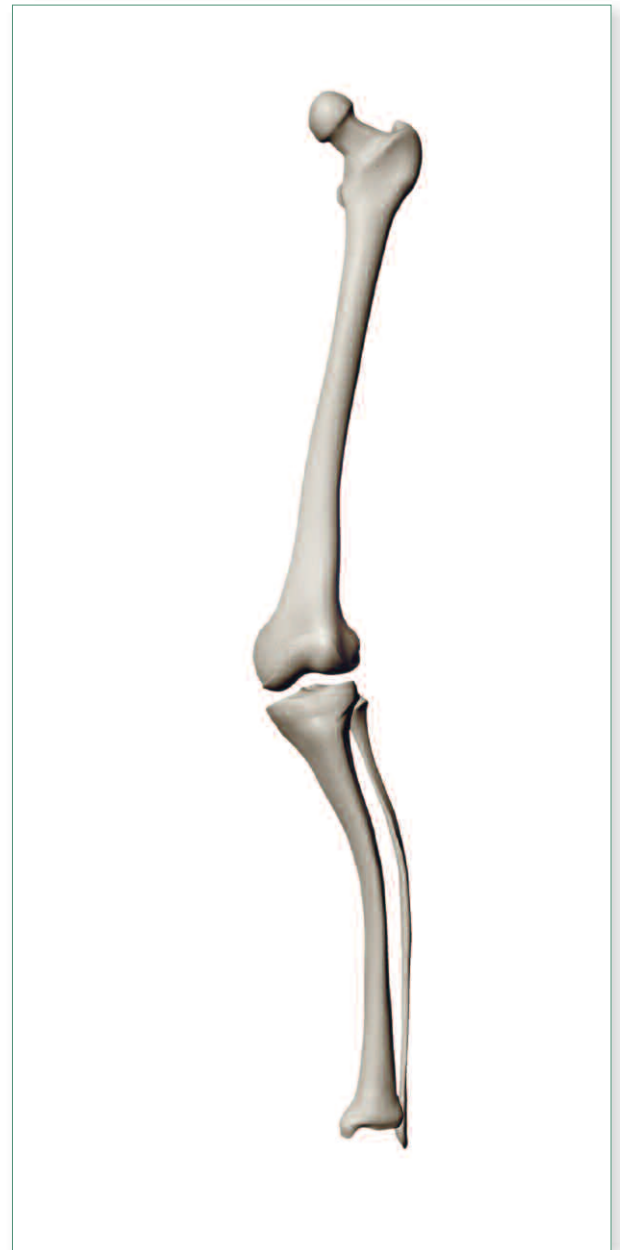
There is a 22° overall varus knee alignment. 12° of the deformity is located at the femur, and 10° is found within the tibia. The 10° at the proximal tibia is due to the extra-articular tibial deformity, which is 16° at its apex and contributes 10° at the joint level.



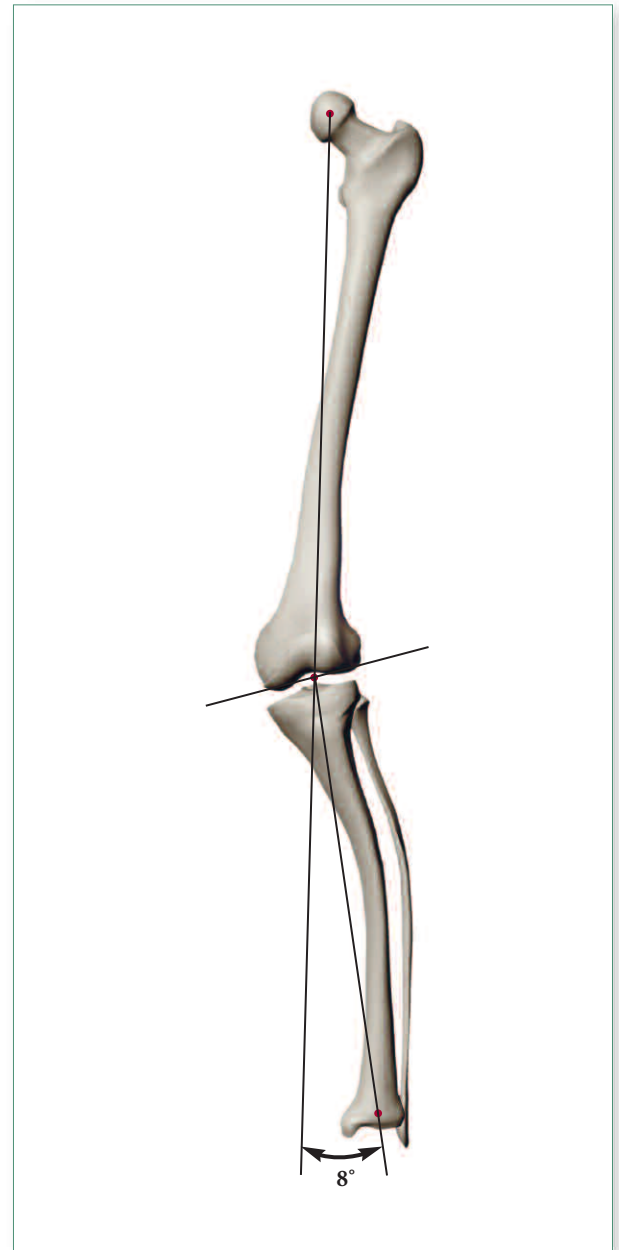
**Example 7C**

## EXAMPLE 8

**Valgus Deformity at the Femur and  
Extra-articular Varus Tibial Angulation**



- ▶ The axes are marked and the overall deformity is indicated to be 8° valgus.



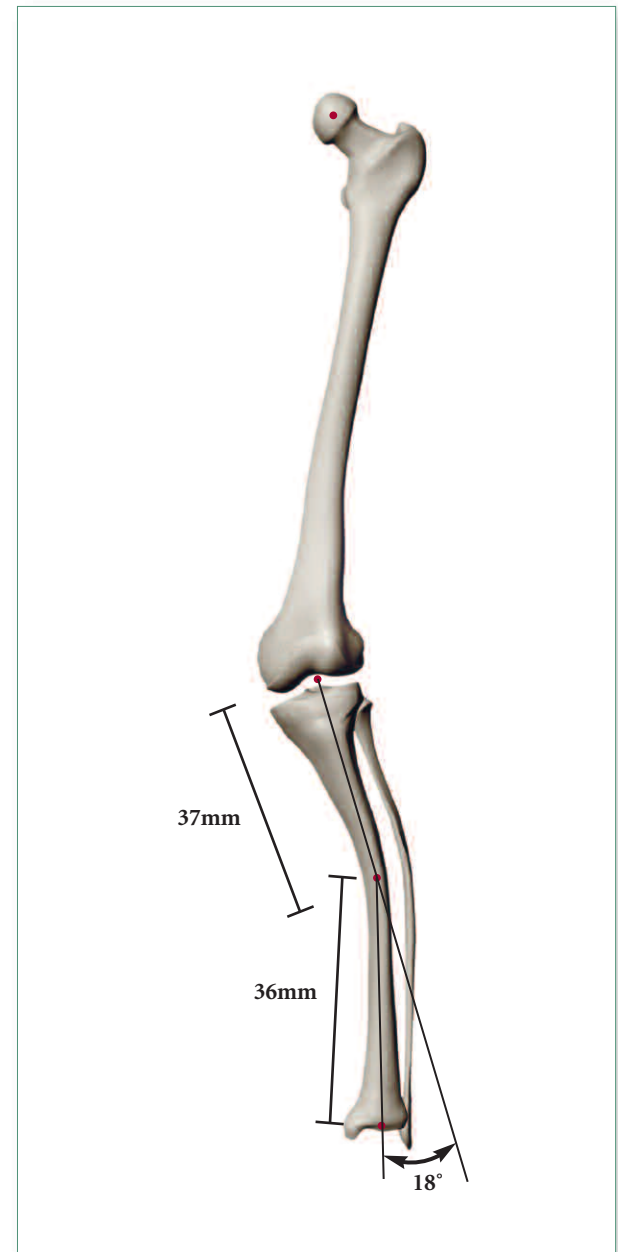
Example 8A

- ▶ The extra-articular tibial angulation.
- ▶ The angulation of the deformity is 18°.
- ▶ The proportional distance from the ankle to the knee is calculated as follows:

$$\frac{36}{36+37} = \frac{36}{73} = 50\%;$$

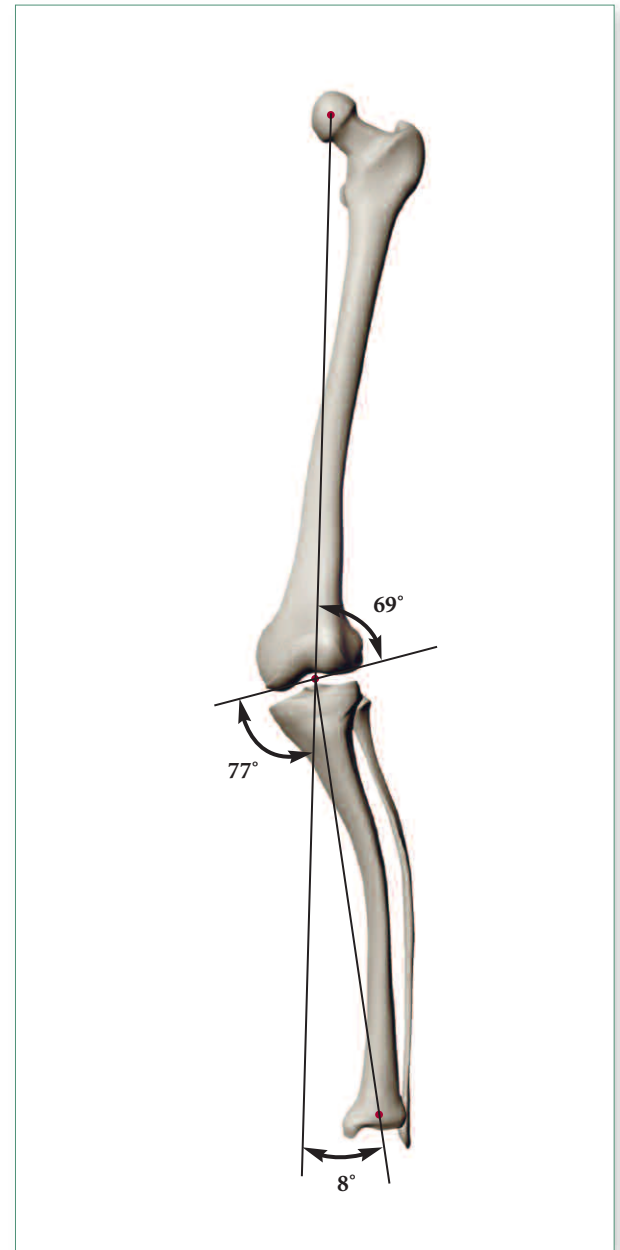
therefore, 50% of 18° equals 9°.

- ▶ Thus, the contribution of extra-articular angulation to the overall knee alignment is 9°.



**Example 8B**

- ▶ All important angles are determined.
- ▶ The overall deformity is 8° valgus.
- ▶ The FJA is 69°. Normally, the FJA is 87°. Therefore, an angle of 69° represents a  $\Delta$  FJA of 18° and indicates an 18° valgus deformity at the femur.
- ▶ The TJA is 77°. Normally, the TJA is 87°. Therefore, an angle of 77° represents a  $\Delta$  TJA of 10° and indicates a 10° varus deformity at the tibia.
- ▶  $\Delta$  FJA and  $\Delta$  TJA = overall deformity.
- ▶ 18° valgus and 10° varus = 8° valgus.
- ▶ There is an 8° overall valgus knee deformity, an 18° valgus deformity at the femur and a 10° proximal tibial varus deformity. 9° of the 10° is due to tibial shaft angulation.

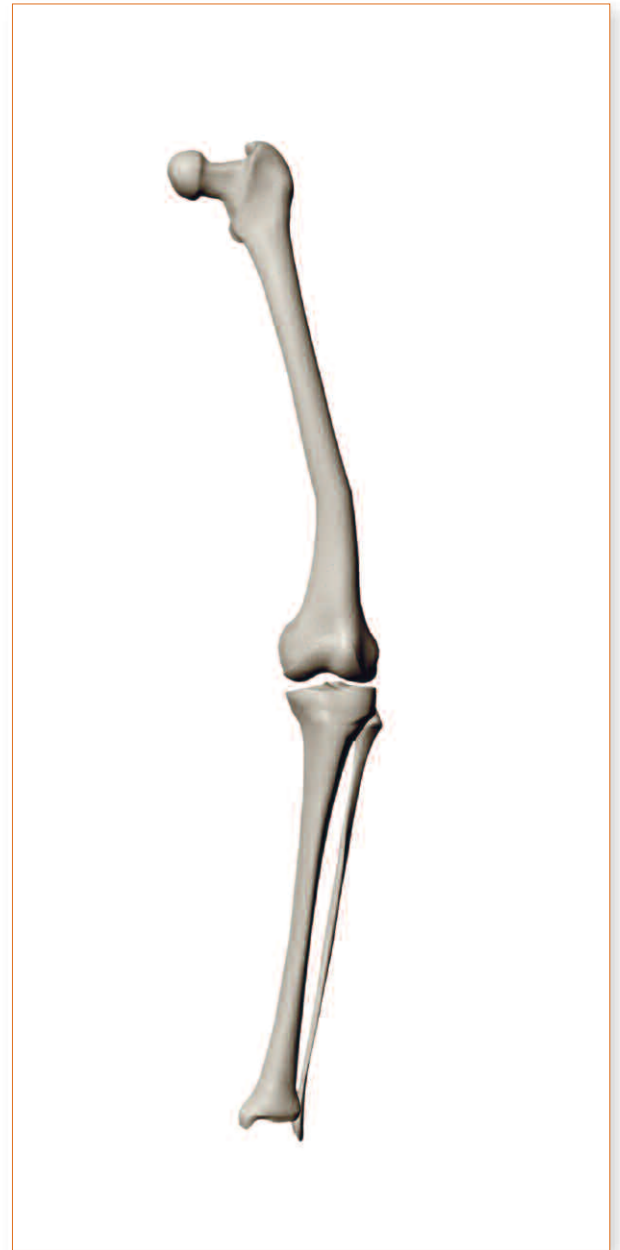


**Example 8C**

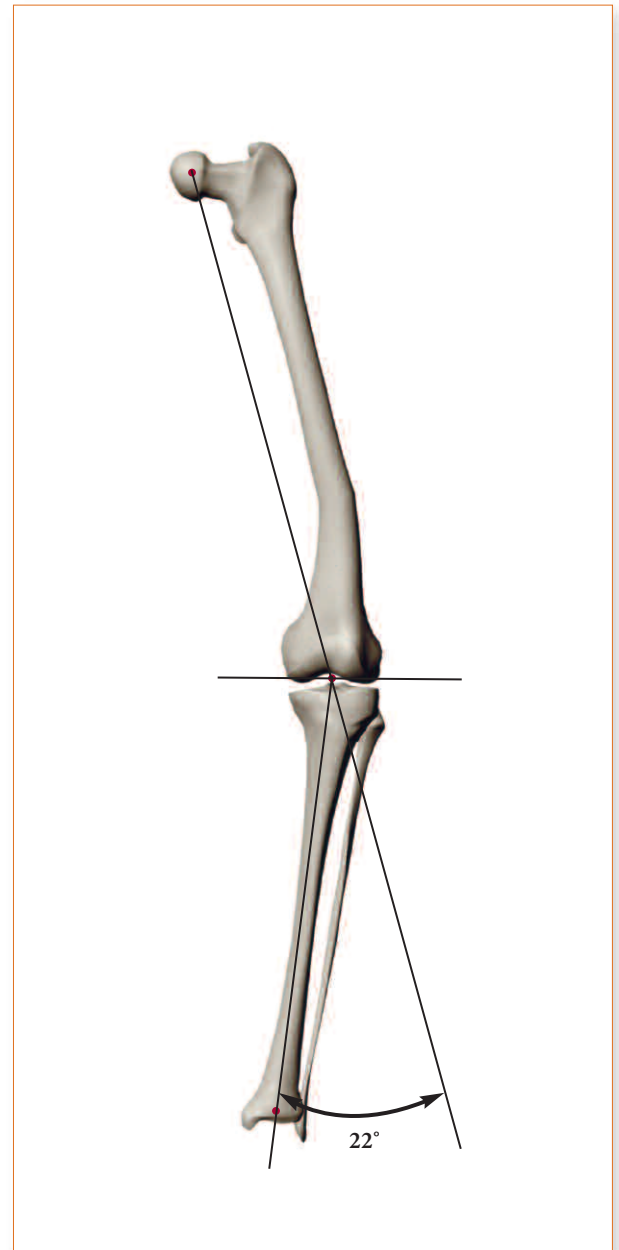


## EXAMPLE 9

### Extra-articular Varus Angulation of the Femur



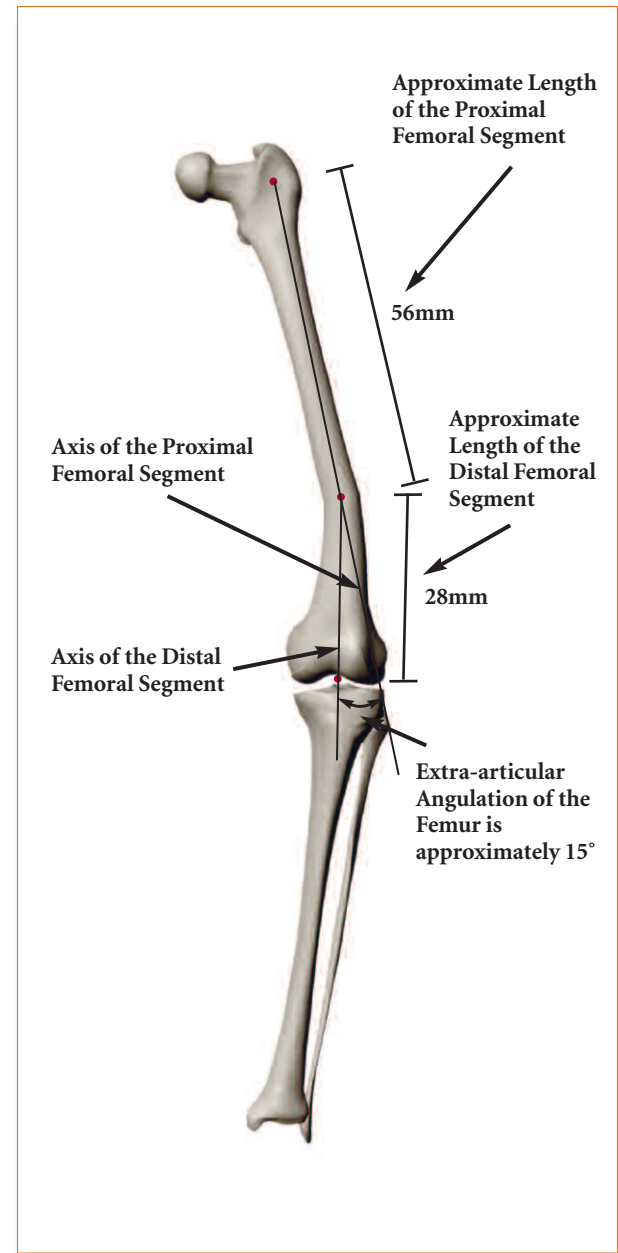
- ▶ The axes are marked and the overall deformity is indicated to be 22° varus.



**Example 9A**

- ▶ Extra-articular femoral angulation of 15°.
- ▶ The angulation of the deformity is 15°.
- ▶ The proportional distance from the hip to the knee is calculated as follows:  

$$\frac{56}{56+28} = \frac{56}{84} = 66.7\% \approx 67\%;$$
 therefore, 67% of 15° equals 10°.
- ▶ Thus, the contribution of extra-articular angulation to the overall knee alignment is about 10°.

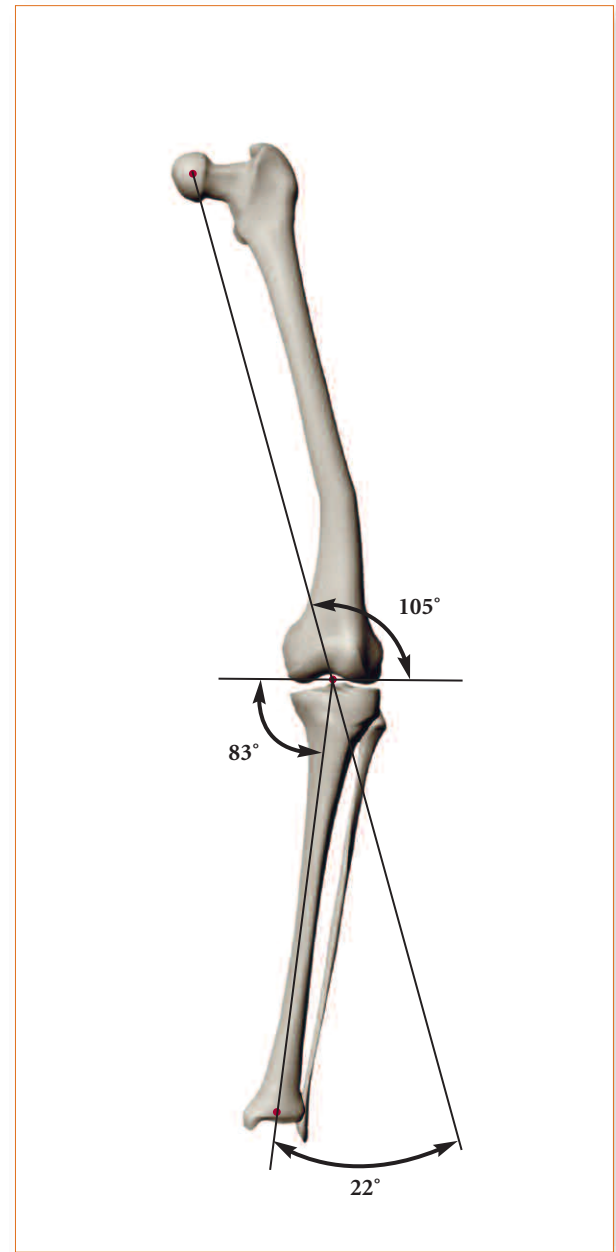


**Example 9B**

- ▶ All important angles are determined.
- ▶ The overall deformity is 22° varus.
- ▶ The FJA is 105°. Normally, the FJA is 87°. Therefore, 105° represents a  $\emptyset$  FJA of 18° and indicates an 18° varus deformity at the femur.
- ▶ The TJA is 83°. Normally, the TJA is 87°. Therefore, an angle of 83° represents a  $\emptyset$  TJA of 4° and indicates a 4° varus deformity at the tibia.
- ▶  $\emptyset$  FJA and  $\emptyset$  TJA = overall deformity.
- ▶ 18° varus and 4° varus = 22° varus.
- ▶ The extra-articular contribution is 10° varus.

**Summary:**

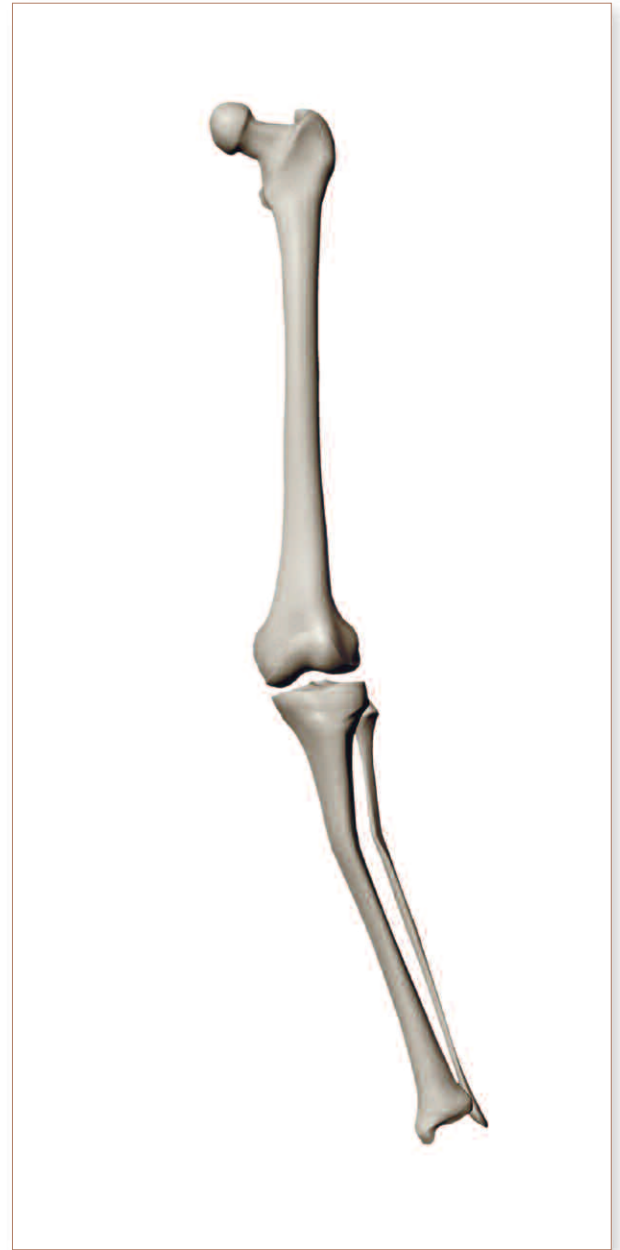
There is 22° of varus angulation at the knee, 18° of which is due to the deformity at the femur, with 10° of this is due to the 15° extra-articular deformity at the distal femur. There is 4° of varus at the tibia.



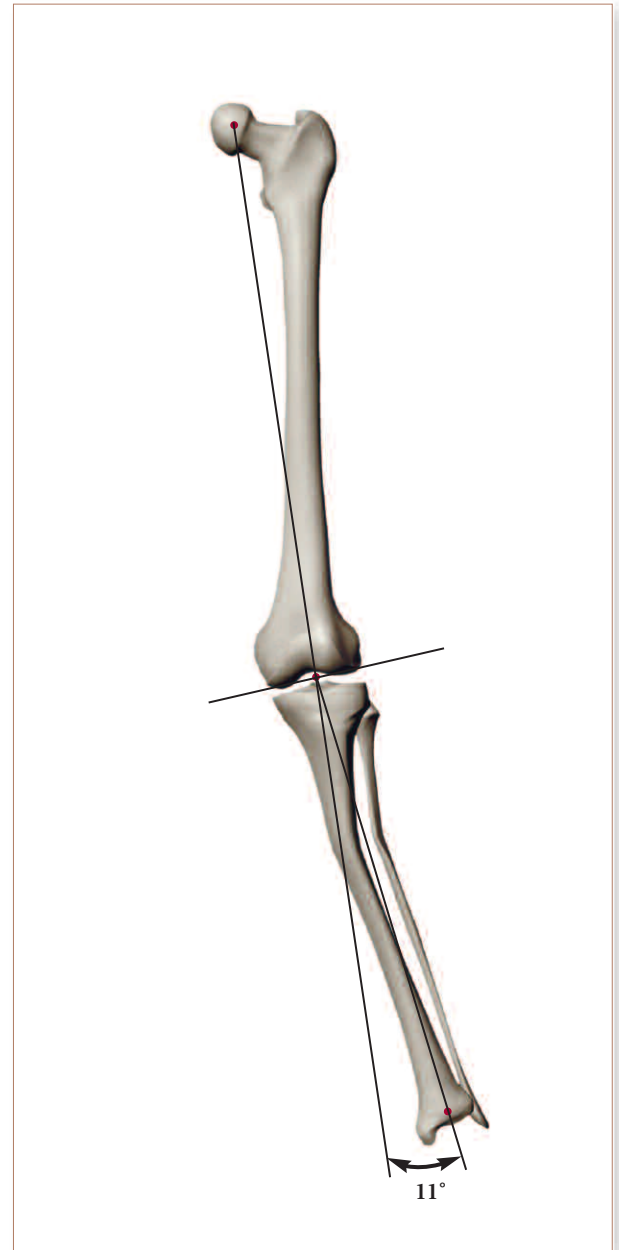**Example 9C**

## EXAMPLE 10

**Valgus Deformity of the Femur with  
Extra-articular Valgus Tibial Angulation**

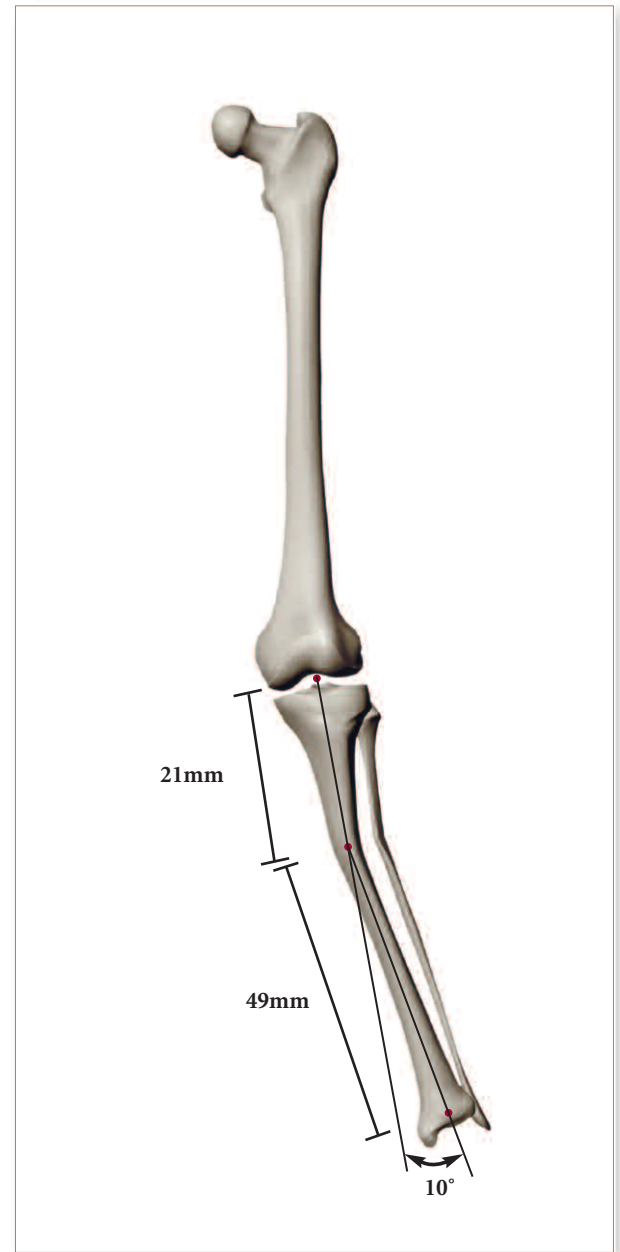


- ▶ The axes are marked and the overall deformity is indicated to be 11° valgus.



**Example 10A**

- ▶ The angulation of the deformity is 10°.
- ▶ The proportional distance from the ankle to the knee is calculated as follows:  
$$\frac{49}{49+21} = \frac{49}{70} = 70\%;$$
therefore, 70% of 10° equals 7°.
- ▶ Thus, the contribution of extra-articular angulation to the overall knee deformity is about 7°.

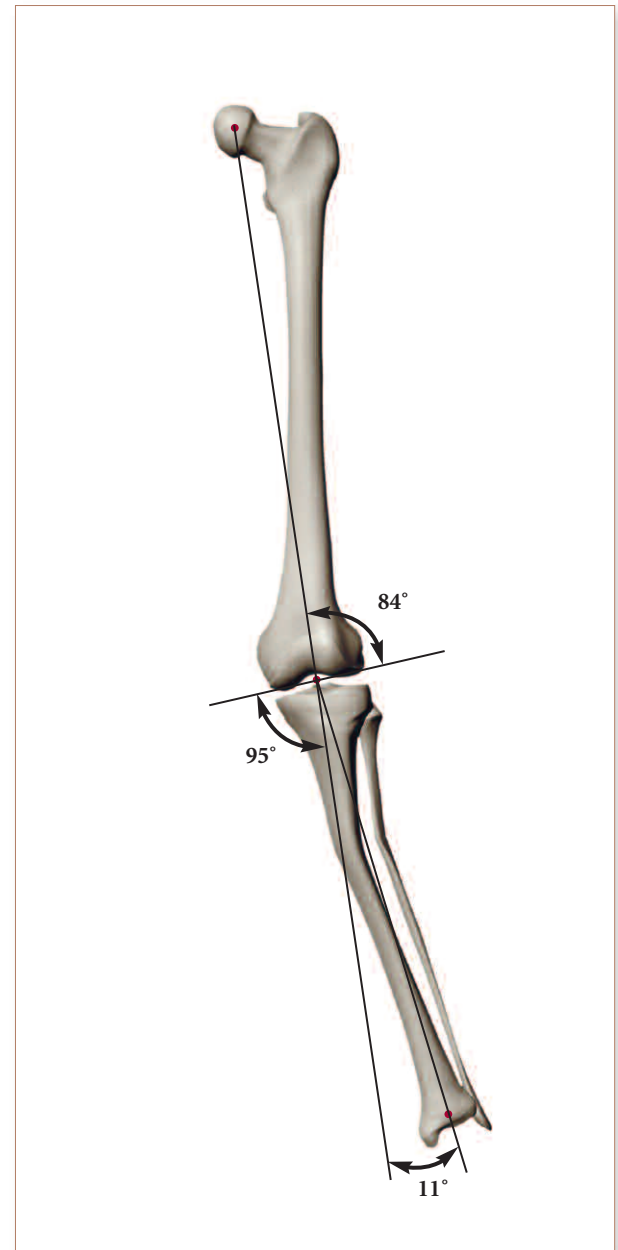


**Example 10B**

- ▶ All important angles are determined.
- ▶ The overall deformity is 11° valgus.
- ▶ The FJA is 84°. Normally, the FJA is 87°. Therefore, 84° represents a  $\emptyset$  FJA of 3°. Thus, there is a 3° valgus deformity at the femur.
- ▶ The TJA is 95°. Normally, the TJA is 87°. Therefore, 95° represents a  $\emptyset$  TJA of 8°. Thus, there is an 8° valgus deformity at the tibia.
- ▶  $\emptyset$  FJA and  $\emptyset$  TJA = overall deformity.
- ▶ 3° valgus and 8° valgus = 11° valgus.
- ▶ The 7° of valgus at the tibia is due to a 10° valgus extra-articular tibial deformity.

**Summary:**

There is an overall valgus knee deformity of 11°, with 3° of the 11° coming from the deformity at the femur, and 8° of the 11° coming from deformity at the proximal tibia; 7° of this 8° is from the tibial shaft angulation of 10°.



**Example 10C**



## UNIT 7

# ONLINE INTERACTIVE PRACTICE

The interactive problems provided here are intended to be used as learning tools. Improved accuracy in measuring axial deformities of the knee comes from constant practice only. Therefore, this interactive section is designed in such a way as to encourage and reinforce learning by repetition while taking different learning styles into account. These problems do not comprise a test; instead, they offer a dynamic way to use instructional tools that are specifically designed to aid each user in achieving mastery of this topic at a comfortable pace. Completing these problems successfully will help contribute toward addressing the challenge of measuring axial deformities of the knee.

To access the Interactive Practice, please enter the URL shown below into your internet browser.  
<http://www.homerstrykercenter.com/publications/axialdeformity/>

## REFERENCES

1. Krackow KA. *The Technique of Total Knee Arthroplasty*. St. Louis; C.V. Mosby Company; 1990.
2. Moreland JR, Bassett LW, Hanker GJ. Radiographic analysis of the axial alignment of the lower extremity. *J Bone Joint Surg (Am)* 1987;69-A:745-49.
3. Yoshioka Y, Siu D, Cooke DV. The anatomy and functional axes of the femur. *J Bone Joint Surg (Am)* 1987;69-A:7873-80.
4. Chao EY, Neluheni EV, Hsu RW, Paley D. Biomechanics of alignment. *Orthop Clin N Am* 1994;25:379-86.

