


# Laser-Assisted Sialolithotripsy: A Correlation of Objective and Subjective Outcomes

Varun Rai, DNB(ENT) ; Rohan R Walvekar, MD; Jatin Verma, MS (ENT); Uday Monga, MS (ENT);  
Devinder Rai, MS (ENT); Manish Munjal, MS (ENT)

**Objective:** To analyze the long-term symptomatic results of laser-assisted sialolithotripsy (LAS) in cases of obstructive sialolithiasis and correlate with objective criteria using diagnostic sialendoscopy (DS) as a method of examination.

**Methods:** This is a retrospective study comprising 50 consecutive patients who underwent holmium-YAG LAS and completed follow-up of at least 6 months. Symptom scoring and endoscopic scoring were done at 6 weeks and 6 months intervals for further study purposes.

**Results:** At the end of 6 weeks post-LAS, 70% patients were asymptomatic (A-sym) and only 30% had residual symptoms (Sym). However, obstructed duct (OB-duct) was observed on endoscopic scoring in 88% due to stenosis, residual stones, or both stenosis and residual stones. The obstructed ducts were treated in outpatient clinic and followed up over time, leading to 98% of patients being in A-sym group at the end of study period of 6 months. At the end of study, 82% of patients had clear duct (CL-duct).

**Conclusion:** Holmium LAS is a viable option for the management of intermediate-sized stones. LAS if used judiciously, and in properly selected cases, has high rate of stone fragmentation and symptom resolution. A vigilant postoperative protocol taking into account residual mealtime symptoms and altered salivary characteristics combined with early DS can help identify and treat patients with residual stone fragments and ductal stenosis.

**Key Words:** laser lithotripsy, sialendoscopy, salivary stones, salivary duct stenosis, sialolithiasis, lithotripsy, chronic sialadenitis, sialadenitis.

**Level of Evidence:** 3

*Laryngoscope*, 00:1–6, 2022

## INTRODUCTION

Obstructive sialadenitis is the most common condition affecting the salivary gland, with an incidence of almost 50% in benign salivary gland disorders.<sup>1</sup> Sialolithiasis forms about two-thirds of the cases of obstructive sialadenitis. The management of salivary stones has undergone a paradigm shift in the past decade from a predominantly open approach to one that promotes gland and duct preservation, with a combination of sialendoscopy with external or intraoral techniques (combined or hybrid approaches).<sup>2</sup> Sialendoscopy is the preferred treatment of choice for small (<4 mm) accessible and floating stones located in the proximal two-thirds of the salivary duct.<sup>3</sup> For hilar and intra-glandular stones (>7 mm) that are either only partially visible, making any form of intra-ductal intervention less desirable, or are

clinically palpable, combined techniques are preferred.<sup>4</sup> Stones that are not clinically palpable and intermediate-sized (4–7 mm) and are located in the hilar regions of the gland pose a particular problem. These “intermediate-sized” stones are too large for endoscopic removal and too small to palpate, making traditional endoscopic or combined approach techniques challenging and less likely to be successful; it is in these scenarios that intra-ductal lithotripsy can be an attractive option.

Intraductal LASER-assisted sialolithotripsy (LAS) for the salivary gland can be traced to 1990, when Gundlach et al reported the application of a laser beam for the fragmentation of salivary stones.<sup>5</sup> A systemic review by YO-IFOS head and neck study group found that, while LAS is associated with a high success rate of stone fragmentation, the symptom resolution rate associated with LAS is relatively low.<sup>6</sup> These observations have led to debates regarding the efficacy of intra-ductal lithotripsy among experts; one such hypothesis is that the low symptom resolution rate associated with LAS may be related to LAS-associated intraductal stenosis, caused in turn by ductal injury due to direct or dissipated laser energy and prolonged operative times associated with LAS.<sup>7–9</sup>

However, the data to support this school of thought, in terms of objective evidence, are lacking. Our study aims to present our results of endoscopic LAS and evaluate intra-luminal effects of LAS by objective post-treatment diagnostic sialendoscopy (DS) in an effort to

From the Department of ENT (V.R., J.V., U.M., D.R., M.M.), Sir Ganga Ram Hospital, New Delhi, India; Otolaryngology & Head Neck Surgery (R.R.W.), LSUHSC, New Orleans, Louisiana, USA.

Additional supporting information may be found in the online version of this article.

Editor's Note: This Manuscript was accepted for publication on February 26, 2022.

The authors have no funding, financial relationships, or conflicts of interest to disclose.

Send correspondence to: Varun Rai, DNB(ENT), Department of ENT, Sir Ganga Ram Hospital, H 465, New Rajinder Nagar, New Delhi, India 110060.

Email: varun.rai2001@gmail.com

DOI: 10.1002/lary.30106

help formulate recommendations for LAS based on objective evidence and data.

## MATERIALS AND METHODS

Our study was a retrospective study of 50 consecutive patients undergoing LAS at Department of Otolaryngology, Sir Ganga Ram Hospital, New Delhi, a tertiary health care facility from December 2017 to December 2019. All procedures were performed by a single surgeon (VR). All patients with symptoms of obstructive sialadenitis had a thorough clinical examination with emphasis on mealtime symptoms, examination of the papilla in terms of location, patency, characterization of the expressed saliva, and a floor mouth examination with bimanual palpation of the gland to localize the sialolith.

A non-contrasted computerized tomography (CT) scan was obtained for all patients, as is the protocol at our center when planning intervention for sialolithiasis. The CT scan was then analyzed for characteristics of sialolith, namely the number, location, size (maximum sagittal diameter), and orientation.

All the primary interventional sialendoscopy procedures were performed under general anesthesia with an informed consent for LAS. The consent also discussed the possibility of staged procedures as well as the need for check diagnostic sialendoscopy (DS) in the postoperative follow-up period of at least 6 months.

### Procedure Details

Standard aseptic precautions were taken for an oral cavity case. A Doyen's retractor was used for exposure and throat was packed in every case. The papilla was identified using an operating microscope, (Carl Zeiss OPMI Visu 200 S8 Surgical Microscope) along with expression of saliva with gland massage. Serial dilation was performed in a standard fashion with Marchal dilators (Karl Storz Endoscopy, Tuttlingen, Germany) and a 1.3 mm all-in-one sialendoscope was used for all the procedures (Karl Storz Endoscopy, Tuttlingen, Germany).

Intraductal LAS was performed using the Lumenis VersaPulse Powersuite 100 W Holmium Laser (Lumenis Ltd.) with a 230 nm laser fiber. Laser settings used were 5 Hz and 0.6 Joule

of energy. Stone fragmentation carried out till individual particles were less than 2 mm, which were then extracted using a basket or expressed via papilla and gland massage (Fig. 1). At the end of the procedure, a solution consisting of a combination of 5 ml metronidazole (500 mg/100 ml) and 2 ml dexamethasone (4 mg/ml) was instilled into the duct using a size 24 French Gauge Cannula through the papilla. The duct was then stented with a 4Fr diameter, 6 cm length pre-made stent (Intermedics Ltd. India) and secured to oral cavity using 4-0 round-bodied silk sutures. Stent placement was maintained for a period of 4 weeks and any displaced stents were replaced in outpatient clinic. Post-operative advice following procedure consisted of 7-day course of amoxicillin and clavulanic acid combination, nonsteroidal anti-inflammatory drugs, and a soft diet.

The study included 50 consecutive patients who underwent LAS and completed monthly examinations in the outpatient clinic for a minimum period of 6 months. The follow-up protocol included monthly symptom scoring questionnaires and office-based DS. All patients included in the study underwent DS at 6 weeks and 6 months post-surgery.

The rationale of DS at 6-week duration was that the post-operative edema would have settled down, and adequate time would have been given to allow the duct to heal, leading to an accurate assessment of the salivary duct lumen. For study purposes, the symptom scoring and DS findings at the periods of 6 weeks and 6 months were entered into records for further evaluation. Due to the inherent nature of LAS wherein there is potential thermal injury to the duct leading to late-stage stenosis, as well as repulsion of minute stone fragments leading to incomplete stone clearance in the primary setting, all patients regardless of their symptom scores were subjected to DS to objectively confirm the duct patency and stone free status.

In our center, it is standard practice to objectively follow all LAS cases with scheduled DS at 6 weeks and 6 months intervals to maintain a high degree of success rate.

The symptom scoring was done according to a four-point forced Likert scale for each individual complaint of pain of affected gland, swelling associated with gland, and altered salivary characteristics (Table I). For purposes of the study, symptom score of 2 and above were classified as being "Symptomatic (Sym)," regardless of degree. Consequently, for the purpose of

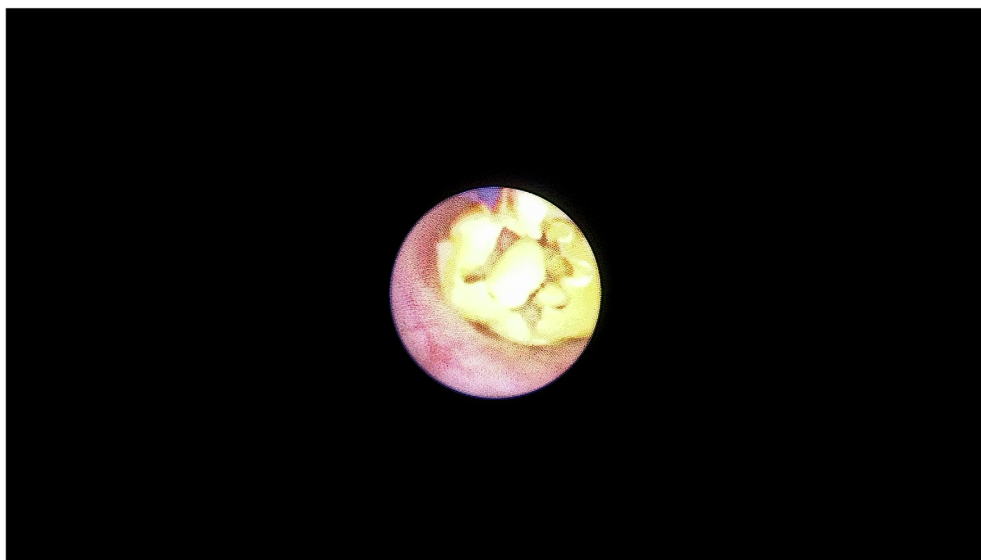


Fig. 1. Depicting the Sialendoscopic View of LAS in Progress with the Stone Partially Fragmented and Laser Tip in Contact with the Stone. [Color figure can be viewed in the online issue, which is available at [www.laryngoscope.com](http://www.laryngoscope.com).]

TABLE I.  
This is the Symptom-Based Scoring Questionnaires Sent to Patients for Monthly Follow-Ups.

Symptom	Likert Scoring			
	1	2	3	4
Pain	No pain	Mild intermittent	Severe intermittent	Severe constant
Swelling	No swelling	Mealtime gland tightness (Not observable)	Visible mealtime gland swelling	Constant gland swelling
Salivary flow	Clear saliva	Intermittent mealtime yellow/thick saliva	Constant thick/yellowish saliva	No saliva

The score was calculated according to four-point forced Likert scales. Any score of 2 or above was classified as significant and patients grouped in "Sym" group.

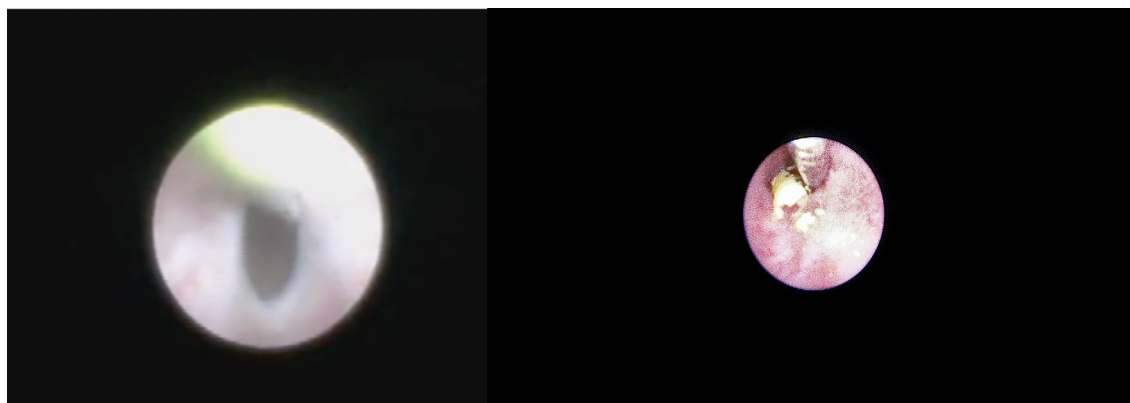

Fig. 2. Postoperative Check Endoscopy (DS) Showing. Left: Stenosis; Right: Residual Stone Fragments. [Color figure can be viewed in the online issue, which is available at [www.laryngoscope.com](http://www.laryngoscope.com).]

analysis, patients were categorized as being either "asymptomatic (A-sym)" or "symptomatic (Sym)" during the evaluation period.

The findings of DS were recorded and endoscopic findings were utilized to categorize the ducts as being clear (CL-duct) or obstructed (OB-duct). The obstructed ducts were further classified as having a stenosis, residual stone fragments, or both. During the DS of patients with OB-duct, a clinic-based therapeutic intervention was performed according to established protocols of sialendoscopic management of strictures and residual stone fragments (Fig. 2). All the OB-duct with residual stone fragments were basketed out under 1.3 mm all-in-one sialendoscopic vision, and no further stenting was done. All stenosed ducts were dilated using serial endoscopes to a minimum diameter of 1.6 mm, which is the minimum recommended diameter for adequate salivary flow. The degree and character of stenosis found on DS were classified according to standard scoring system given by Koch et al.<sup>19</sup> These ducts were further stented after dilatation for an additional period of 2 weeks. Only the patients who had OB-duct at 6-week interval and were subjected to dilatation for stenosis, and subsequent stenting underwent a second DS at 4-week post-secondary intervention, and then again at 6-month interval. The patients with CL-duct and those who did not require stenting/dilatation during primary DS were only checked at the end of the study period of 6 months.

All scoring was done by a primary surgeon (VR) and corroborated by our team (JV, and UM), and the data were entered into records for analysis.

Qualitative variables were assessed using Fisher's exact test. McNemar test was used to follow the movement of qualitative variables across follow-up treatments. Sensitivity, specificity, PPV, NPV, and accuracy were also computed. A *p* value

TABLE II.  
This Table Shows the Demographics of Patients Grouped According to Initial Size of Stone Measured on CT Scan with Diameter Taken as Maximum Sagittal Diameter.

Sitting → Calculus Size (mm)	One		Two		<i>p</i> Value
	n	%	N	%	
<4	7	16.67%	0	0.00%	0.107
4–7	32	76.19%	3	37.50%	0.014
>7	3	7.14%	5	62.50%	<0.001
TOTAL	42	100%	8	100%	

This also depicts the correlation between initial size of stone and number of sittings required to achieve stone free duct.

<0.05 is considered statistically significant. The data were stored securely in MS Excel spreadsheet and statistical analysis was performed using an open source "R" programming language.

## RESULTS

In our study, 66% (n = 33) were male, and 34% (n = 17) were female. The stones were located in submandibular gland in 86% (n = 43) and in parotid gland in 14% (n = 7). Stone size ranged from 3.2 mm to 8.9 mm, with a mean size of 5.56 mm (SD+/- 1.35). Fourteen percent (n = 7) of patients had stone size less than 4 mm, 70% (n = 35) with sizes between 4 and 7 mm, and 16% (n = 8) patients with stone size greater than 7 mm. Single

TABLE III.

This Table Shows the Correlation Between Symptom Scoring and Endoscopic Scoring at 6 Weeks and 6 Months Study Intervals.

Symptom Scoring	Endoscopic Scoring—Abnormal Duct	Endoscopic Scoring—Normal Duct	<i>p</i> Value	Sensitivity	PPV	Accuracy
Asymptomatic 6 weeks	29	6				
Symptomatic 6 weeks	15	0	0.102	65.91%	82.86%	58%
Asymptomatic 6 months	8	41				
Symptomatic 6 months	1	0	0.18	88.89%	16.33%	16%

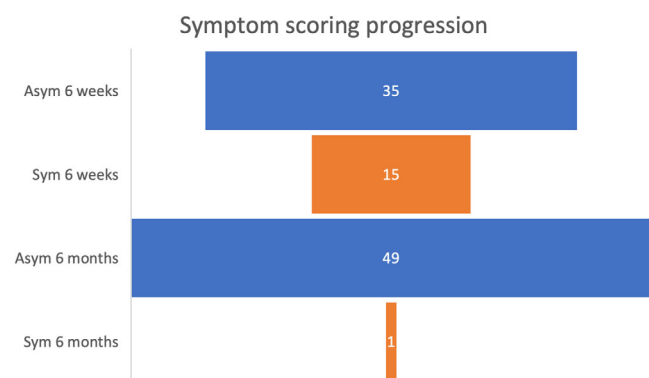


Fig. 3. This Figure Depicts the Symptom Progression Among Patients During the Period of Study. Legend: Asym: Asymptomatic Patients (Likert Score of 1 on Symptom Scoring Questionnaires). Sym: Symptomatic Patients (with Likert Score 2 and Above). [Color figure can be viewed in the online issue, which is available at [www.laryngoscope.com](http://www.laryngoscope.com).]

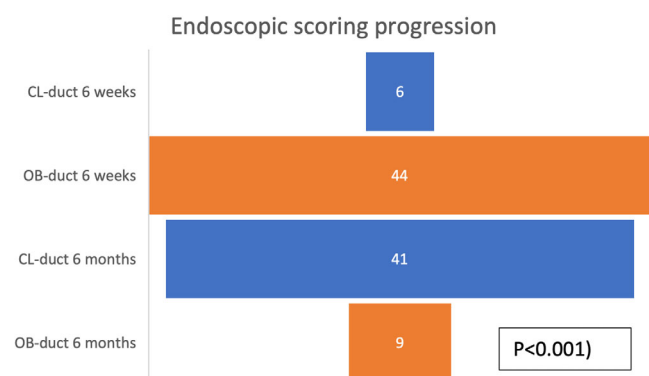


Fig. 4. This Figure Depicts the Endoscopic Scoring Progression Among Patients During. CL-Duct: Salivary Duct Without Obstructions in the Form of Stenosis or Residual Stones. OB-Duct: Obstructed Duct with Stenosis, Stones or a Combination of Residual Stones and Stenosis. [Color figure can be viewed in the online issue, which is available at [www.laryngoscope.com](http://www.laryngoscope.com).]

intervention with LAS was necessary in 84% ( $n = 42$ ) of the patients and multiple interventions were required in 16% ( $n = 8$ ), as shown in Table II. In patients who required more than one intervention, 62.5% ( $n = 5$ ) had stone size greater than 7 mm ( $p < 0.001$ ).

At the 6-week postoperative evaluation, symptom scoring based on questionnaires, 70% ( $n = 35$ ) of the patients were in A-sym group, and 30% ( $n = 15$ ) were in

Sym group. On endoscopic examination of the duct, 88% ( $n = 44$ ) had an OB-duct and only 12% ( $n = 6$ ) had a CL-duct. OB-duct duct was seen in all patients who were classified in the Sym group ( $n = 15$ , sensitivity = 100%, PPV = 82.86%) and 82.85% of the patients who were classified in A-sym group (sensitivity = 65.91%, PPV = 82.86%) (Table III). When taking the initial size of stone into consideration, sensitivity and PPV were higher for stone size above 7 mm, however this was not statistically significant.

At the 6-month postoperative period, 98% ( $n = 49$ ) of the patients were in A-sym group and only one patient (2%) was in Sym group with persistent residual mealtime symptoms. Endoscopic scoring showed CL-duct in 82% ( $n = 41$ ) and OB-duct in 18% ( $n = 9$ ) of the patients. The symptomatic individual had an OB-duct, which was due to a tight stricture at the laser site. Among the patients in A-sym group, 83.66% ( $n = 41$ ) had a CL-duct and 16.32% ( $n = 8$ ) had an OB-duct (sensitivity = 88.89%, PPV = 16.33%,  $p = 0.18$ ), (Table III). Again, when taking the initial size of stone into consideration, sensitivity and PPV were higher for stone size above 7 mm, which was statistically not significant.

On linear progression of groups along the timeline, all patients in the Sym group recovered completely at the end of 6 months ( $n = 15$ ,  $p < 0.001$ ). Only one of the patients initially in the A-sym group developed symptoms in the postoperative period and remained symptomatic at the end of the study period (Fig. 3).

On objective evaluation of the duct system with postoperative DS at 6 months, in 80% ( $n = 35$ ) of patients, endoscopic changes after LAS resolved and with findings that could be categorized as being clear, while only 9 (20%) patients had findings suggesting persistent obstruction on DS ( $p < 0.001$ ). All the patients with a clear finding at DS at the 6-week interval remained clear throughout the period of the study (Fig. 4).

## DISCUSSION

Direct sialendoscopic intervention with baskets/forceps extraction of calculi is usually possible for small, free-floating stones (1.5–3 mm), without proximal stenosis. Walvekar et al. described that stone shape and orientation within the calculi can be predictors of successful stone removal with direct extraction.<sup>11</sup> For larger calculi or those that are stuck behind a narrowing of the duct, the options of intervention include combined approach or intra-ductal stone fragmentation. Combined approach is

preferable and more predictable in cases where the calculi is clinically palpable within the oral cavity or can be localized using ultrasound, that is, either sono-palpation or ultrasound-guided needle localization for submandibular and parotid stones, respectively.<sup>12</sup> For stones that are not clinically palpable, more proximal in location (hilar or intra-glandular) or may have a treatable focal stenosis that is preventing endoscopic stone extraction, endoscopic stone fragmentation is an attractive alternative to facilitate stone removal and gland preservation. Specifically, endoscopic laser fragmentation using pulsed excimer laser was first described in the 1990s by Gundlach et al., and since then many reports of LAS have been published. Despite the paucity on reports regarding the ideal laser for LAS, the preferred one by most authors is the holmium-YAG laser due to safety afforded by high water absorbent coefficient ( $3 \text{ mm}^{-1}$ )<sup>13</sup> ready availability in most centers, and relative cost-effectiveness. The holmium-YAG laser is also the preferred system for disintegration of calculi regardless of the calculi's physical and radiological characteristics.<sup>14</sup>

In the literature, the success rate of fragmentation of salivary calculi ranges from 40% to 100%.<sup>15–22</sup> The wide range is probably due to unfavorable duct anatomy, and lie of the calculi within branches of duct. For this reason, Marchal and Dulgerov recommend that LAS should be limited to calculi within main duct and when stone is visible completely within the ductal system (stage L2).<sup>23</sup> In our study, as per recommendations, we have included calculi that were in the same stage (L2) to eliminate bias when recording rates of postoperative stenosis and residual stone fragments after LAS.

As noted previously, the discrepancy in symptom relief after successful LAS has been speculated to result from post-treatment ductal stenosis and/or residual stone fragments; resulting from laser-induced thermal damage to the salivary duct lumen, prolonged operative times and repeated entry and re-entry of the scope to remove stone fragments, and non-recoverable stone fragments, respectively. However, to date, there have been no objective studies documenting the endoscopic state of the duct that have correlated these findings to patient symptoms.

Our LAS fragmentation rates were 100%. Although this attests to the efficacy and prior literature evidence that LAS is associated with high fragmentation rates, our results could be influenced by the retrospective nature of our data and by selection bias, given that our criteria for LAS were stones favorable for such an intervention, (Stage L2). Most of the cases required single fragmentation sitting, however, multiple sittings of fragmentation were employed when the primary procedure had to be staged due to either development of oral mucosa edema or due to signs of impending ductal damage (whitening of duct/ thinning of duct/ductal edema). In our study, multiple interventions were necessary in 16% of patients, and this had a statistically significant correlation with the initial size of the stone, with 62.5% of the cases having sizes greater than 7 mm. This need for multiple interventions to manage these larger stones with LAS can also be explained by longer fragmentation process, prolonged laser exposure, and increased need of irrigation.

Consequently, the authors caution the use of LAS for stones greater than 7 mm and recommend close re-evaluation of ductal integrity during long LAS procedures as well as keeping a close watch for cheek swelling or floor mouth swelling that could occur due to ductal tears and dissemination of irrigation fluid.

Seventy percent of patients reported complete symptomatic relief at the end of 6 weeks. As compared with worldwide literature, our results were lower as pertains to symptom resolution. However, this may be due to the fact that, in addition to post-prandial symptoms, we also considered altered salivary characteristics as being indicative of persistent symptoms.

In our opinion, altered salivary characteristics could be one of the earliest signs of impending duct obstruction and consequently should be recorded within the symptom profile. From a statistical perspective, eliminating this factor improved our symptom relief rate to 86%, which is comparable to other studies.

DS findings of the ducts showed an obstruction in the ducts of all symptomatic subjects, which was expected, and also reflected on the studies that performed an objective evaluation of DS/USG postoperatively. The DS scores of asymptomatic patients also revealed obstructions. At the study period of 6 weeks, 82.85% of asymptomatic patients had obstructed duct on DS, which primarily consisted of early stenosis or residual stone fragments. In our opinion, these early stenosis and/or residual stone fragments were unlikely to cause significant symptomatic obstruction. In our study, these early stenoses and residual stone fragments were corrected with DS, according to established protocols for floating stones and sialendoscopic management of strictures.<sup>23</sup> As mentioned previously, these patients who underwent ductal intervention during DS were also stented for an additional period of 2 weeks.

At the end of the study period of 6 months, all but one patient was completely asymptomatic. The only patient who was symptomatic was found to have a very tight stricture at the laser fragmentation site, which had to be re-dilated and stented under general anesthesia. Among the asymptomatic patients, DS showed abnormalities in 16.32% and was normal in 83.66%. When the period of study was extended, symptom scoring became more sensitive when predicting the status of the duct, however this was not statistically evaluated. The initial size of stone did have a positive correlation with the outcome of intervention as regards symptomatic relief as well as DS scores, however this was not statistically significant.

We also observed a positive trend as regards to symptom scoring and endoscopic scoring over time, which was statistically significant. We attribute this to early diagnosis of offending obstructions and subsequent management during the DS. In our opinion, the early stenosis noted during initial DS, if left untreated, could progress to fibrous stenosis, thus leading to poor symptom relief. Similarly, residual stone fragments could act as nidus for further stone formation and hence present as recurrent stones at a later date.

Endoscopic evaluation of a duct after LAS gives the surgeon the opportunity to identify and remove residual

stone fragments and stenosis. In our opinion, diligent care of the post-LAS duct is a valuable consideration to prevent late-stage stenosis and recurrent stone formation, which ultimately improves the long-term results of LAS and consequently patient outcomes.

## CONCLUSIONS

LAS is a viable option for the management of intermediate-sized stones. LAS if used judiciously, and in properly selected cases, has high rate of stone fragmentation and symptom resolution. A vigilant postoperative protocol considering residual mealtime symptoms and altered salivary characteristics combined with early DS can help identify and treat residual stone fragments and ductal stenosis.

## BIBLIOGRAPHY

1. Epker BN. Obstructive and inflammatory diseases of the major salivary glands. *Oral Surg Oral Med Oral Pathol* 1972;33:2–27.
2. Capaccio P, Torretta S, Ottavian F, Sambataro G, Pignataro L. Modern management of obstructive salivary diseases. *Acta Otorhinolaryngol Ital* 2007;27:161–172.
3. Witt RL, Iro H, Koch M, McGurk M, Nahlieli O, Zenk J. Minimally invasive options for salivary calculi. *Laryngoscope* 2012;122:1306–1311.
4. Koch M, Zenk J, Iro H. Algorithms for treatment of salivary gland obstructions. *Otolaryngol Clin N Am* 2009;42:1173–1192.
5. Gundlach P, Scherer H, Hopf J, et al. Endoscopic-controlled laser lithotripsy of salivary calculi. In vitro studies and initial clinical use [in German]. *HNO* 1990;38:247–225.
6. Chiesa-Estomba CM, Saga-Gutierrez C, Calvo-Henriquez C, Lechien JR, Cartier C, Mayo-Yanez M, Larruscain-Sarasola E, Ayad T, Walvekar RR. Laser-assisted lithotripsy with sialendoscopy: systematic review of YO-IFOS head and neck study group. *Ear Nose Throat J* 2021;100:42S–50S. <https://doi.org/10.1177/0145561320926281>. Epub 2020 May 22. PMID: 32442031.
7. Konigsberger R, Feyh J, Goetz A, et al. Endoscopic controlled laser lithotripsy in the treatment of sialolithiasis. *Laryngorhinootologie* 1990;69:322–323.
8. Luers JC, Petry-Schmelzer JN, Hein WG, Gostian AO, Hutten-Brink KB, Beutner D. Fragmentation of salivary stones with a 980 nm diode laser. *Auris Nasus Larynx* 2014;41:76–80.
9. Sun YT, Lee KS, Hung SH, Su CH. Sialendoscopy with holmium:YAG laser treatment for multiple large sialolithiasis of the Wharton duct: a case report and literature review. *J Oral Maxillofac Surg* 2014;72:2491–2496.
10. Koch M, Iro H. Salivary duct stenosis: diagnosis and treatment. *Acta Otorhinolaryngol Ital* 2017;37:132–141. <https://doi.org/10.14639/0392-100X-1603>.
11. Walvekar RR, Carrau RL, Schiatkin B. Endoscopic sialolith removal: orientation and shape as predictors of success. *Am J Otolaryngol* 2009;30:153–156.
12. Marchal F, Dulguerov P. Sialolithiasis management: the state of the art. *Arch Otolaryngol* 2003;129:951–956.
13. Van Leeuwen TG, van der Veen MJ, Verdaasdonk RM, Borst C. Tissue ablation by holmium-YSGG laser pulses through saline and blood. *SPIE Laser-Tissue Interaction* 1991;II:214–219.
14. Schrötzlmair F, Müller M, Pongratz T, et al. Laser lithotripsy of salivary stones: correlation with physical and radiological parameters. *Lasers Surg Med* 2015;47:342–349.
15. Ito H, Baba S. Pulsed dye laser lithotripsy of submandibular gland salivary calculus. *J Laryngol Otol* 1996;110:942–946.
16. Raif J, Vardi M, Nahlieli O, Gannot I. An Er:YAG laser endoscopic fiber delivery system for lithotripsy of salivary stones. *Lasers Surg Med* 2006;38:580–587.
17. Durbec M, Dinkel E, Vigier S, Disant F, Marchal F, Faure F. Thulium-YAG laser sialendoscopy for parotid and submandibular sialolithiasis. *Lasers Surg Med* 2012;44:783–786.
18. Martellucci S, Pagliuca G, de Vincentiis M, et al. Ho:Yag laser for sialolithiasis of Wharton's duct. *Otolaryngol Head Neck Surg* 2013;148:770–774.
19. Phillips J, Withrow K. Outcomes of holmium laser-assisted lithotripsy with sialendoscopy in treatment of sialolithiasis. *Otolaryngol Head Neck Surg* 2014;150:962–967.
20. Sionis S, Caria RA, Trucas M, Brennan PA, Puxeddu R. Sialoendoscopy with and without holmium:YAG laser-assisted lithotripsy in the management of obstructive sialadenitis of major salivary glands [published correction appears in Br J Oral Maxillofac. Surg 2014 Jul; 52(6):579]. *Br J Oral Maxillofac Surg* 2014;52:58–62.
21. Achim V, Light TJ, Andersen PE. Gland preservation in patients undergoing sialoendoscopy. *Otolaryngol Head Neck Surg* 2017;157:53–57.
22. Koch M, Hung SH, Su CH, Lee KS, Iro H, Mantsopoulos K. Intraductal lithotripsy in sialolithiasis with two different Ho:YAG lasers: presetting parameters, effectiveness, success rates. *Eur Rev Med Pharmacol Sci* 2019;23:5548–5557.
23. Marchal F, Chossegras C, Faure F. Salivary stones and stenosis- a comprehensive classification. *Rev Stomatol Chir Maxillofac* 2008;109:233–236.