

NUCLEAR MEDICINE & POSITRON EMISSION TOMOGRAPHY

Richard S.Kuebler,M.D.,J.D.

Clinical Assistant Professor

Academic Director of Nuclear Medicine

LSUHSC Department of Radiology

Acknowledgements for Lecture and Images

Dan Fertel,M.D.

Stephanie Casey,M.D.,M.P.H.

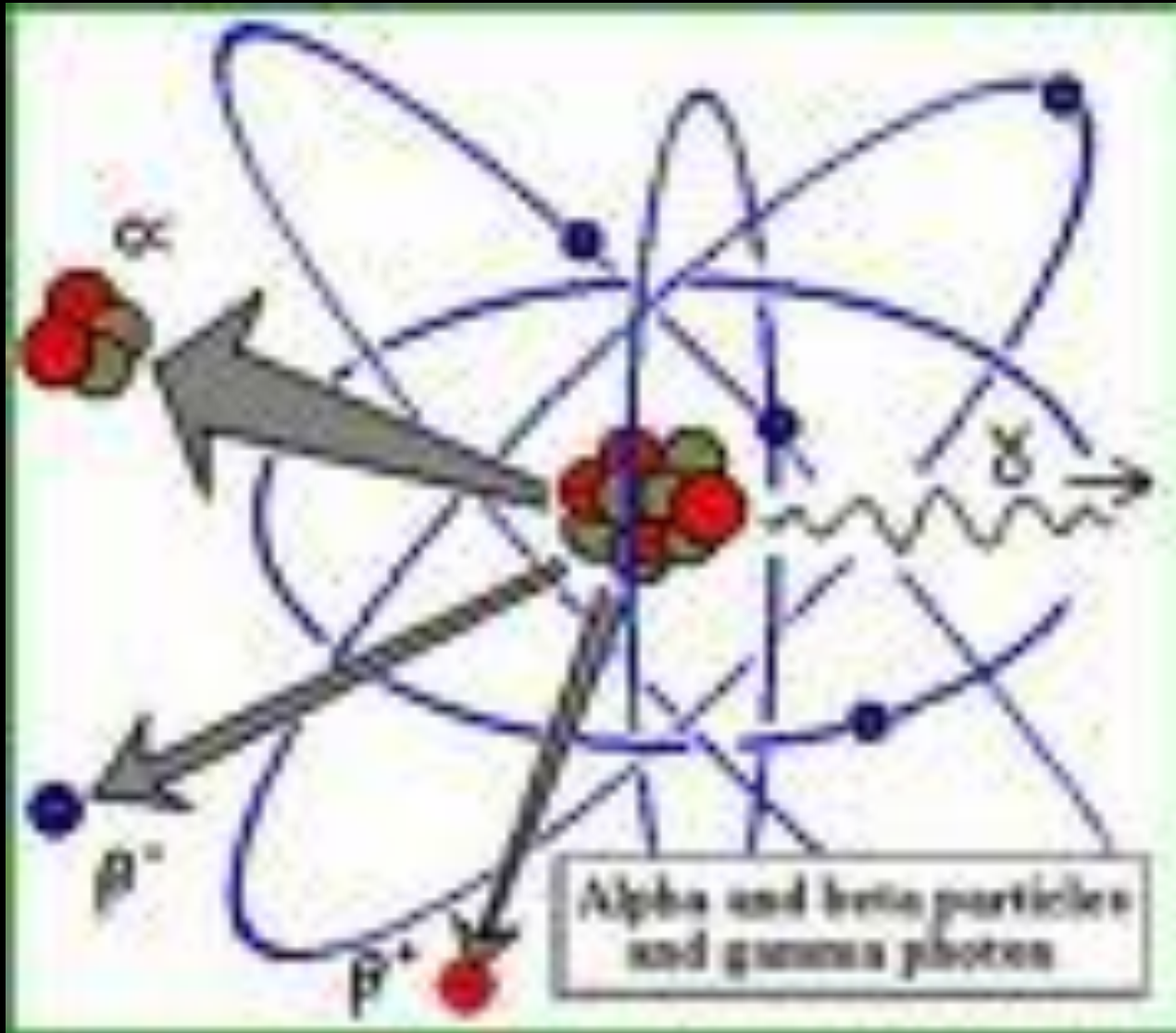


References

- Brant and Helms
Fundamentals of Diagnostic Radiology
- Mettler and Guiberteau
Essentials of Clinical Nuclear Medicine





Nuclear Medicine



- **Diagnostic**

- **Therapeutic**

Nuclear Medicine

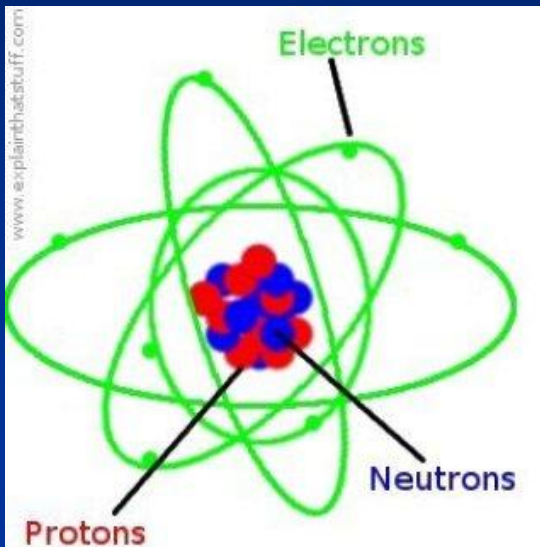
- Use of radioactive isotopes
- Most common **Technetium-99m** 
 - which has a 6 hour half life with good detector
- Others include **Iodine-123, Indium-111, Gallium-67.** 
- Gamma camera imaging
- SPECT imaging

Radionuclides= Isotopes attempting to reach stability by emitting radiation

Tc-99m

Radioactive decay

ATOM



Gamma ray/photon emission
(140KeV)

Gamma camera

Light pulse

Voltage Signal

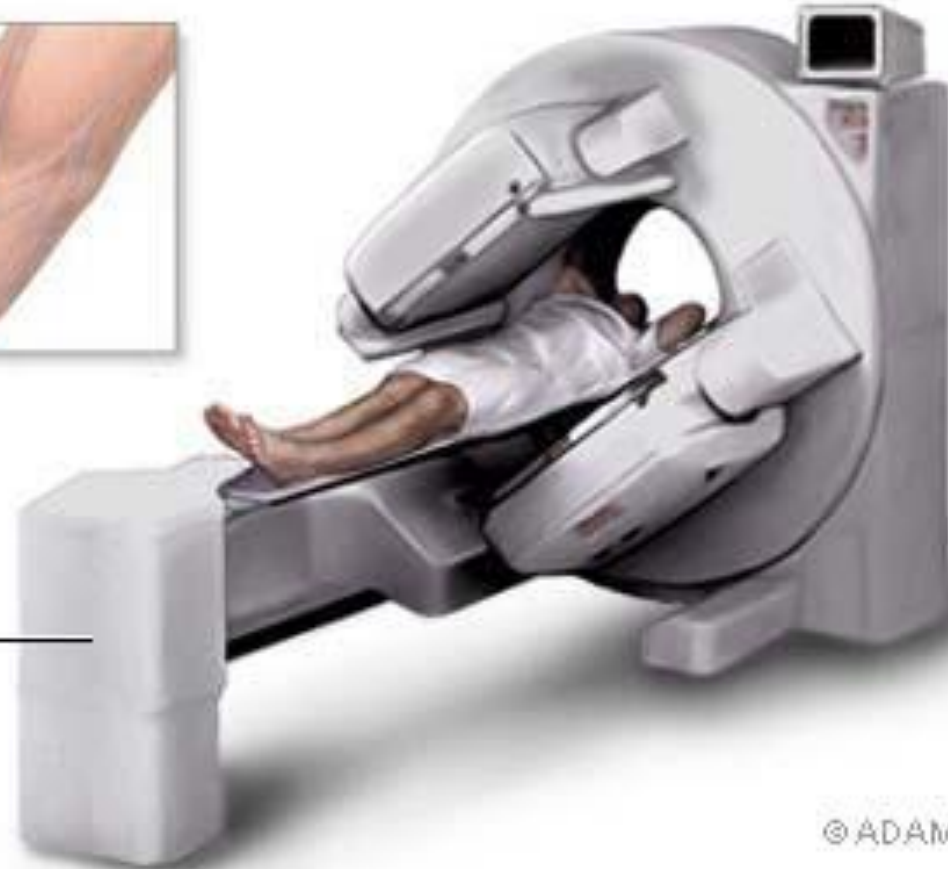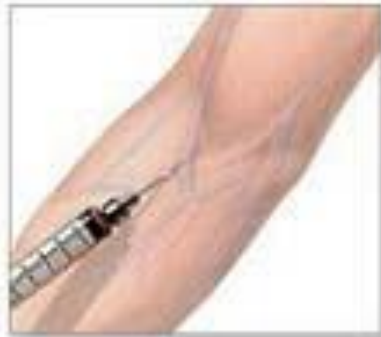Image

Gamma Camera

- A **gamma camera** is a device used to image gamma radiation emitting radioisotopes, a technique known as scintigraphy



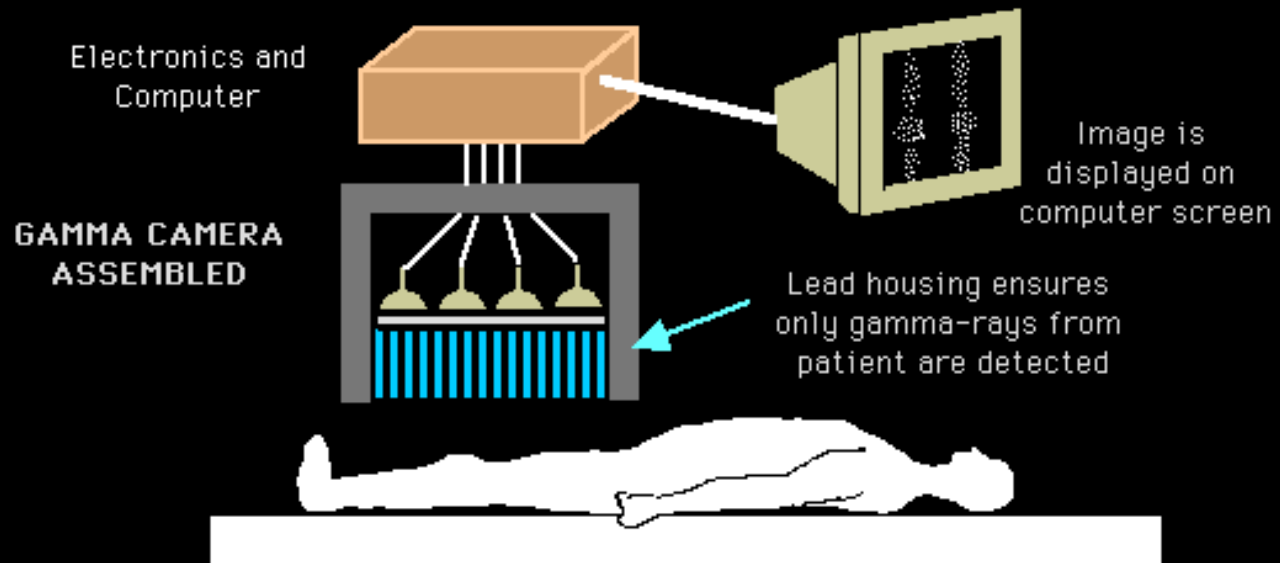
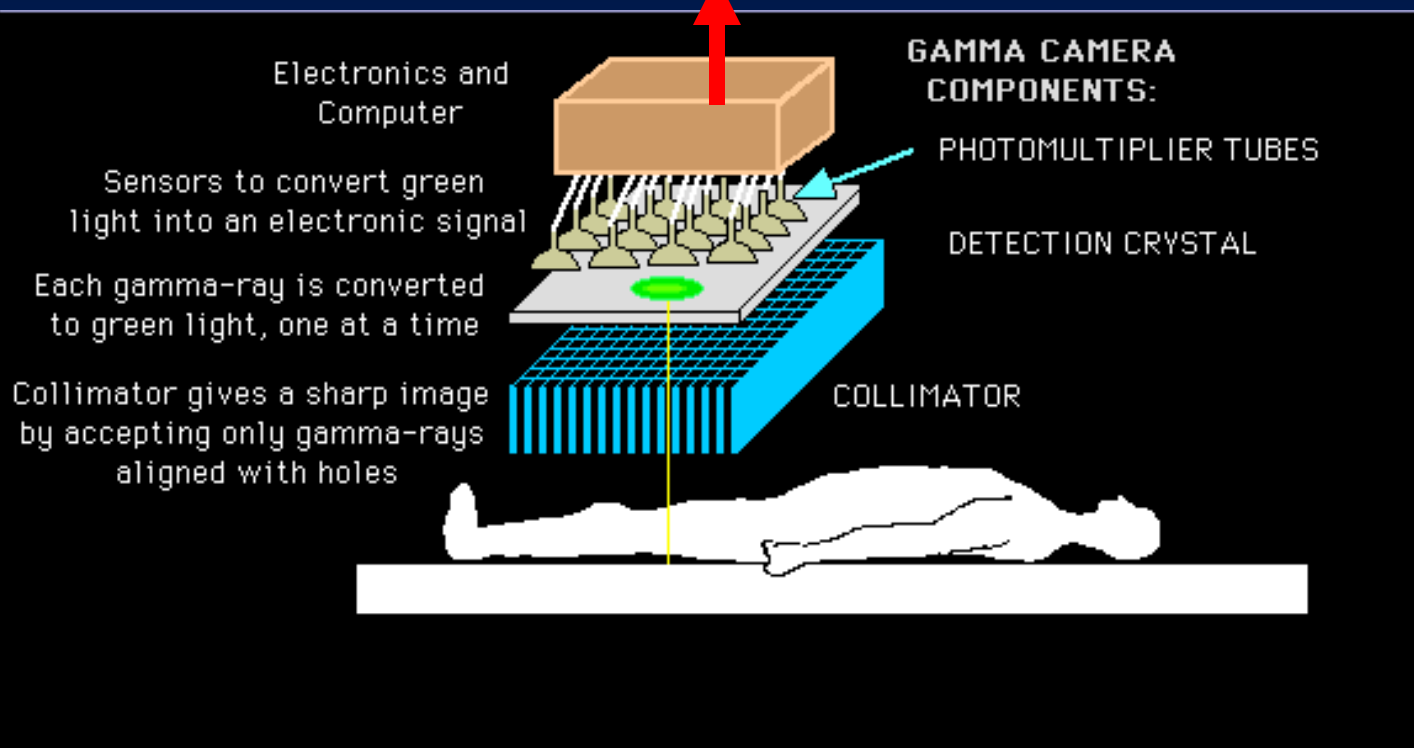
The radiotracer, injected into a vein, emits gamma radiation as it decays. A gamma camera scans the radiation area and creates an image.



Gamma camera

© ADAM, Inc.

Image on PACS



Uses of Nuclear Medicine

- **Heart:** myocardial perfusion imaging where there has been further development for improvement, rather than decrease or replacement by other modalities. Use SPECT evaluation
- **Bone scans,** evaluate for metastatic bone cancer, osteomyelitis. Most common changes we see are arthritic, correlate with other studies.

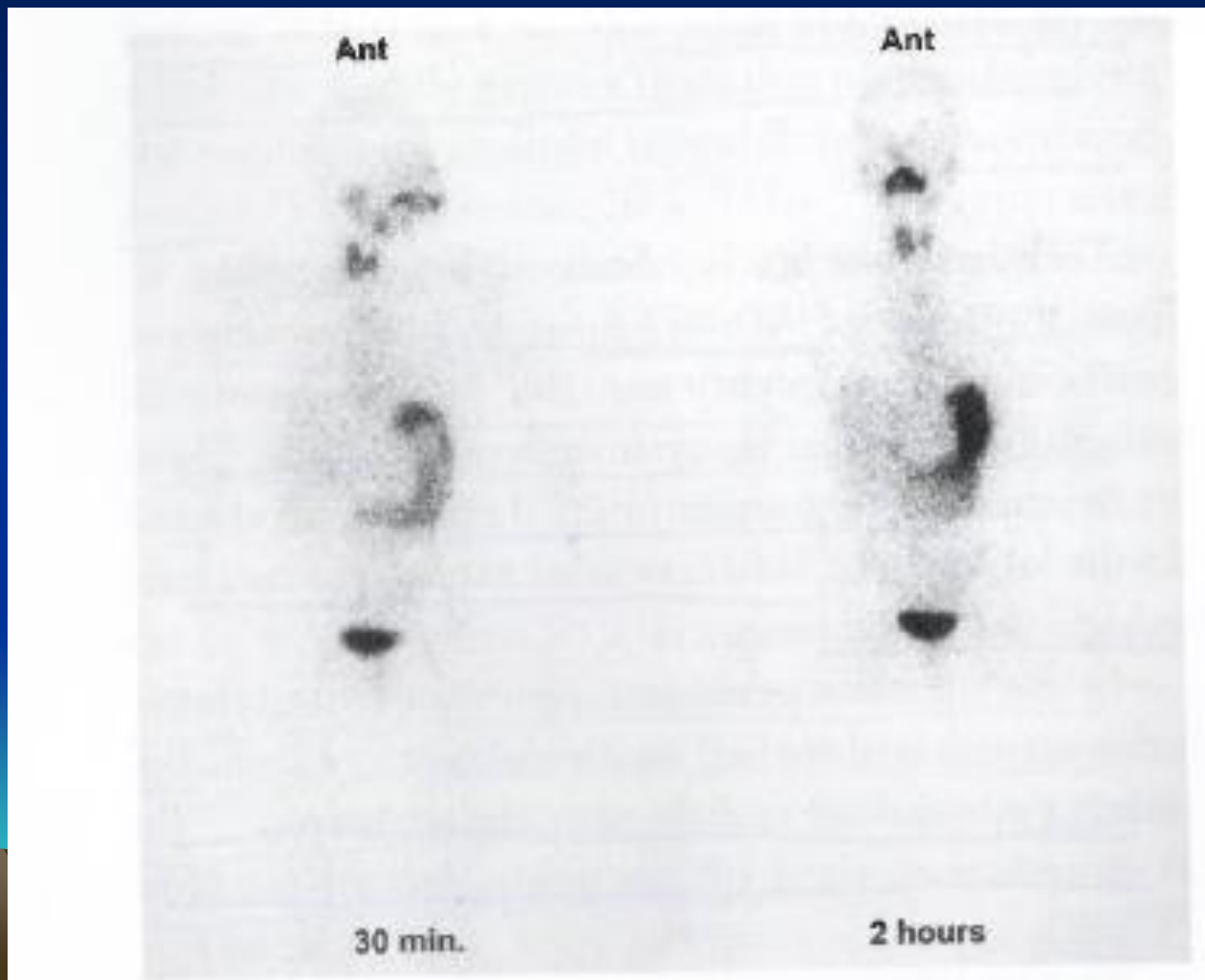


Radionuclides for Imaging

- Normal Whole-body distribution
- Route of excretion
- Target/critical organ



Normal Technetium Distribution



Cardiovascular Nuclear Imaging

1. Heart wall motion



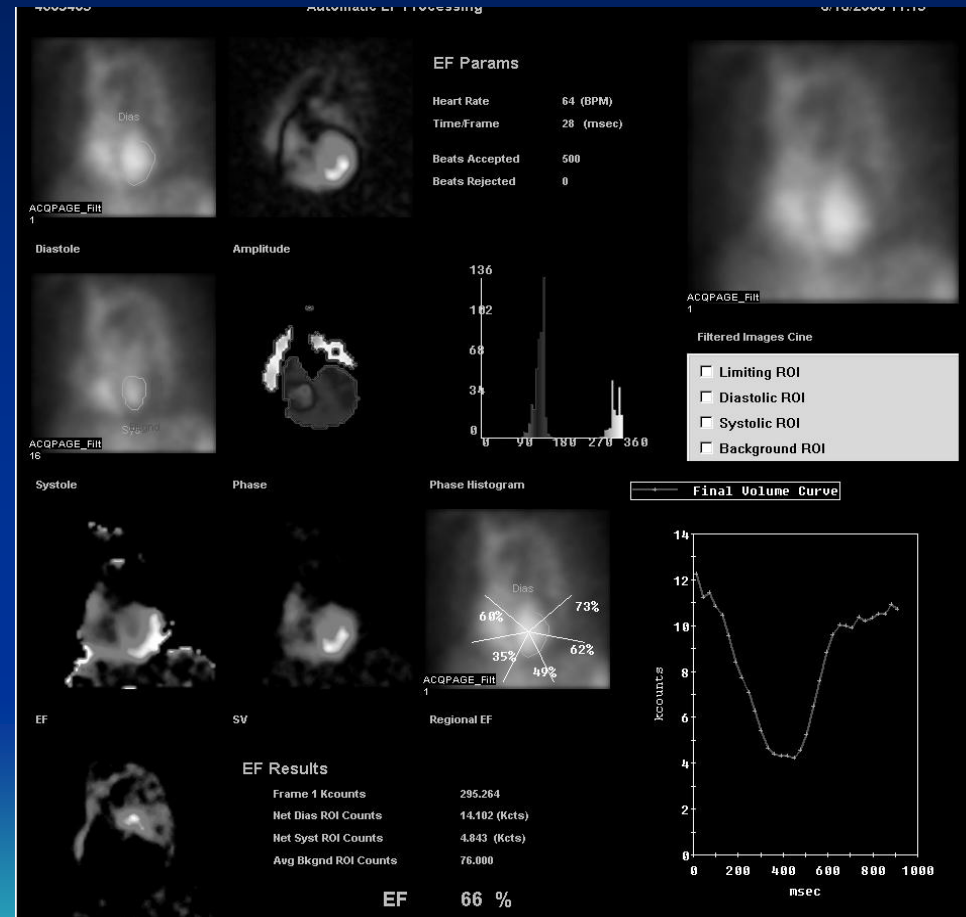
2. Myocardial Perfusion & Viability



Heart wall motion

(Regional & Global Ventricular Function)

- Tc-99m tagged red blood cells
- Evaluate left ventricular ejection fraction (nl > 50%)
- Tagged red blood cells also used for GI bleeding and hemangioma evaluation in the liver



Equilibrium Radionuclide Angiography

Gated equilibrium radionuclide angiograms (MUGA scans)

- 1. Performed with Tc-99m red blood cells**
- 2. Common indications include assessment of LVEF & regional wall motion**



Myocardial Perfusion & Viability

- Originally thallium 201
- Now use Tc99m Cardiolite or Myoview
- SPECT Imaging
- Determine adequacy of blood flow to myocardium, especially in conjunction with exercise or pharmacologic stress

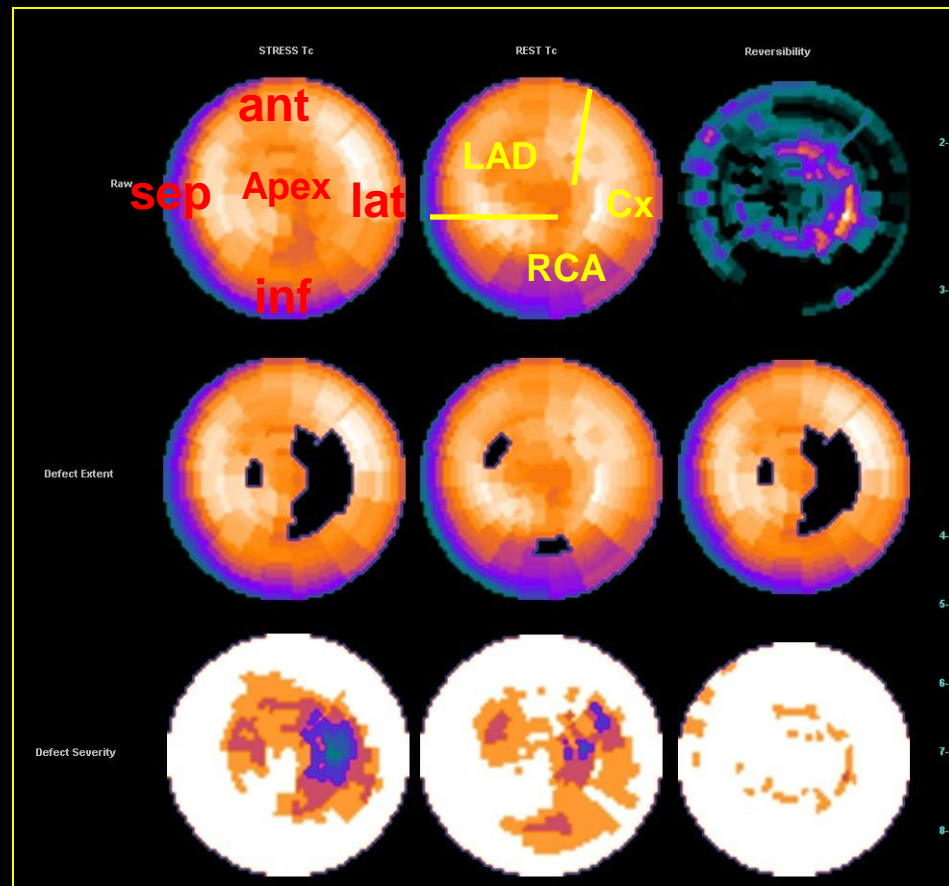
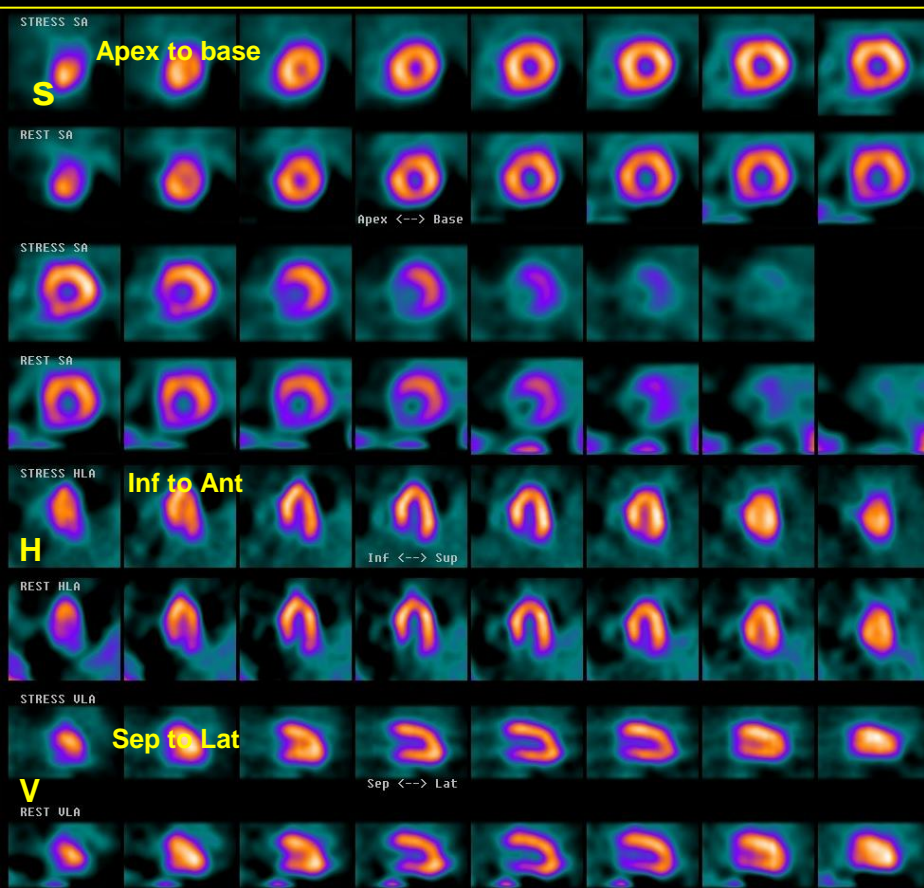


Myocardial Perfusion

- Stress/Exercise
- Increased Oxygen demand
- Dilate coronary arteries



Normal heart

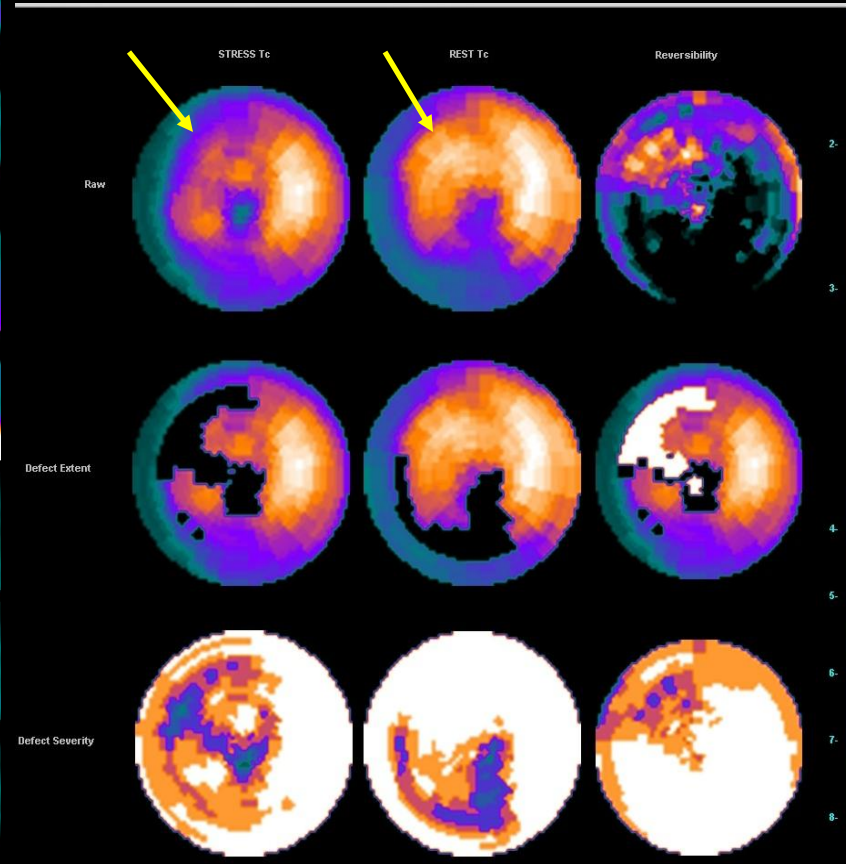
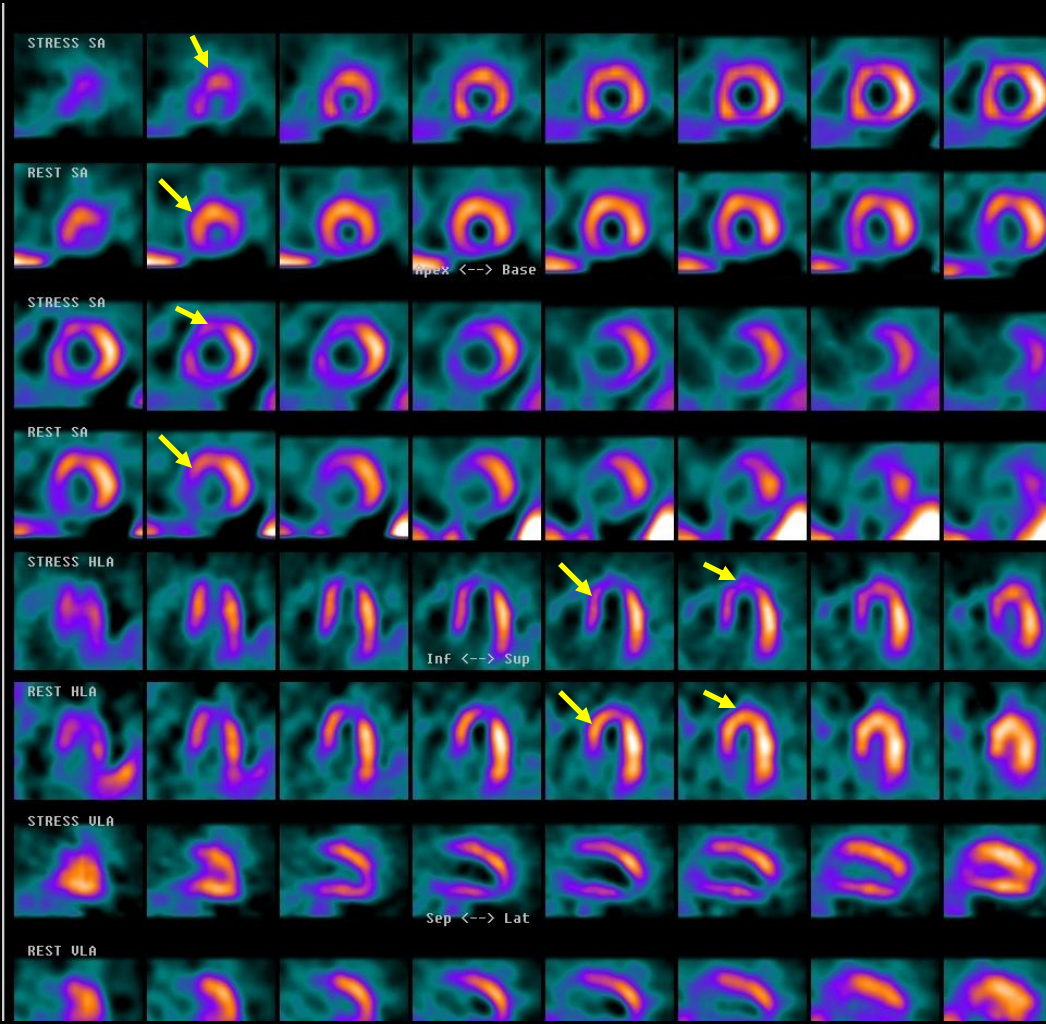


Myocardial Perfusion

Rest = baseline perfusion

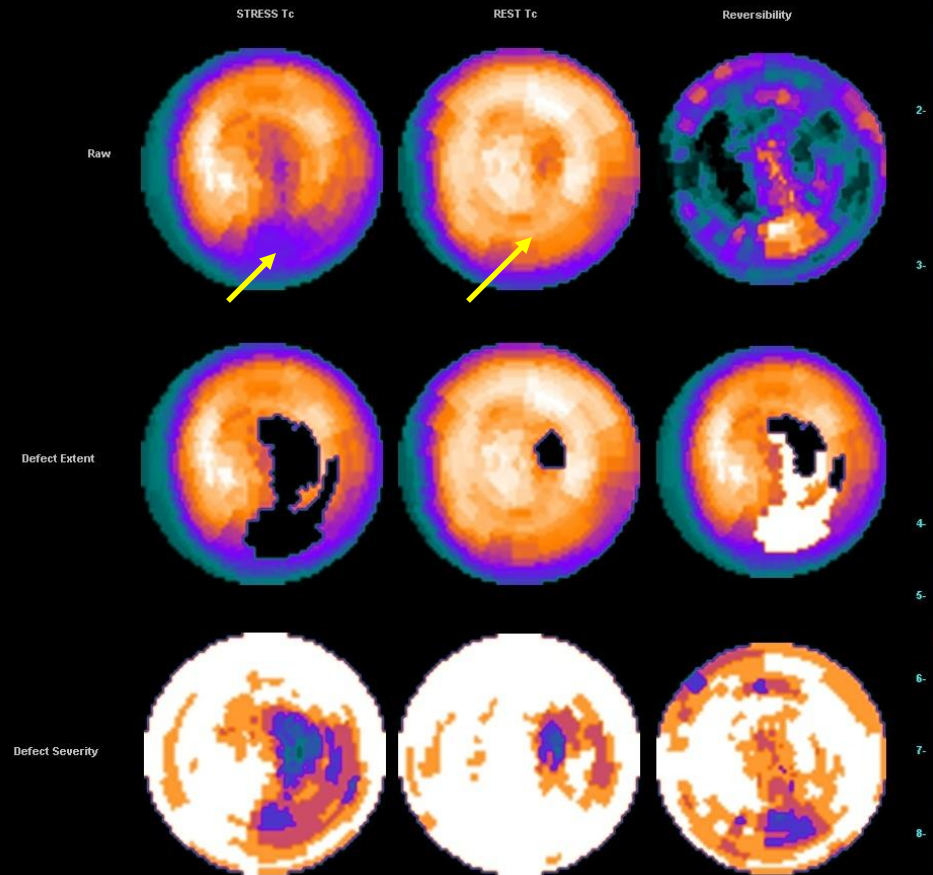
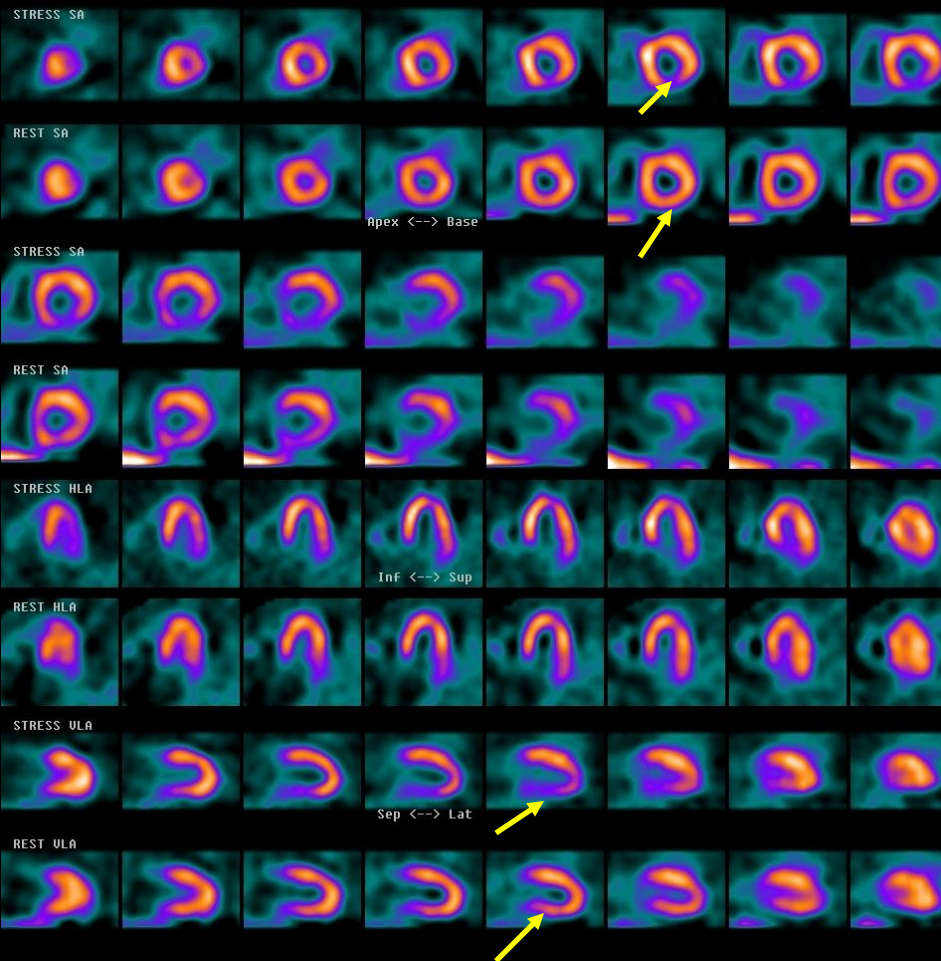
Stress = maximal perfusion

Ischemia



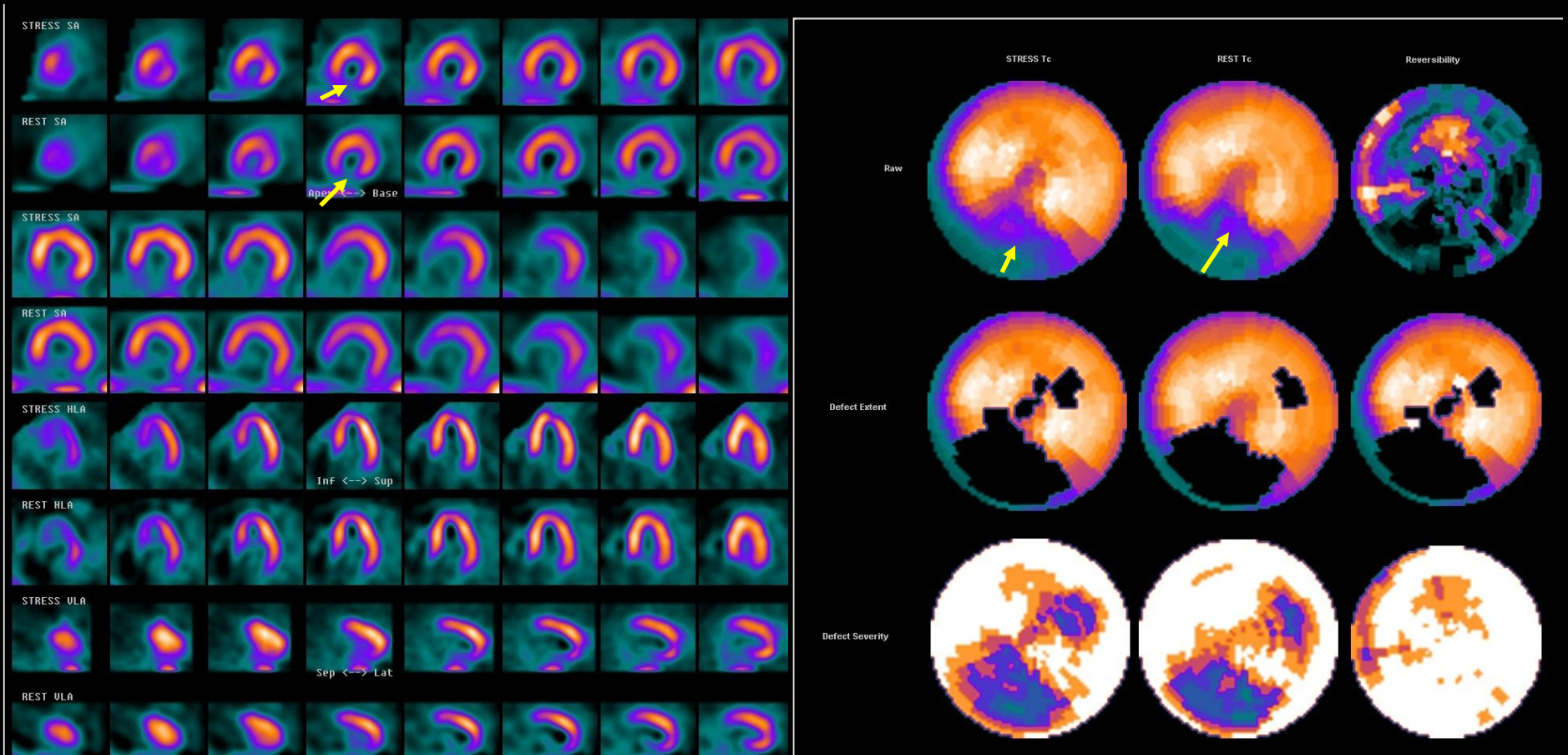
Apical septal

Ischemia



Inferior Wall

Fixed defect

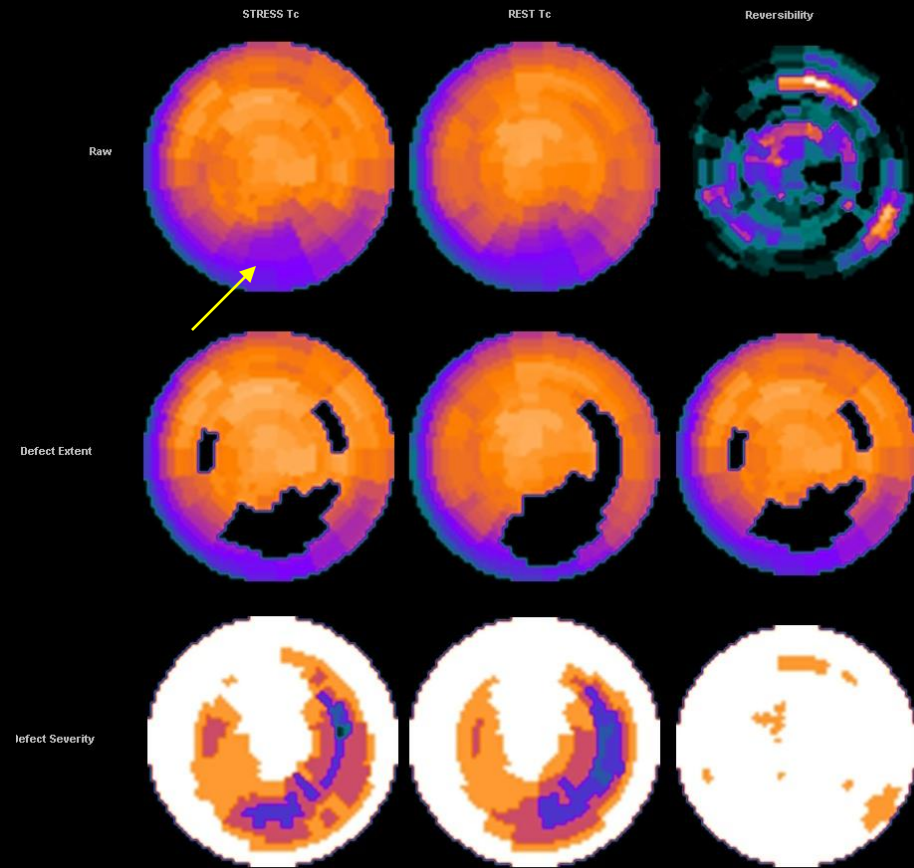
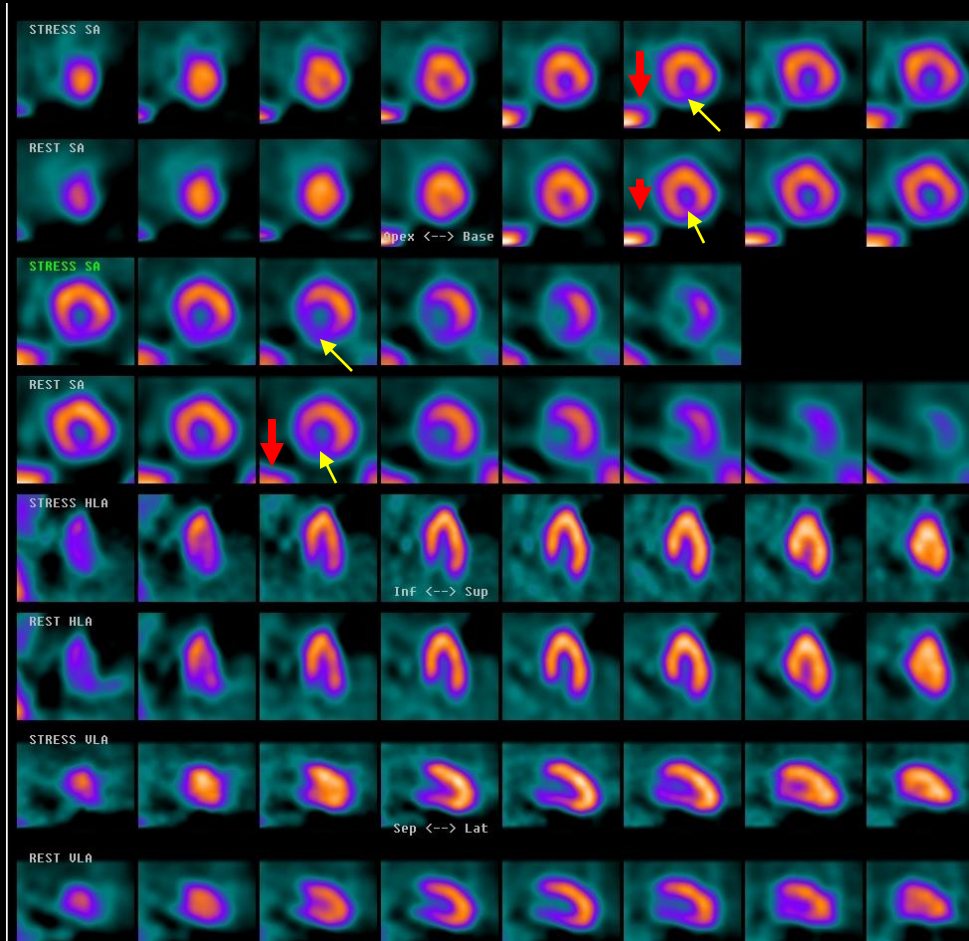


Scar vs Hibernating myocardium

Delayed imaging or PET

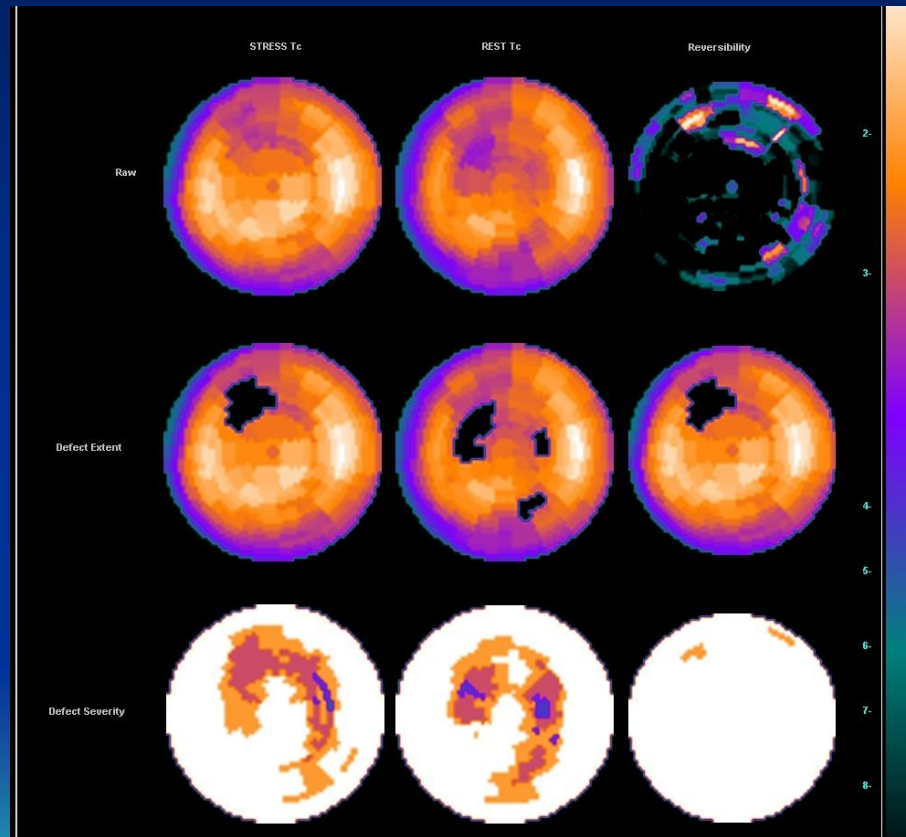
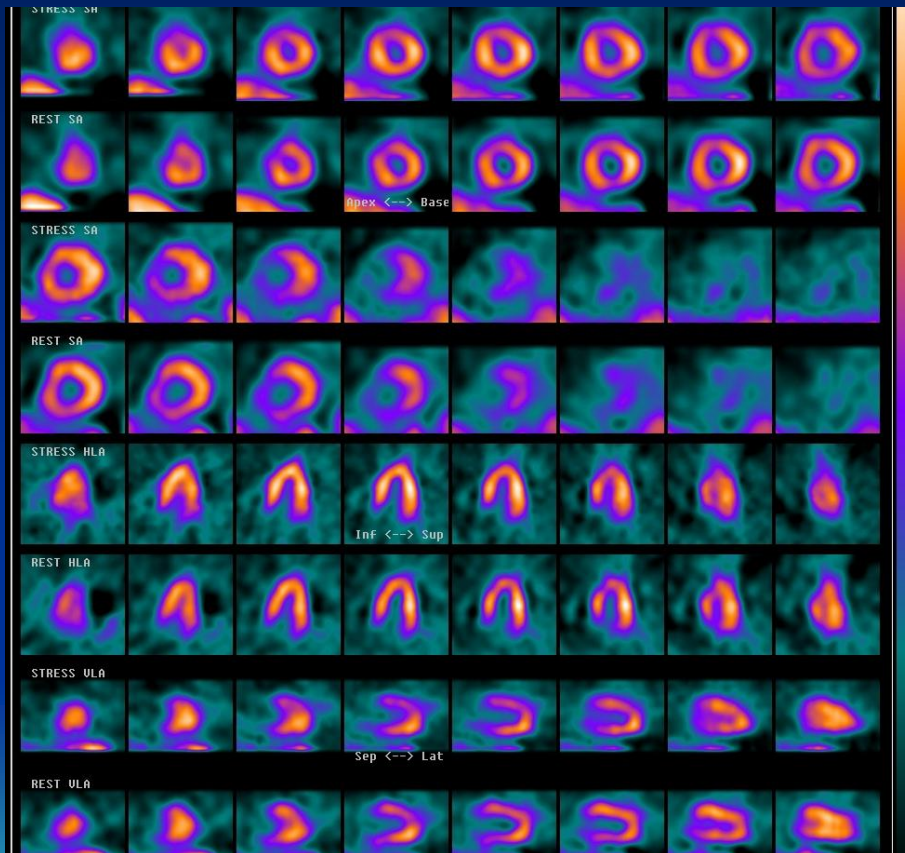
Viability

Fixed defect vs diaphragm



Liver, spleen, bowel activity – reconstruction artifact

Breast attenuation



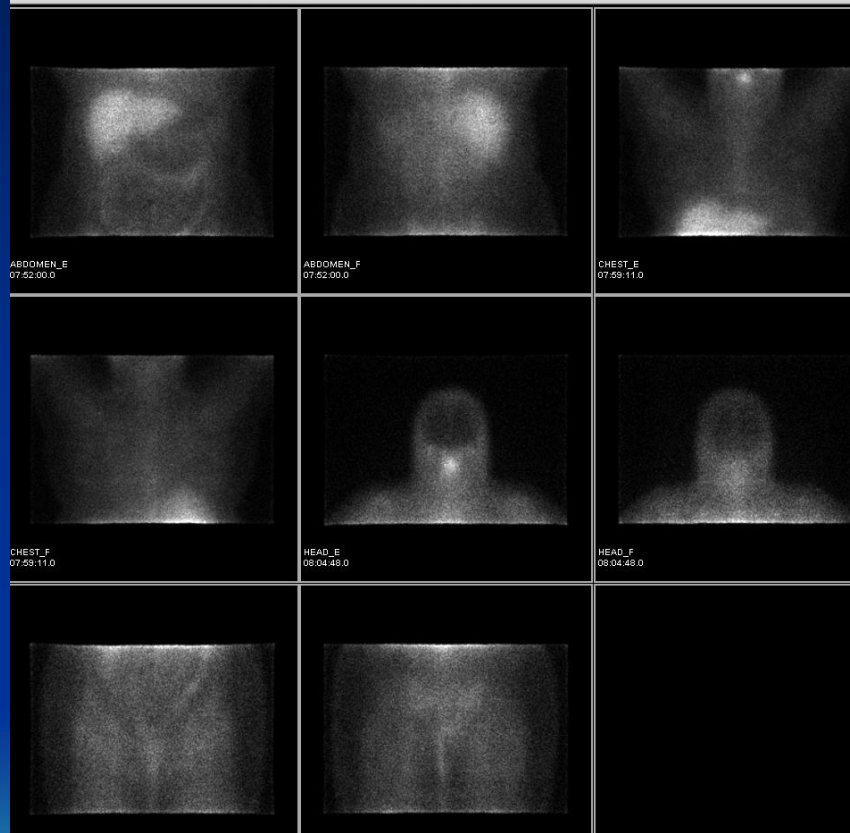
Anterior or lateral wall defect

Imaging for infection

- **Ga 67 Citrate:** not used as much anymore, former use was for neoplasm (including lymphoma and lung cancer), inflammation, infection
 - Ga-67-----complexes with plasma transferrin----carried to sites of inflammation
 - Incorporated into WBCs—bound by intracellular lactoferrin—then migrate to inflamed areas
 - Taken up by microorganisms by binding to siderophores produced by bacteria
- **In-111 tagged white blood cells.** Can also tag with Tc-99, but shorter half life.



Gallium scan – Ga-67



- Photon poor- grainy images
- Image 24-48 hours
- Bowel activity
- Sarcoidosis
- FUO
- Diskitis/spinal Osteomyelitis
- Opportunistic infections
 - Need CXR correlation
 - PCP – intense activity
 - Kaposi's sarcoma – no activity
 - Normal CXR-Normal Ga-67

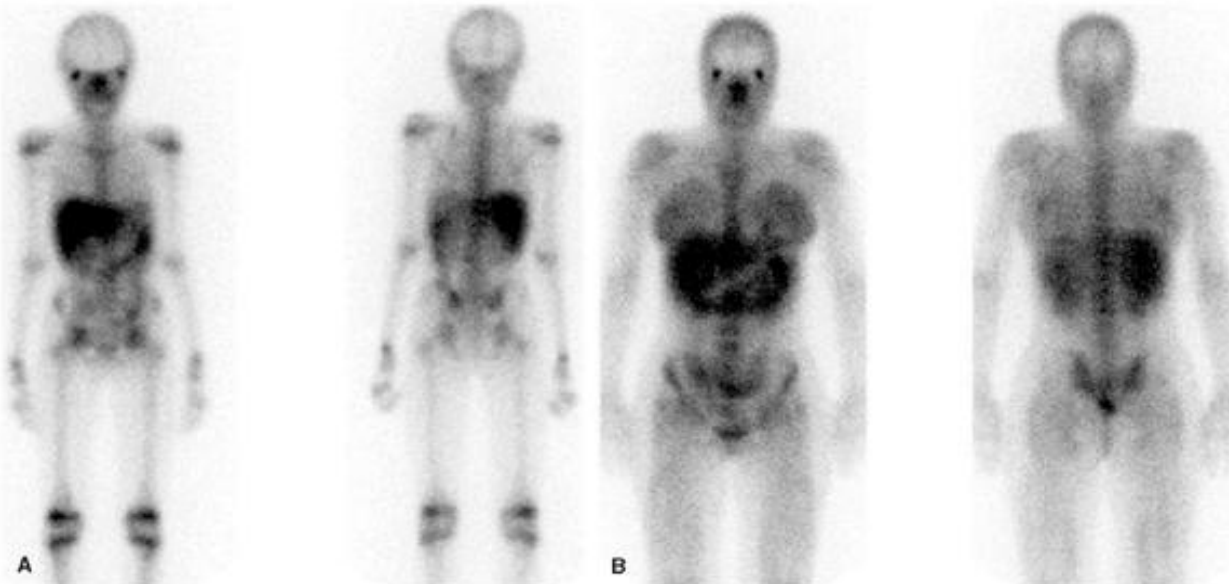
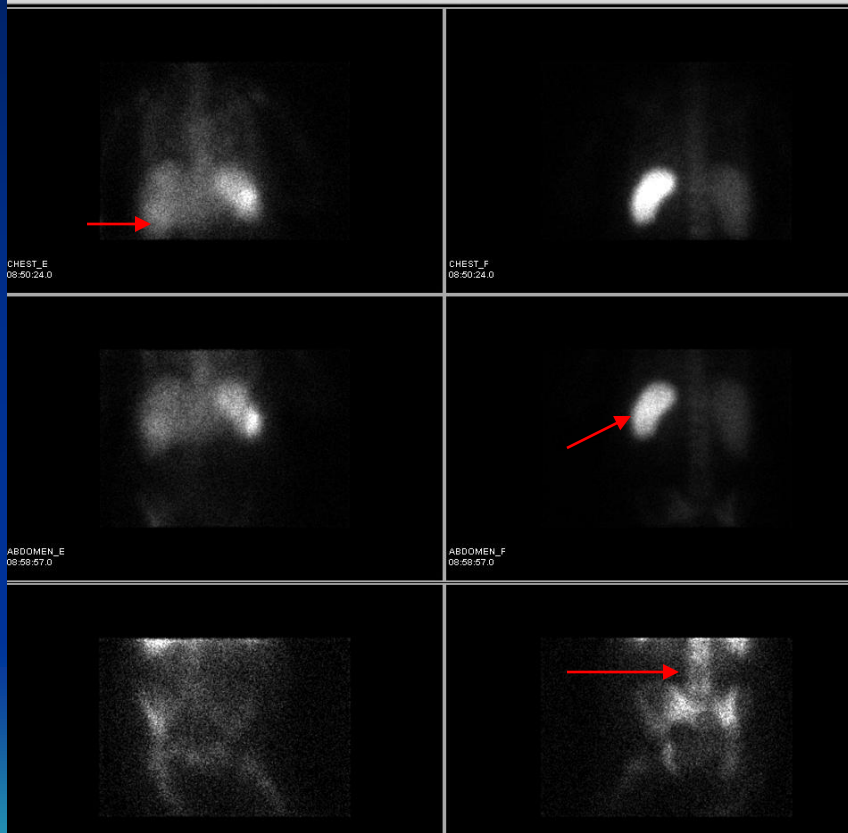


FIGURE 61.1. Normal Pediatric and Adult Gallium Studies. **A.** Anterior and posterior wholebody gallium-67 (Ga-67) images performed on an 11-year-old child. Prominent skeletal uptake is normal in children. The distal femoral and proximal tibial growth plates are easily identified. **B.** Anterior and posterior whole-body Ga-67 images performed on a 20-year-old woman. In this patient there is more soft tissue and less skeletal activity than in the patient illustrated in **A**. Note the physiologic breast activity, which can be confused with abnormal pulmonary uptake. This can be resolved by obtaining oblique and lateral views, or by SPECT.

Gallium and FOU Imaging

- Value in its nonspecificity
- Will detect pathology other than just infection
- Neoplasia
- Initial imaging should be with In-111 WBC and then followed with Gallium, if necessary (especially if FOU for less than two weeks)
- If patient has had systemic antibiotics, may get false negative with Gallium scan
- Better in children-WBC require phlebotomy

In-111 WBC scan



- Image 12-24 hr
- No bowel/renal activity
- Bacterial infections
- Prosthetic joint infection – map with Tc-sulfur colloid
- Diabetic foot infection

In-111 Oxine Leukocytes

- High sensitivity and specificity for acute infections.
- Lower for chronic infections
- Attracted to site of infection by chemotaxis (directed migration)
- Not specific for infection, accumulates in any inflammatory response that attracts leukocytes.
- Occasionally in neoplasia



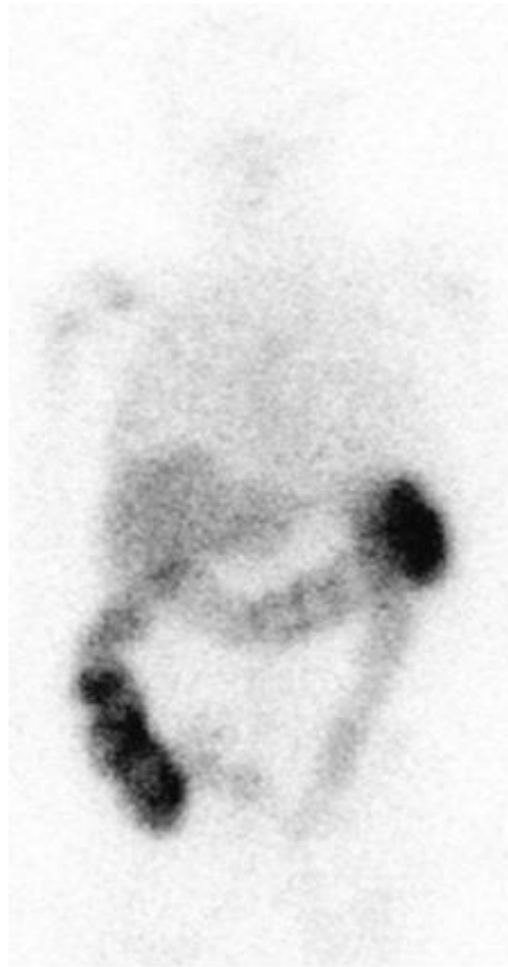
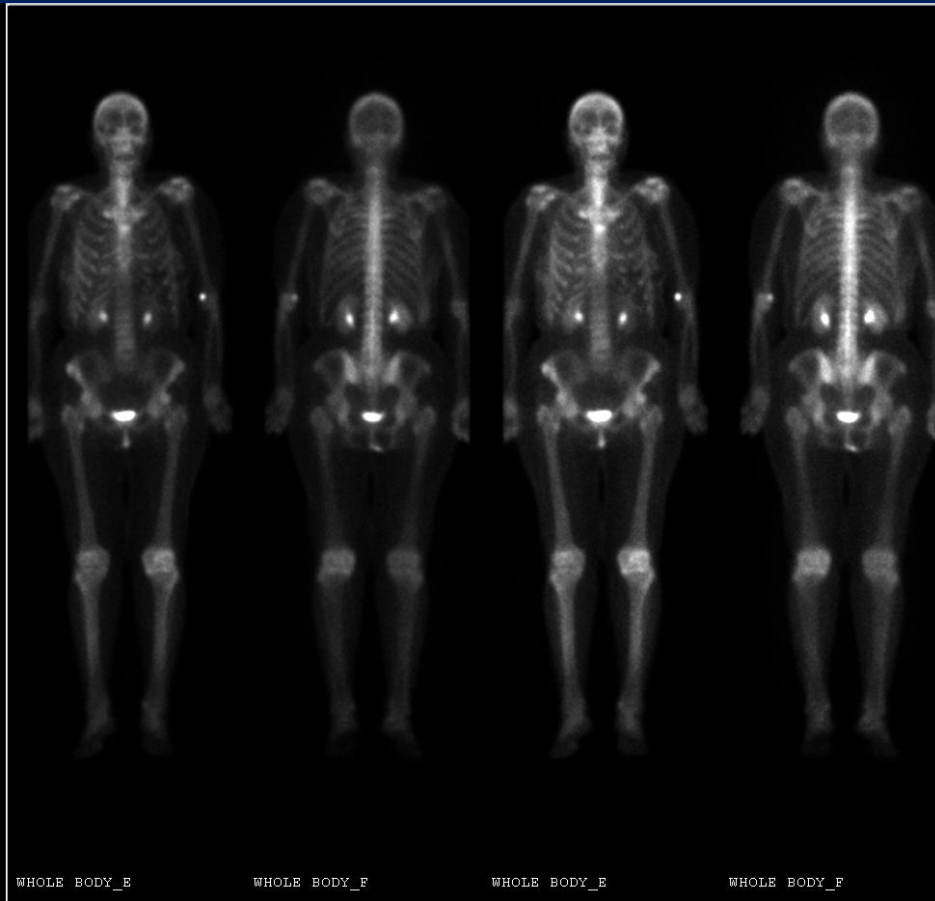
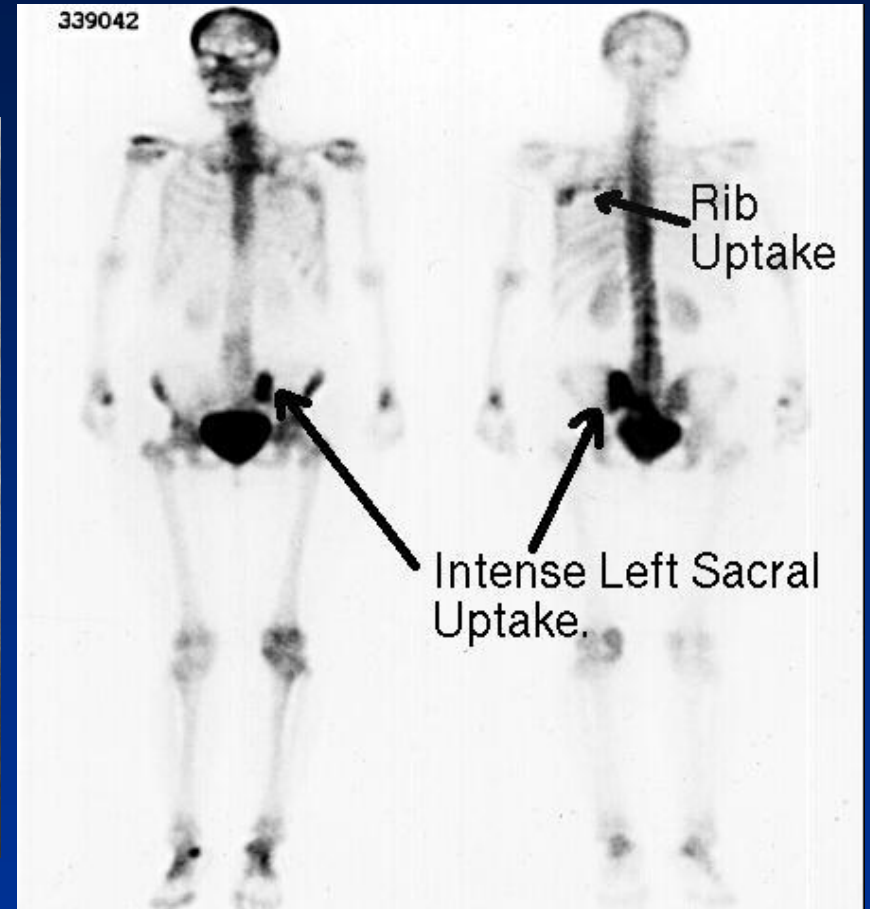
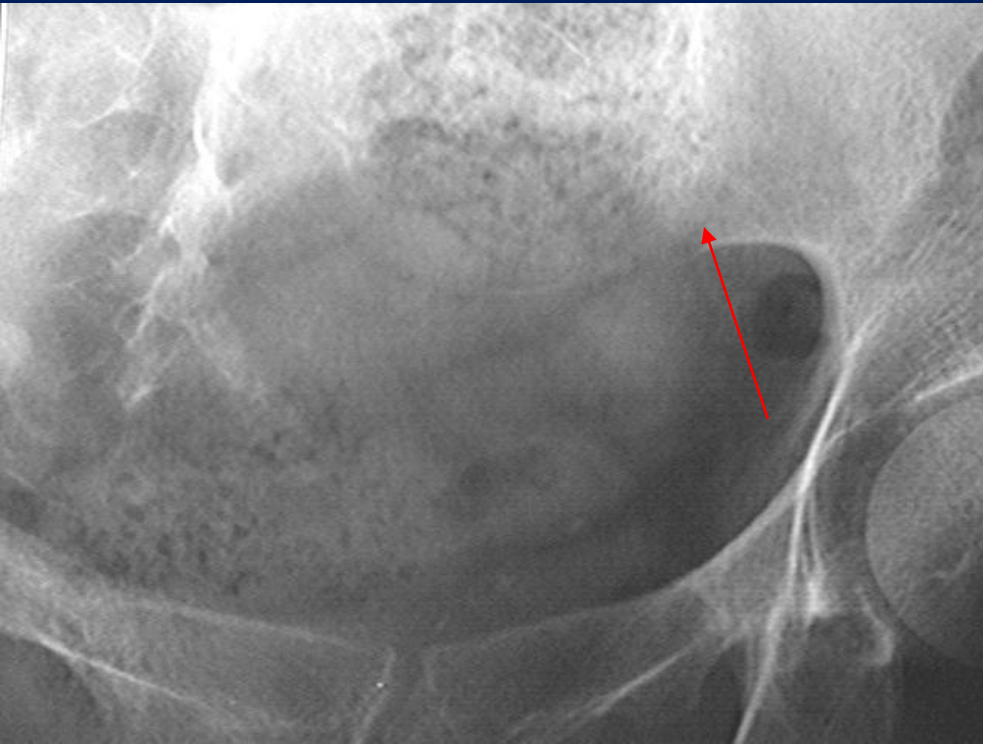FIGURE 61.14. Colitis. Anterior whole body indium–white blood cell image demonstrates intense pancolonic activity. The differential diagnosis includes antibiotic-associated (pseudomembranous) colitis, infectious colitis, ischemic colitis, and inflammatory bowel disease. No conclusions about the extent of bowel involvement can be drawn from a single 24-hour image, because activity in the bowel lumen is redistributed over time by normal peristalsis.

Bone scan Tc99m-MDP



- Increased osteoid formation/mineralization of osteoid(osteogenesis)
- Increased blood flow
- Can be affected by administered drugs
- Always obtain radiographic correlation




Bone Scan - Metastasis



- **Quality of life**
- **Therapeutic decision making**

- **Multifocal areas increased activity**
- **Red marrow: thorax, ribs, pelvis, limbs, skull**

Bone Scan - Metastasis

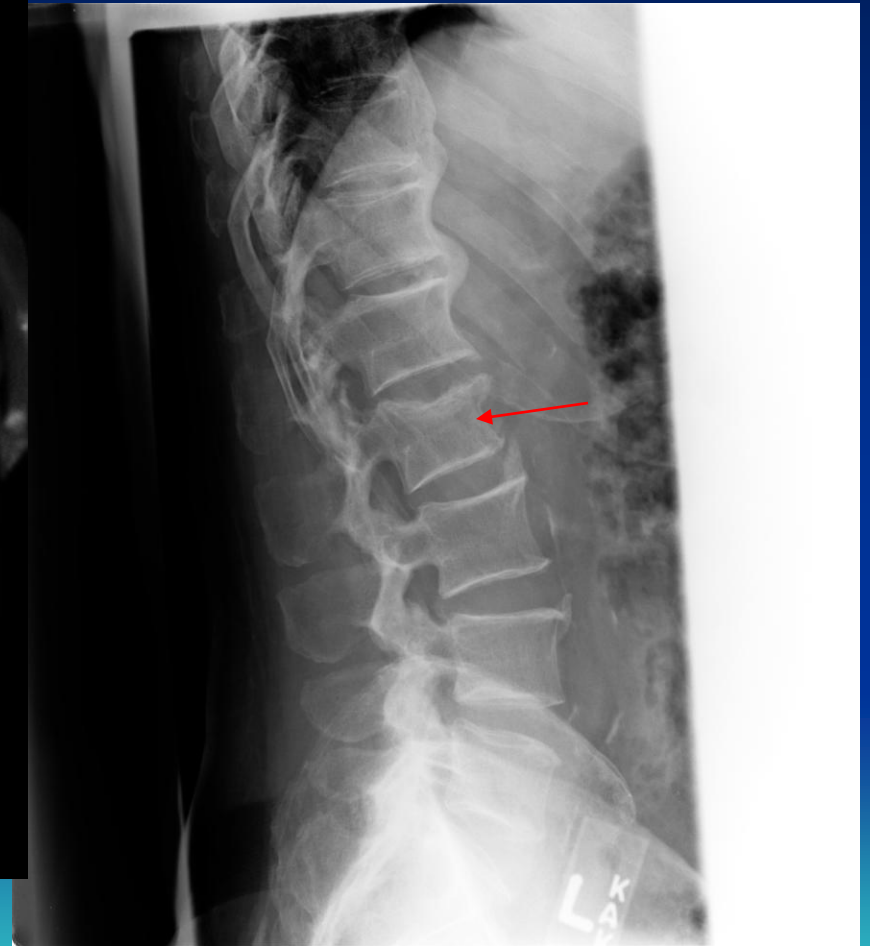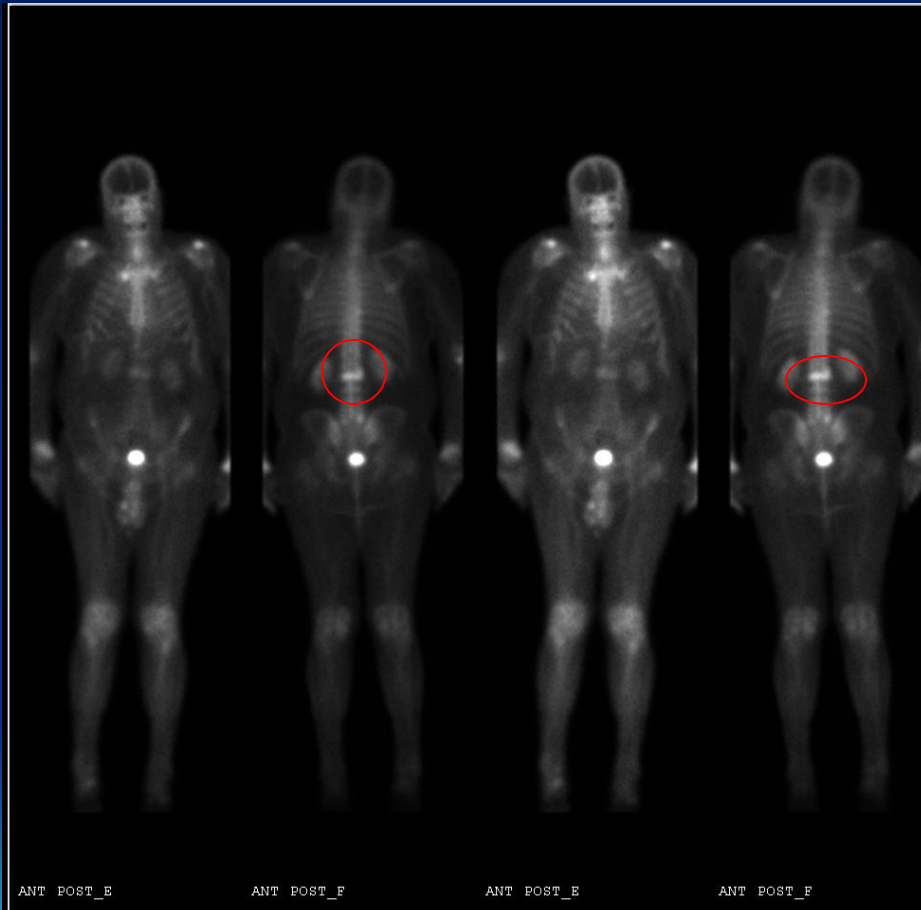
- For a lytic lesion to be visualized by radiography localized demineralization of 30-50% must occur 
- Bone scans usually demonstrate metastatic lesions much earlier than radiography 
- False negative bone scan:
 - Multiple Myeloma
 - Renal cell carcinoma 
 - Thyroid carcinoma

Bone Scan - Metastasis

- 80% of patients with known neoplasms & bone pain have metastasis documented by the bone scan

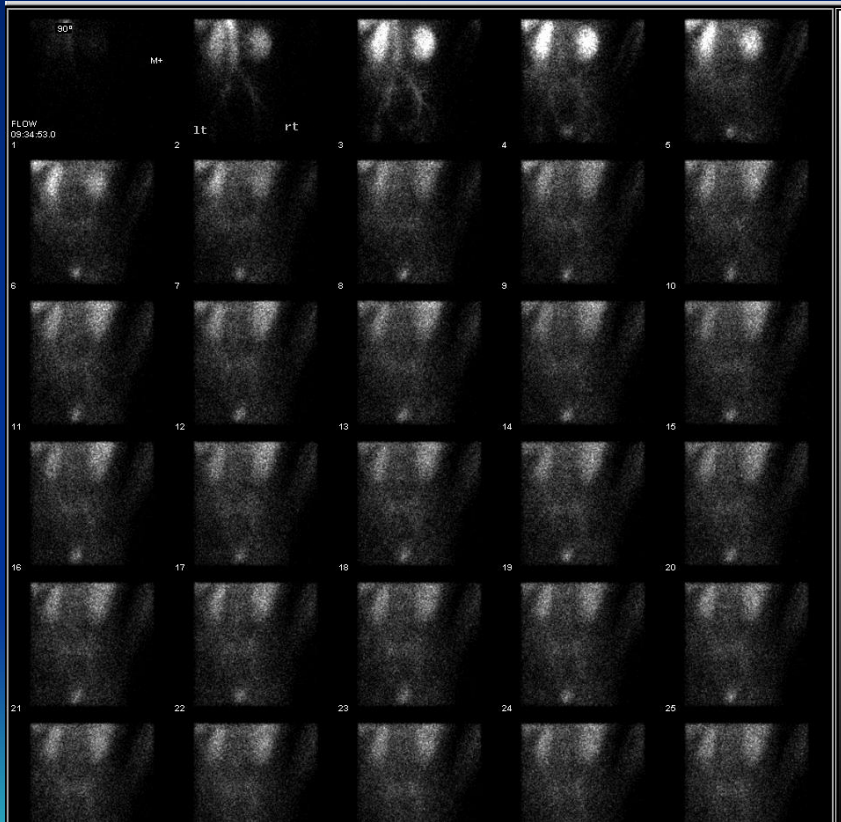


Bone scan – Lumbar fracture

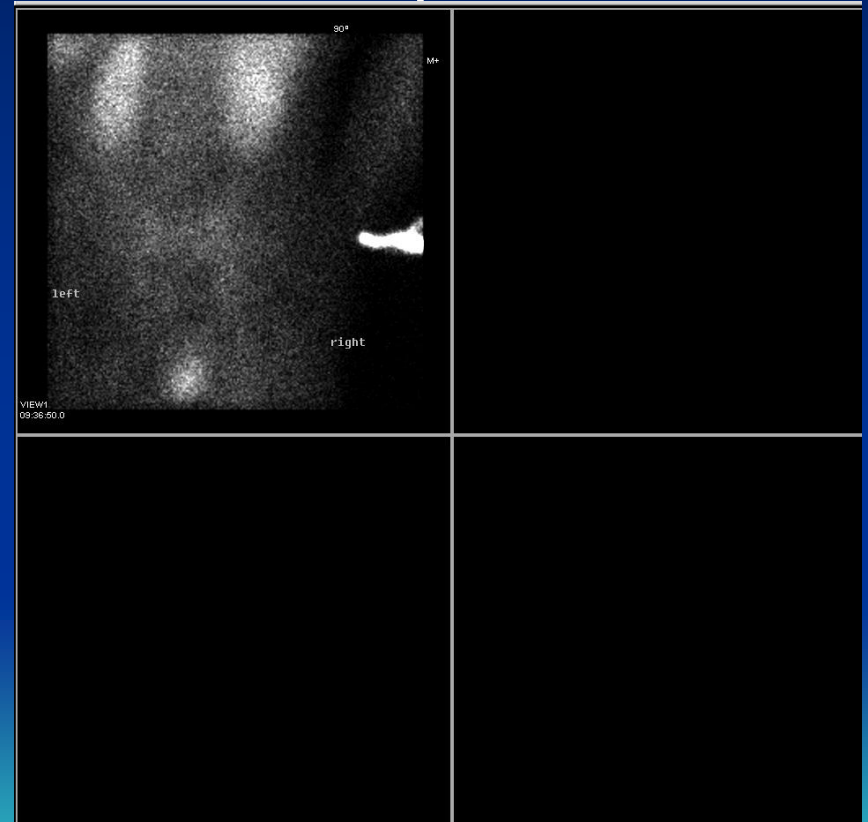


Bone scan 3-phase

- Flow

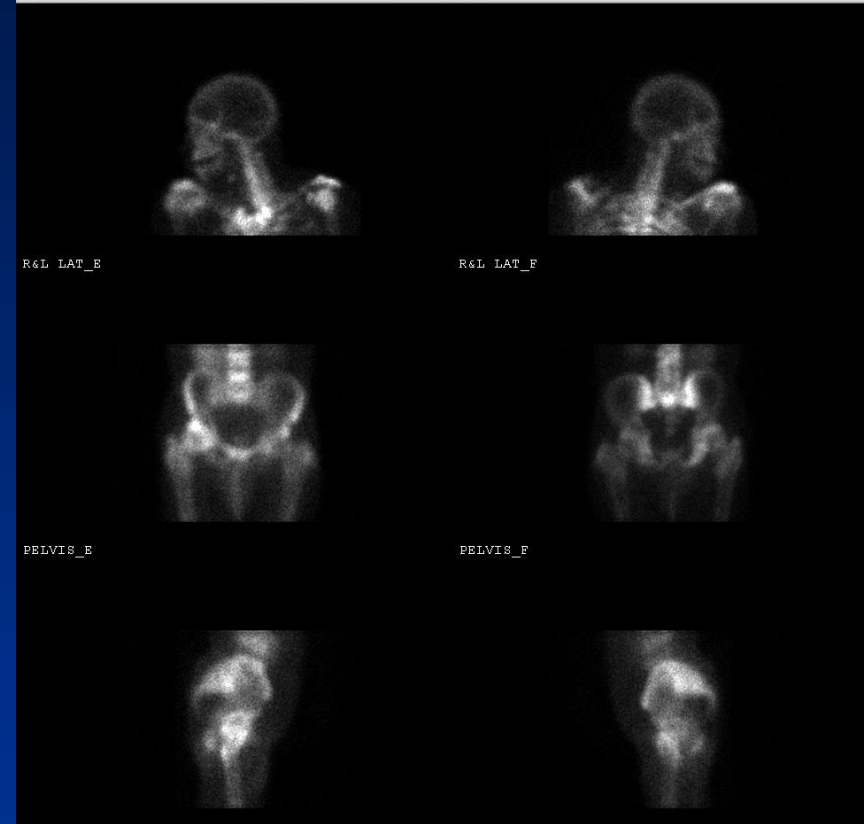
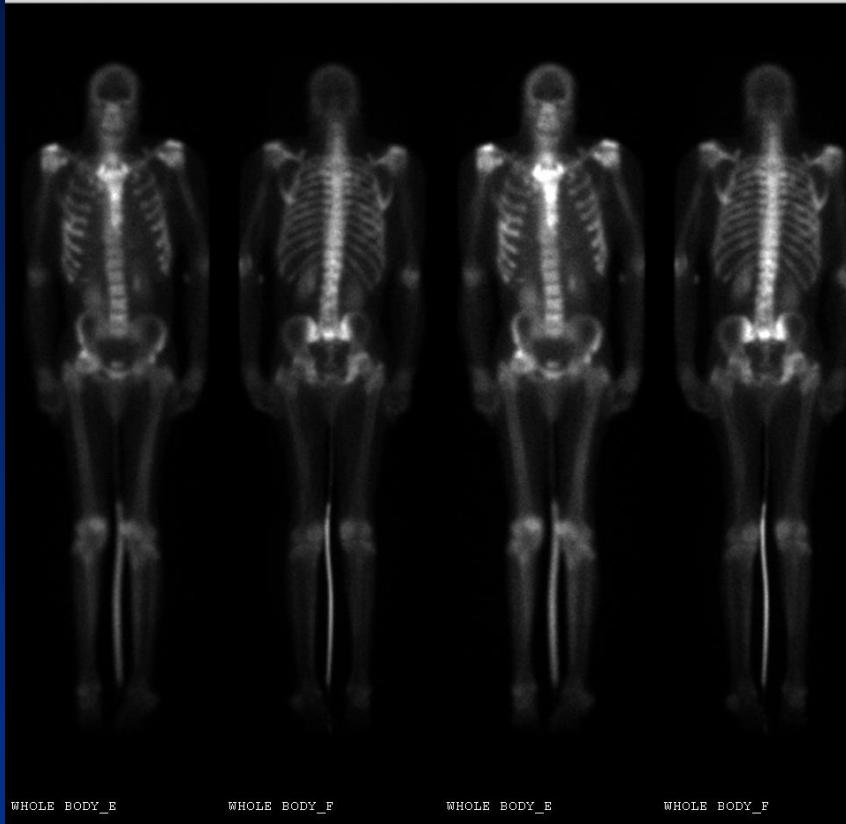

- Blood pool



Bone scan 3-phase

- Delay



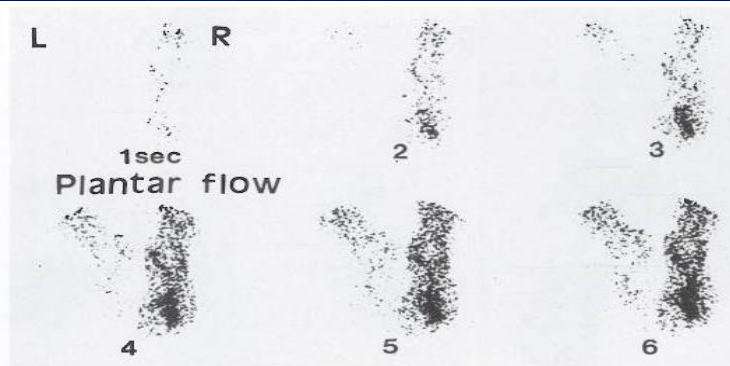
- **3-phase positive:**



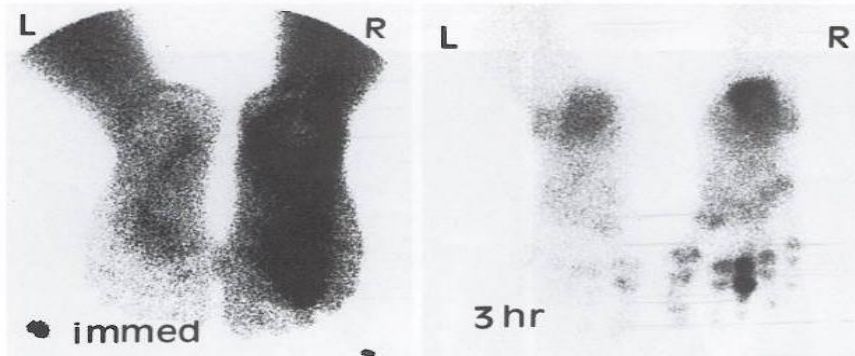
Osteomyelitis
Acute fractures

- **Bone tumors**

- **Cellulitis – 2-phase**
- **Shin splints – delay only**

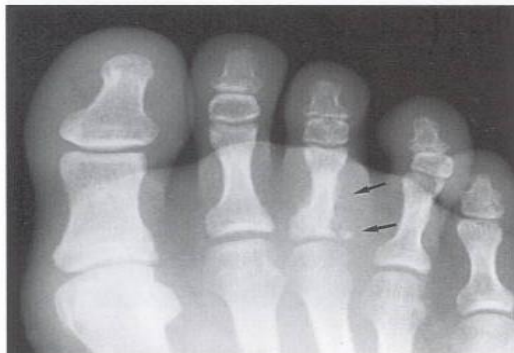

A



B

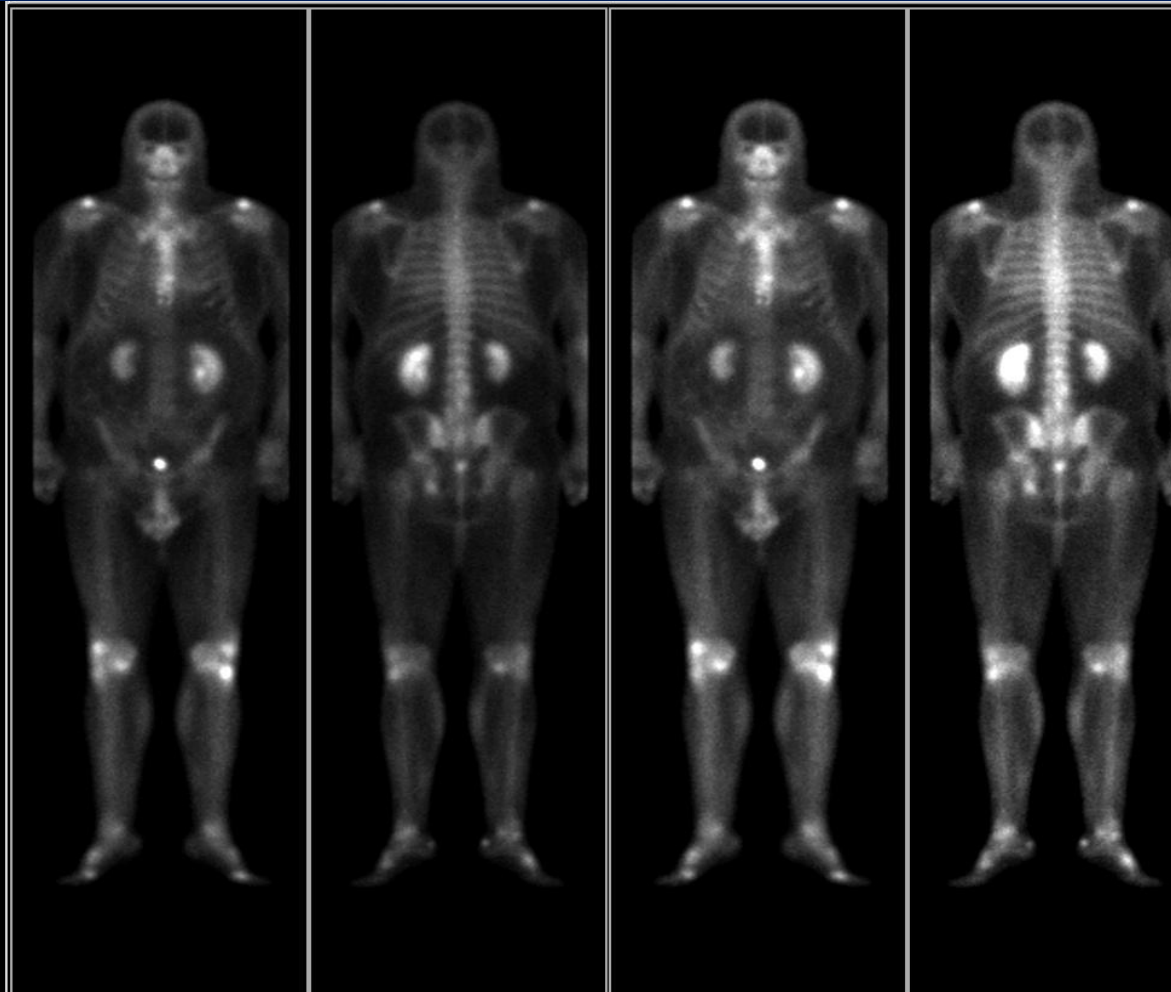
C



D

FIGURE 9-42. Osteomyelitis. Plantar images from a three-phase bone scan show increased flow (A), increased blood pooling (B) in the whole foot, and intense focal activity on the delayed view (C) in the region of the right third toe. The findings are compatible with osteomyelitis. D, A normal radiograph of the right foot at the time of the bone scan became frankly abnormal 2 weeks later (arrows).

Bone scan - Arthritic



Uses of Nuclear Medicine

- Thyroid, Iodine-123 or Technitium-99
- Liver-spleen, largely replaced by CT or MRI
- Biliary, filling gallbladder, biliary ducts
- Renal scan
- Brain scans, replaced by CT
- Others

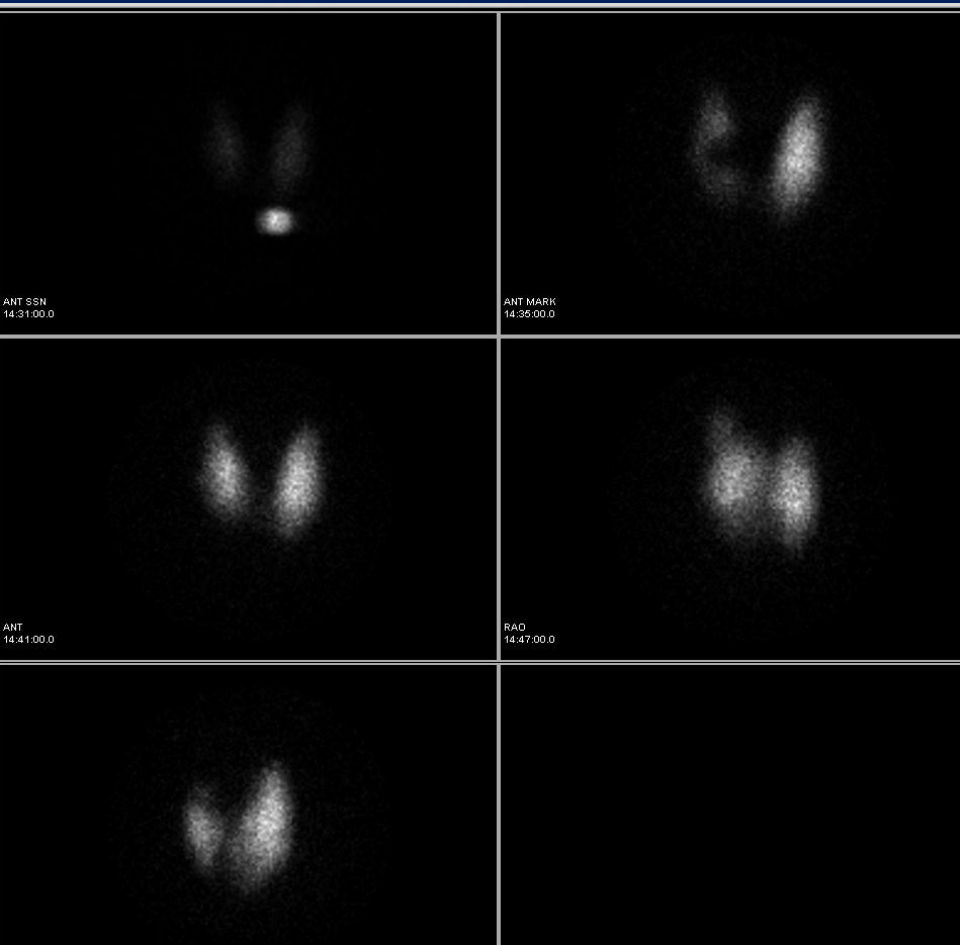

Thyroid scan

- **Thyroid Scan** using Tc99 pertechnetate or I-123
- **Radioactive Iodine uptake** using I-123 or I-131
- Normal uptake in our area 5-15% for 6 hours and 10-30% for 24 hours (10-40% for 24 hours in North and Midwest)
- Total body I-131 used for thyroid cancer evaluation

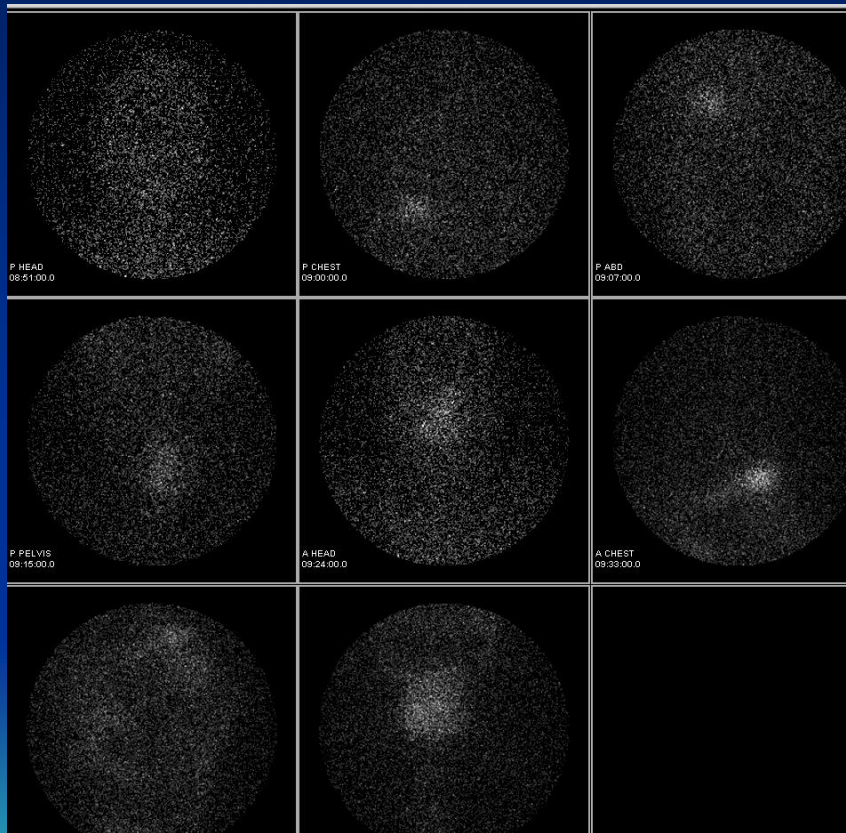


Thyroid scan



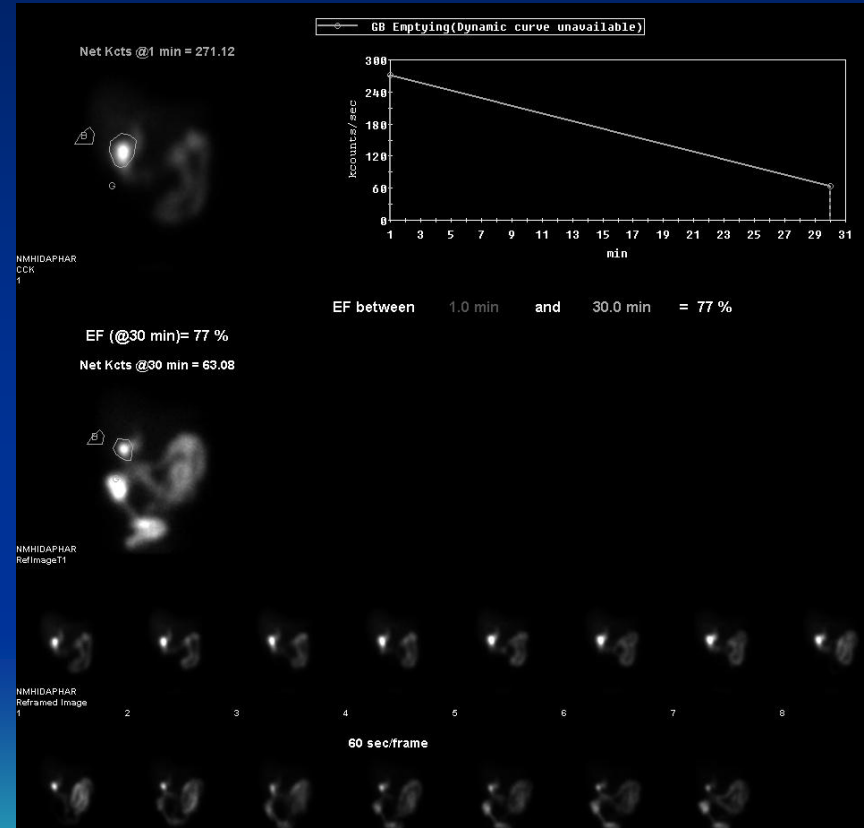
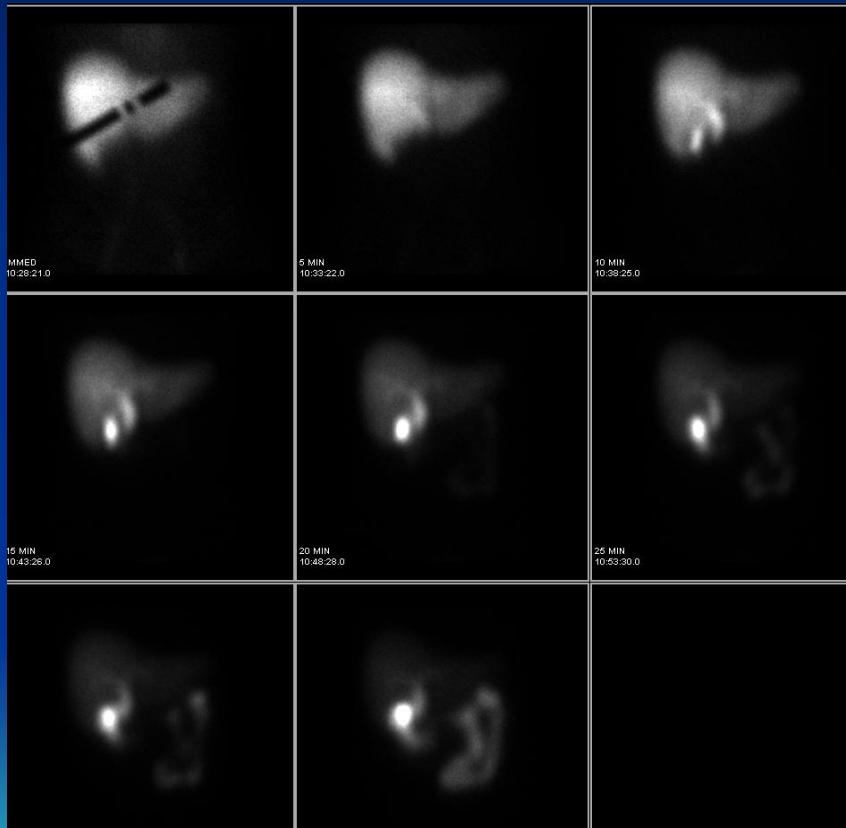
- Hypo or hyperfunction
- Nodules
- Ectopic thyroid
- Organification defect

Total body I-131

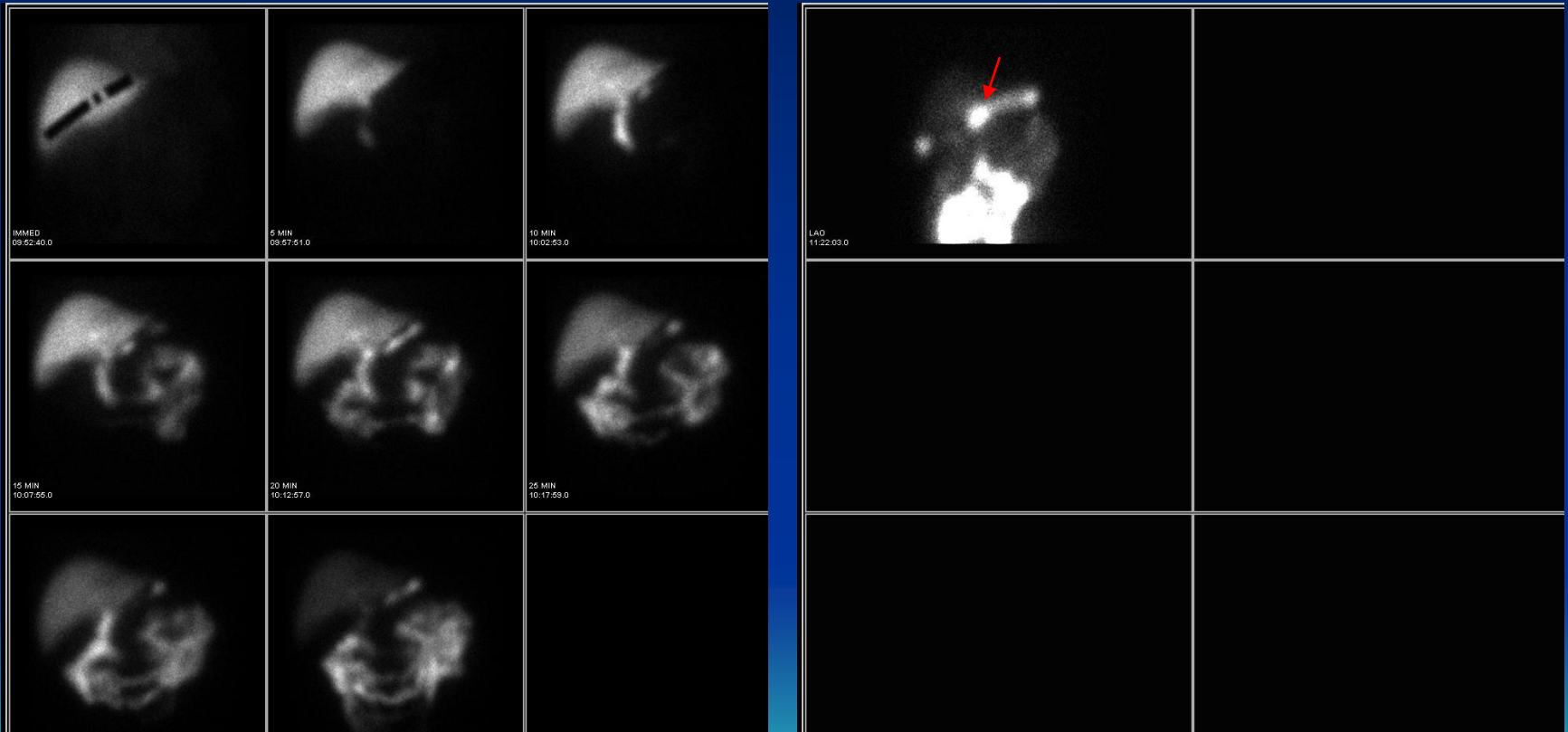


- Post-thyroidectomy
- Postradioiodine Therapy imaging
- I-131: treatment of Graves' disease and multinodular goiter

Hepatobiliary Imaging Tc99 IDA (cholecystokinin injection)

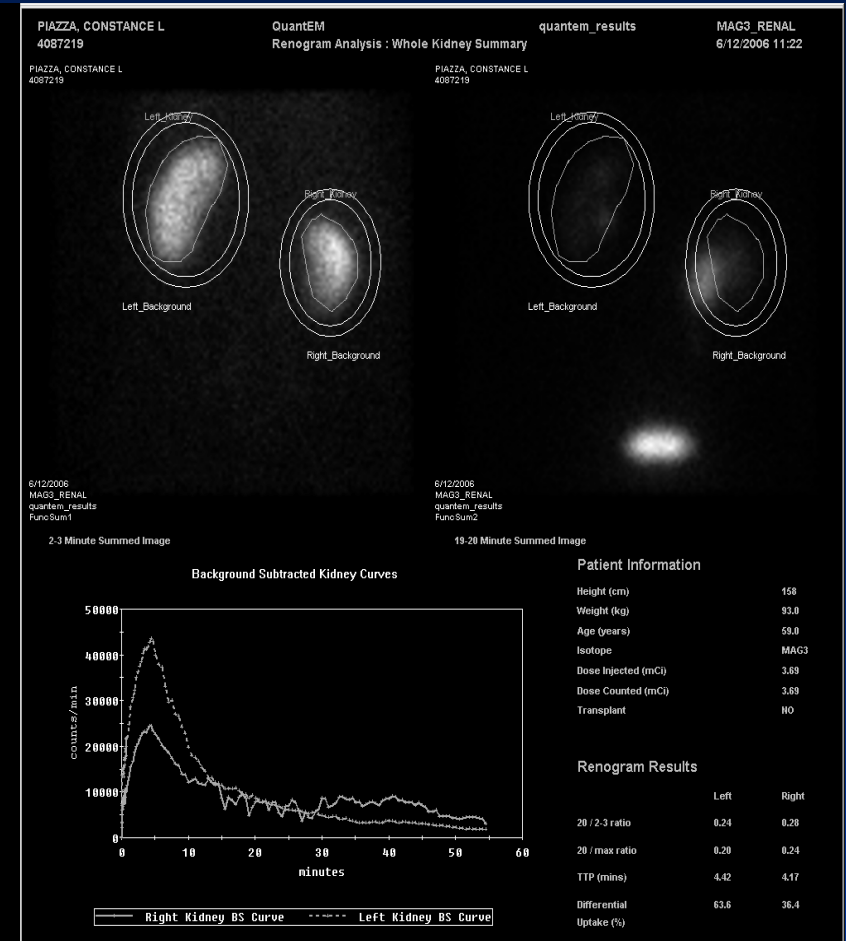
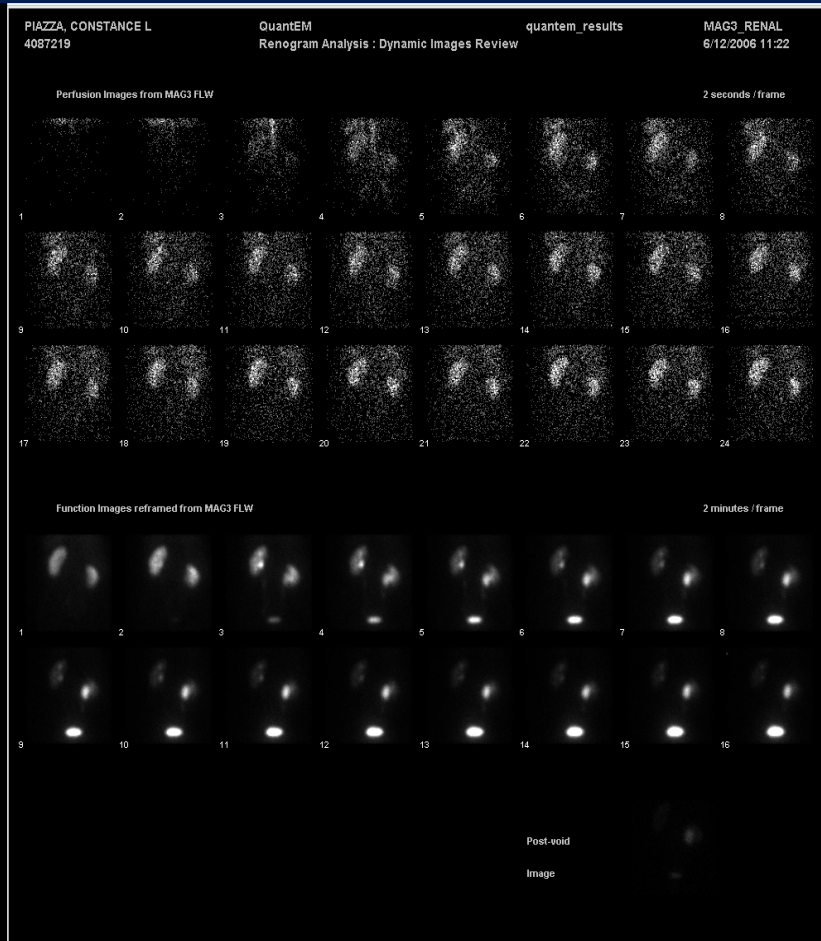


Hepatobiliary Imaging (morphine injection)



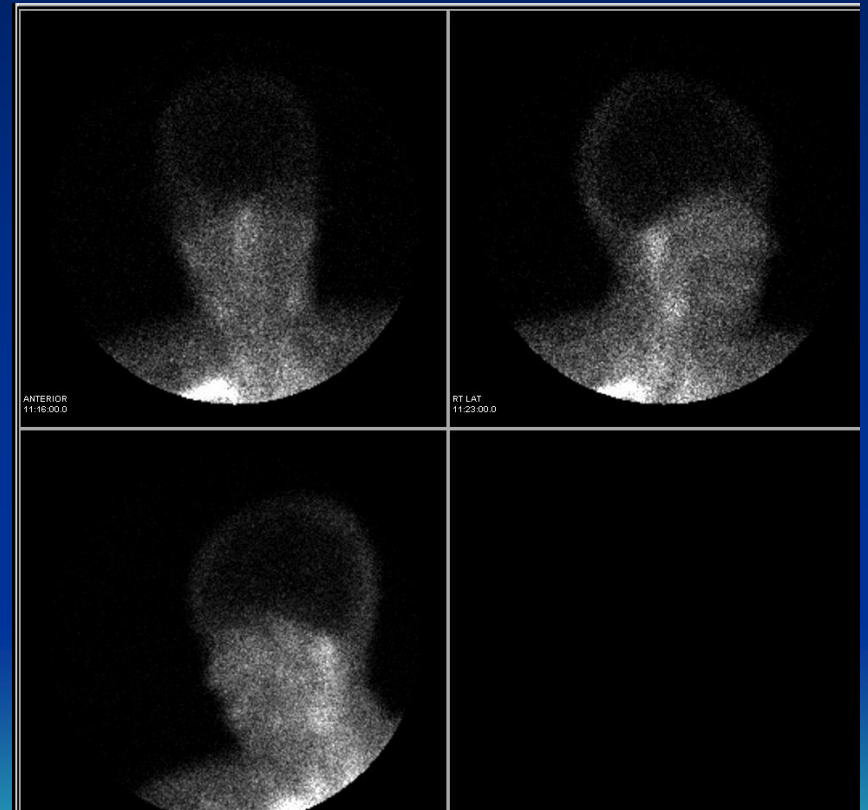

- 1 hr – Gallbladder not visualized

Renal scan Tc-99m MAG3



- **Renal function, images similar to IVP**
- **Indications: Renal srtery stenosis**
- **Acute tubular necrosis, obstruction, pyelonephritis**

Brain scan, brain death (TC99)



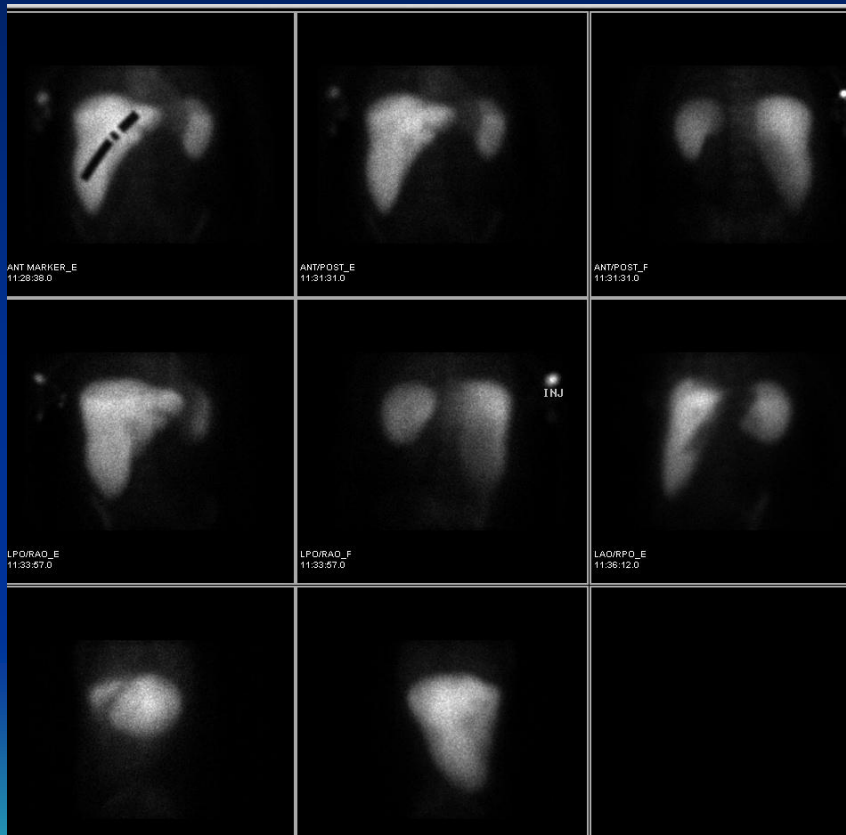
Uses of Nuclear Medicine

Lymphatic mapping

- ^{99m}Tc **Sulfur Colloid**
- Breast carcinoma and melanoma
- Injection for lymph node localization for biopsy (sentinal node)



Liver scan: Tc99 Sulfur colloid



- Hepatocellular disease
- Confirmation of specific space occupying lesions – ie, focal nodular hyperplasia

Radiology Evaluation of Cancer

- Plain Films and Associated Studies
- CT Scan
- MRI
- Nuclear Medicine
- Ultrasound
- **PET**



Positron Emission Tomography - PET

- **Radionuclide with excess protons**

• ↓ Decay

- **Positrons**

- **Positron + electron collision**

• **Annihilation reaction generates two 511-keV gamma photons**

- **PET detector ring for localization & imaging**




Type of Pet Scanners

- PET Scanner
- PET/CT Fusion Scanner



PET – CT Fusion Scanner

- Combination of **Positron Emission Tomography** (PET) and Helical CT
 - PET detects area of increased **metabolic activity** as indicated by uptake of radioactive glucose (tumor, infection)
 - PET data is then “fused” with CT data to produce an image showing increased **glucose uptake** superimposed upon the exquisite anatomic detail of **helical CT**
- 

Uses of PET

- Brain
- Cardiac
- Oncology



Cancers evaluated with PET

- Lung
- Lymphoma
- Melanoma
- Colorectal
- Breast
- Esophagus
- Head and Neck



Also

- Thyroid carcinoma: Approved for history of only 1 type of thyroid carcinoma (Follicular) with negative I-131 scan and rising tumor markers
- GU malignancies (Renal, Prostate, Cervical and Ovarian)
- Under review for sarcomas
- Outpatient procedure



Uses of PET

- Diagnosis of cancer (especially lung)
- Staging of cancer
- Restaging of cancer



Note

- Use of PET scan for treatment response may not be covered
- Except in Breast Cancer and certain type of thyroid carcinoma (follicular)



F-18 FDG

- Fluoro-deoxyglucose
- F-18 on a glucose (sugar) molecule
- 110 minute half life
- Cyclotron produced, now commercially available
- Competes with glucose
- Cancers are glucose active



Preparation

- NPO 4-6 hours, except water
- May take medications
- No regular insulin within 4 hours of administration
- Patients on certain insulin preparations may have half dose
- Take serum glucose level, needs to be below 200 (Need to reschedule if above 200)
- Elevated glucose level competes with F-18FDG
- Elevated insulin levels = increased muscle uptake



F-18 FDG

- Tumors – increased # glucose transporters - energy source
- F-18 FDG: interact with glucose receptors
- Phosphorylated inside cell: F-18 FDG 6P
 - Blocked from further metabolism and trapped in cell



PET Image Quantification

- SUV: Standard Uptake Value
 - Based on ROI radioactivity/administered activity/body weight

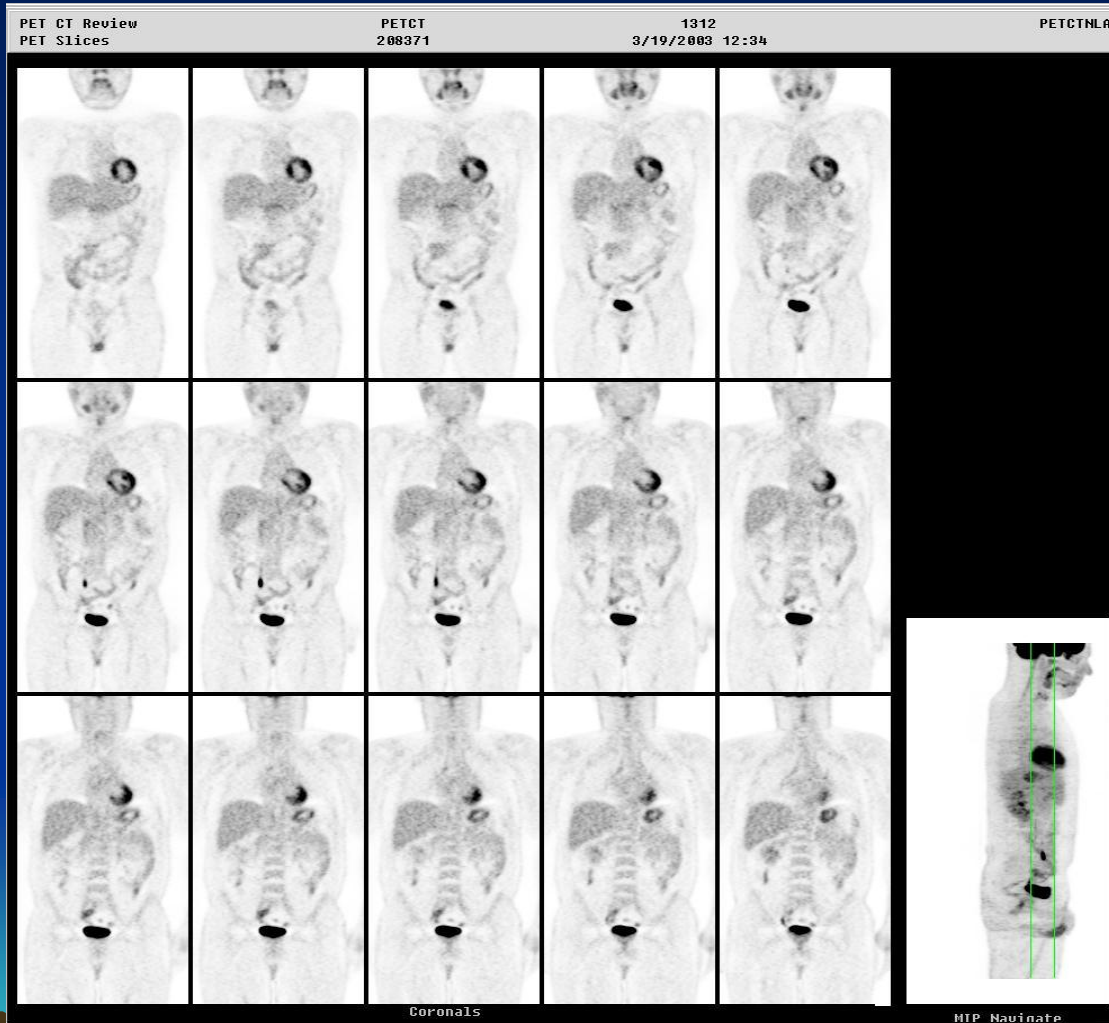


Physiologic uptake or accumulation

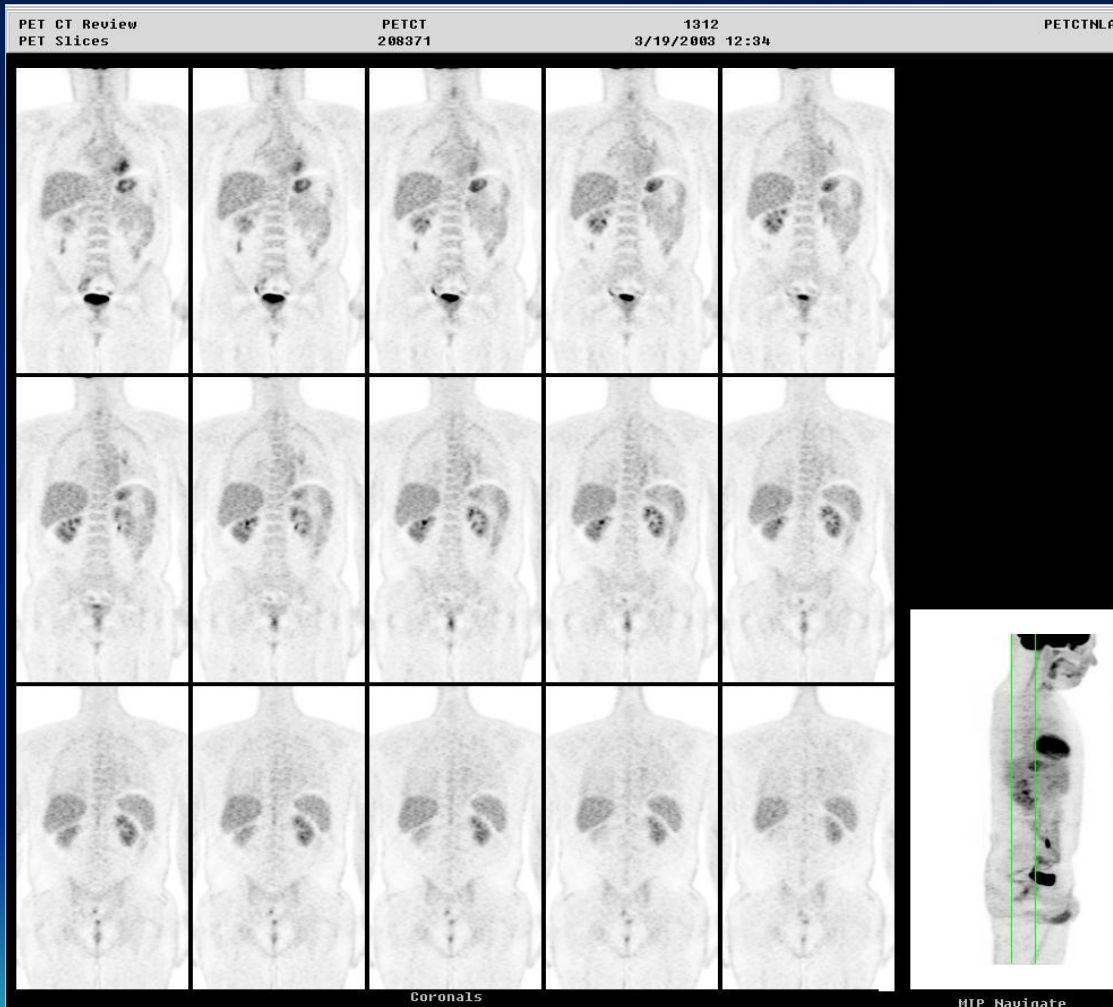
- Brain
- Salivary glands
- Pharynx, larynx
- Liver, Spleen, Bone marrow
- Heart
- GI, including colon
- Renal excretion, ureters, bladder



Normal

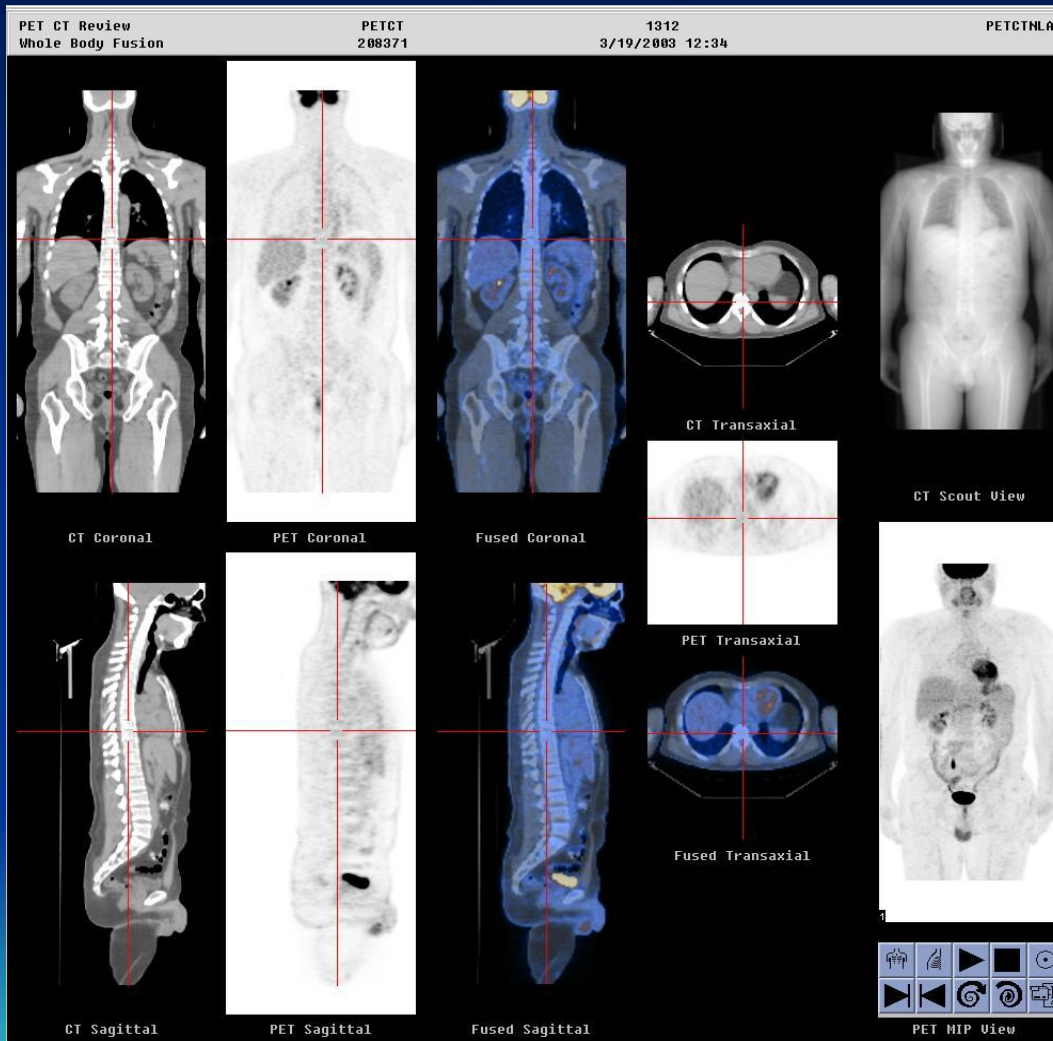


Normal

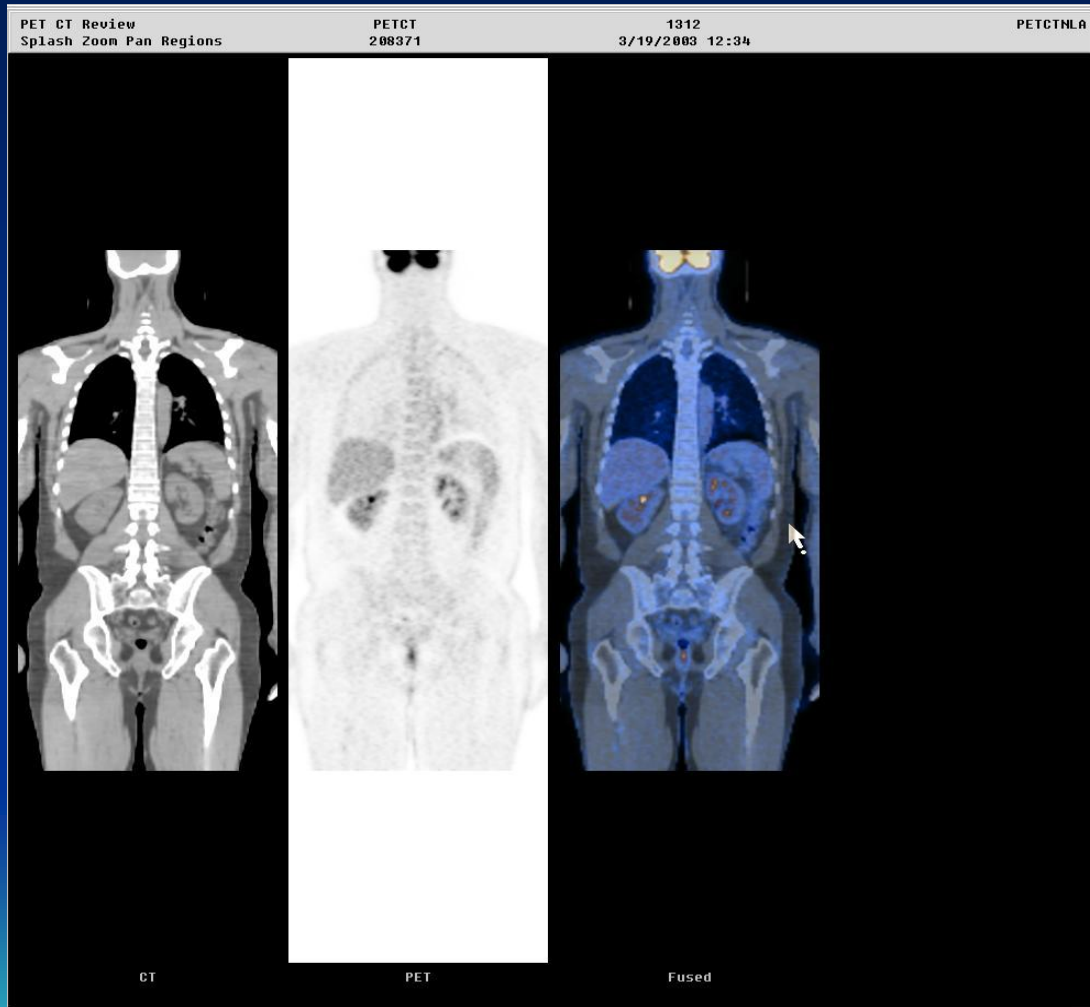


- Brain
- Heart
- Liver
- Bowel
- Urinary system
- Bone marrow

Normal



Normal

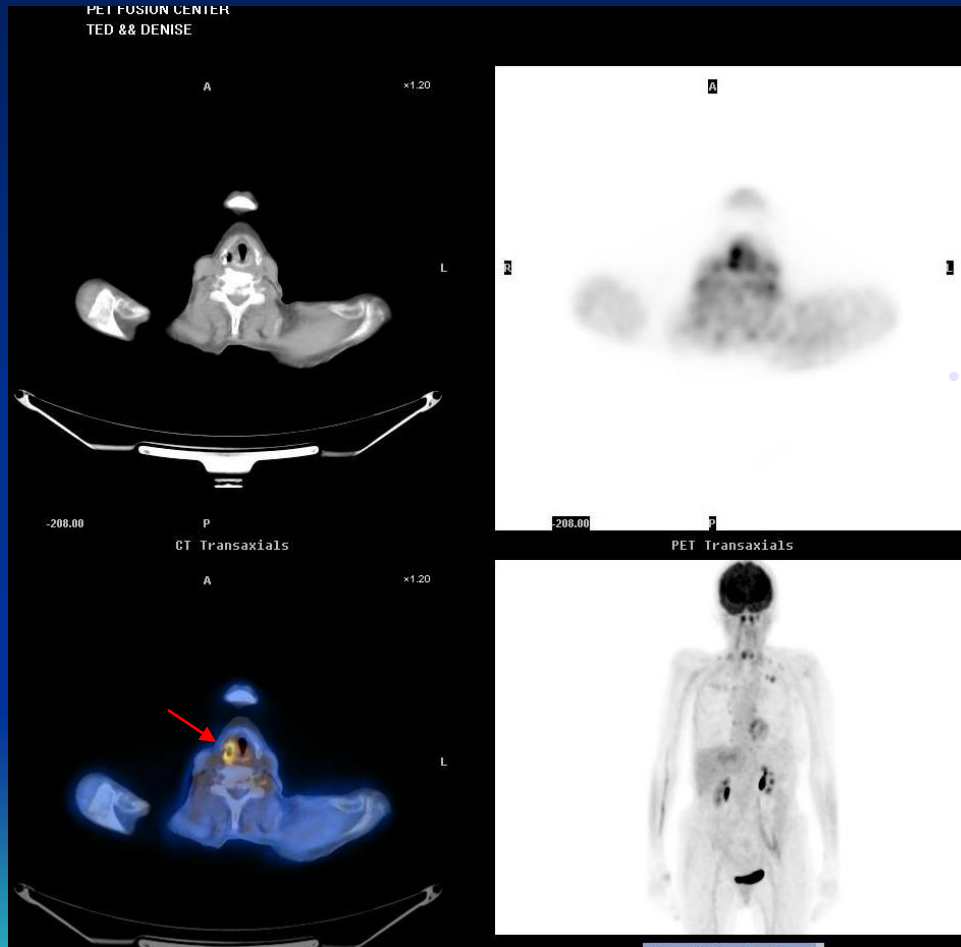


Artifactual uptake

- Muscle
- Fat (Brown Fat)

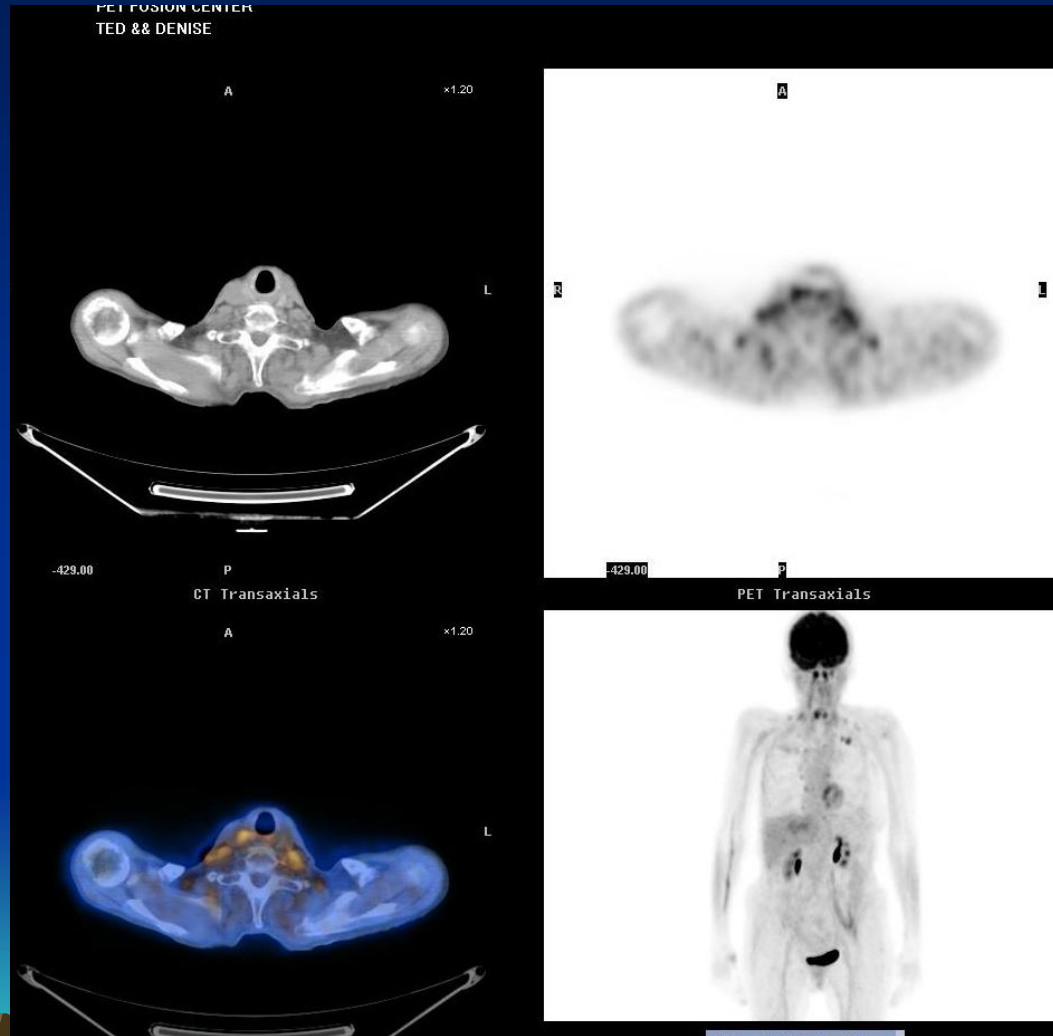


Artifactual

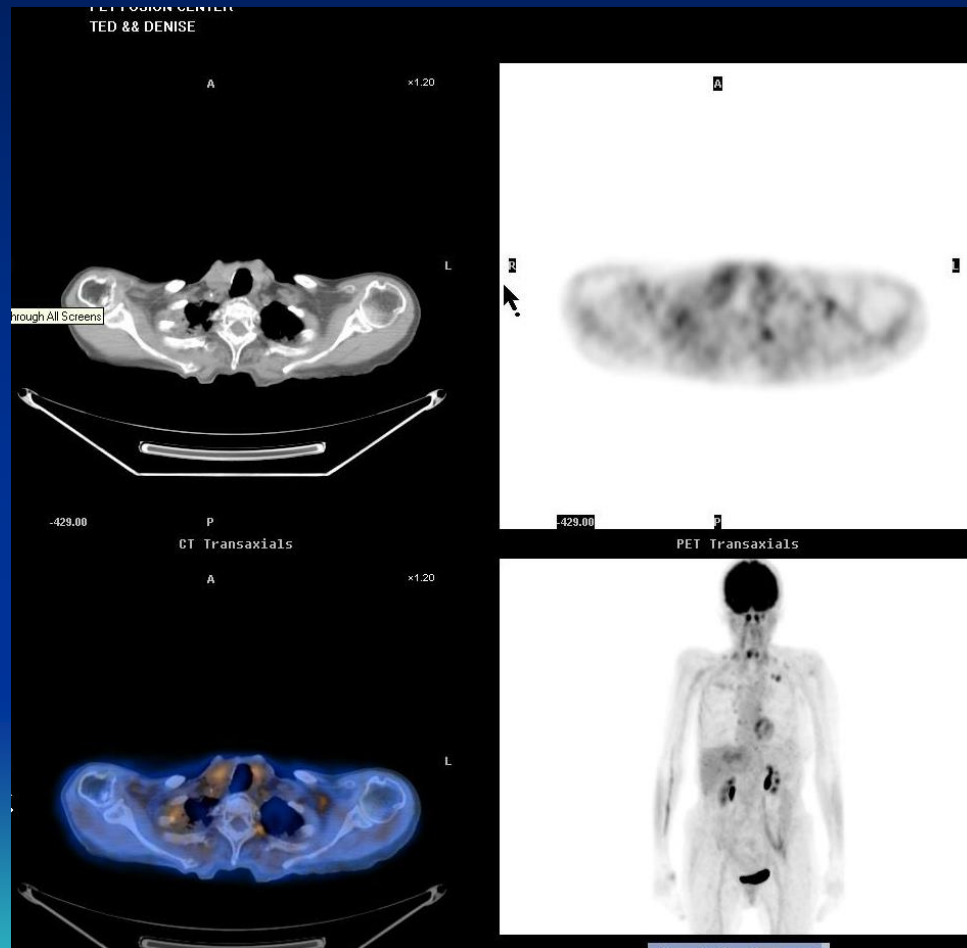


Larynx activity

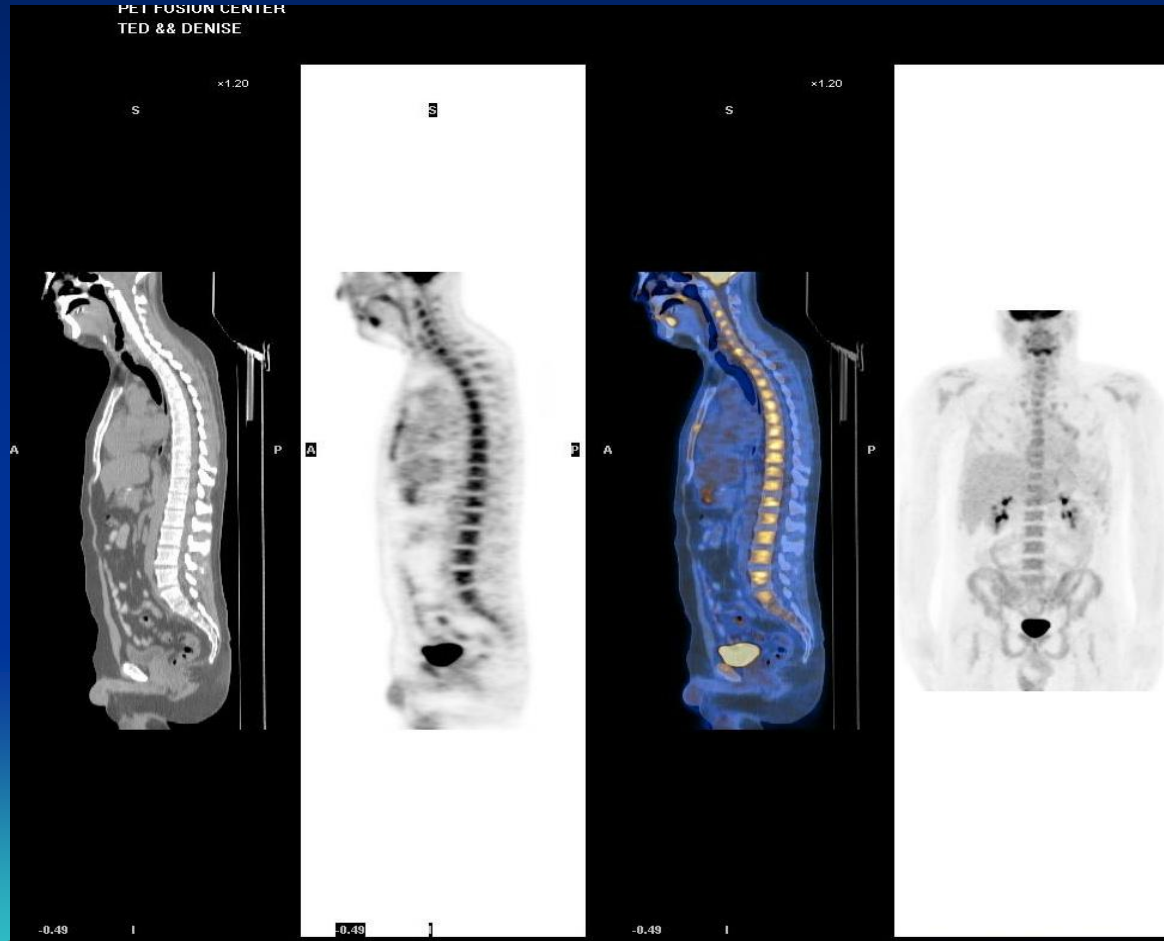
Artifactual, Muscular



Artifactual Fat

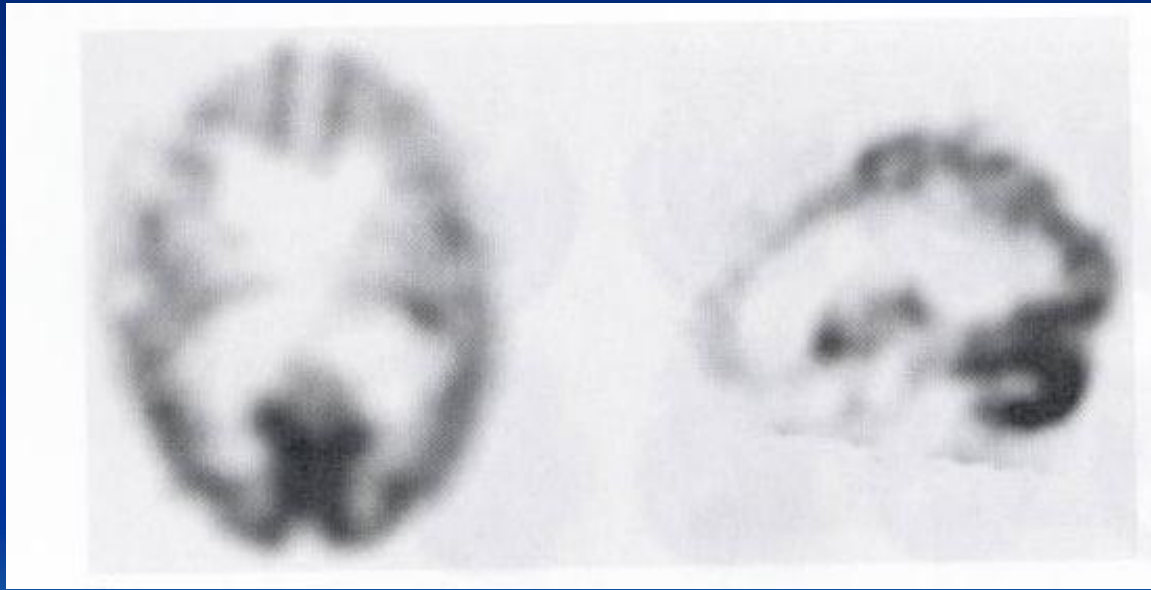


Increased marrow uptake due to chemotherapy

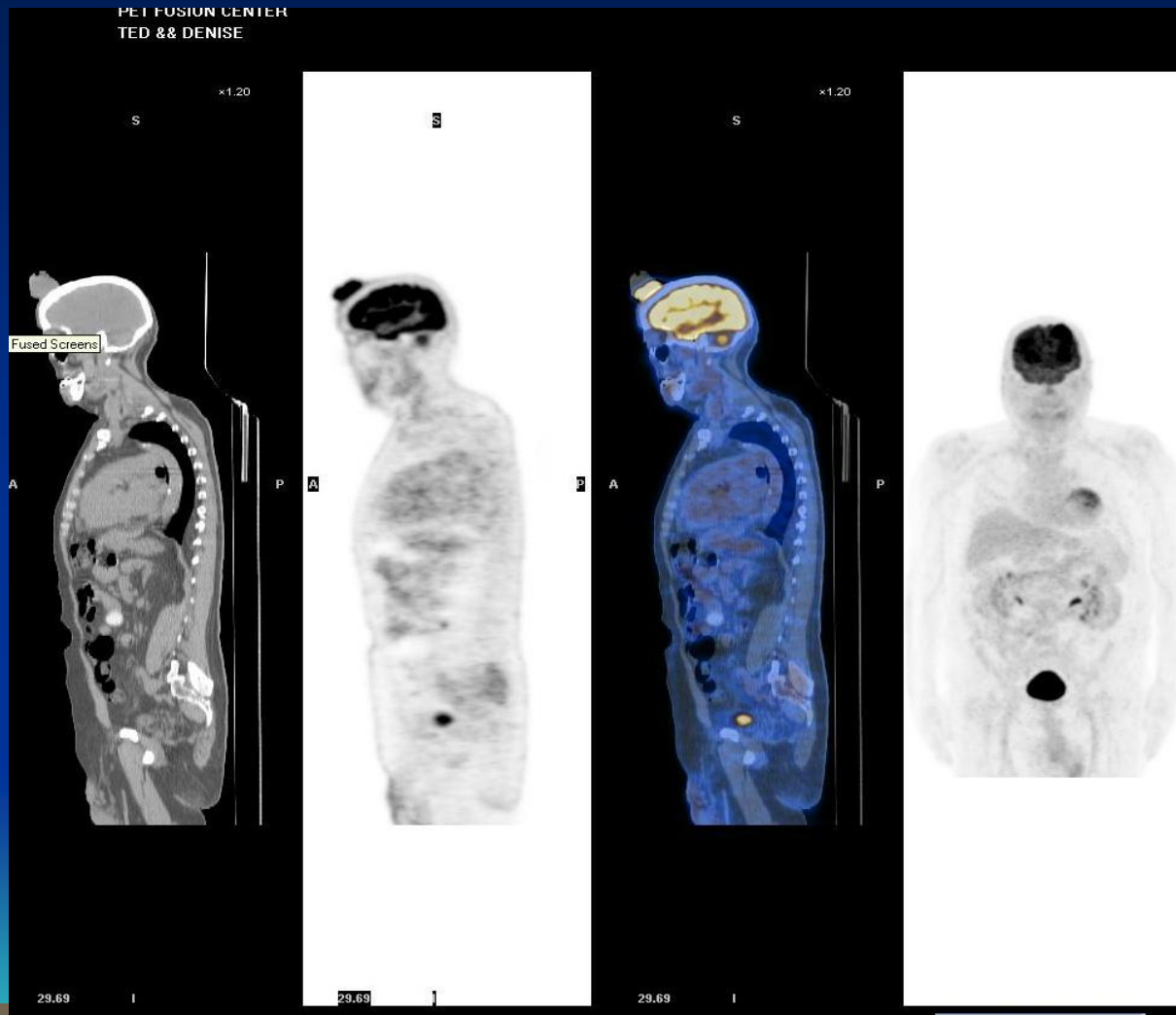


**G-CSF – postchemotherapy
Marrow stimulation**

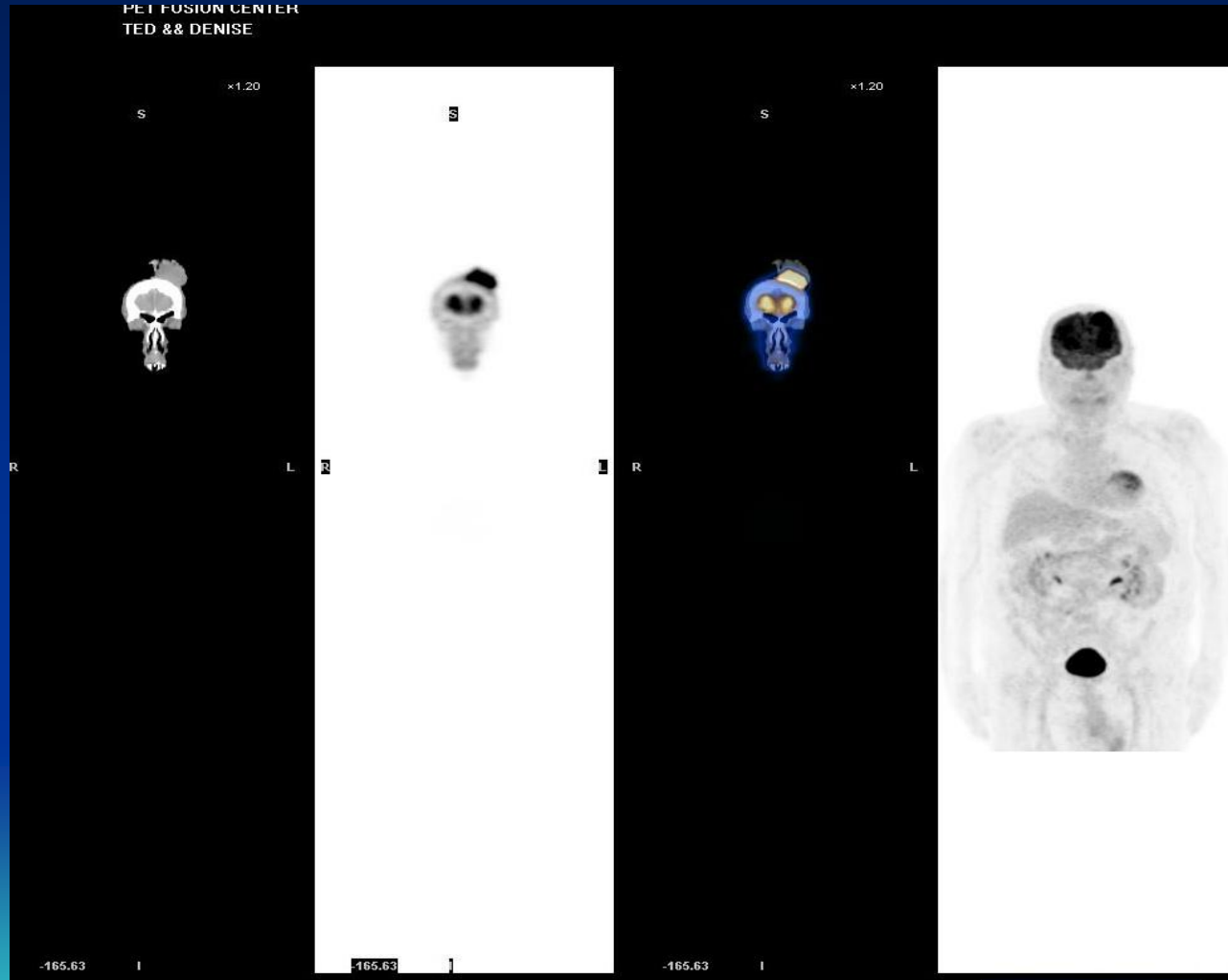
Pick's Disease



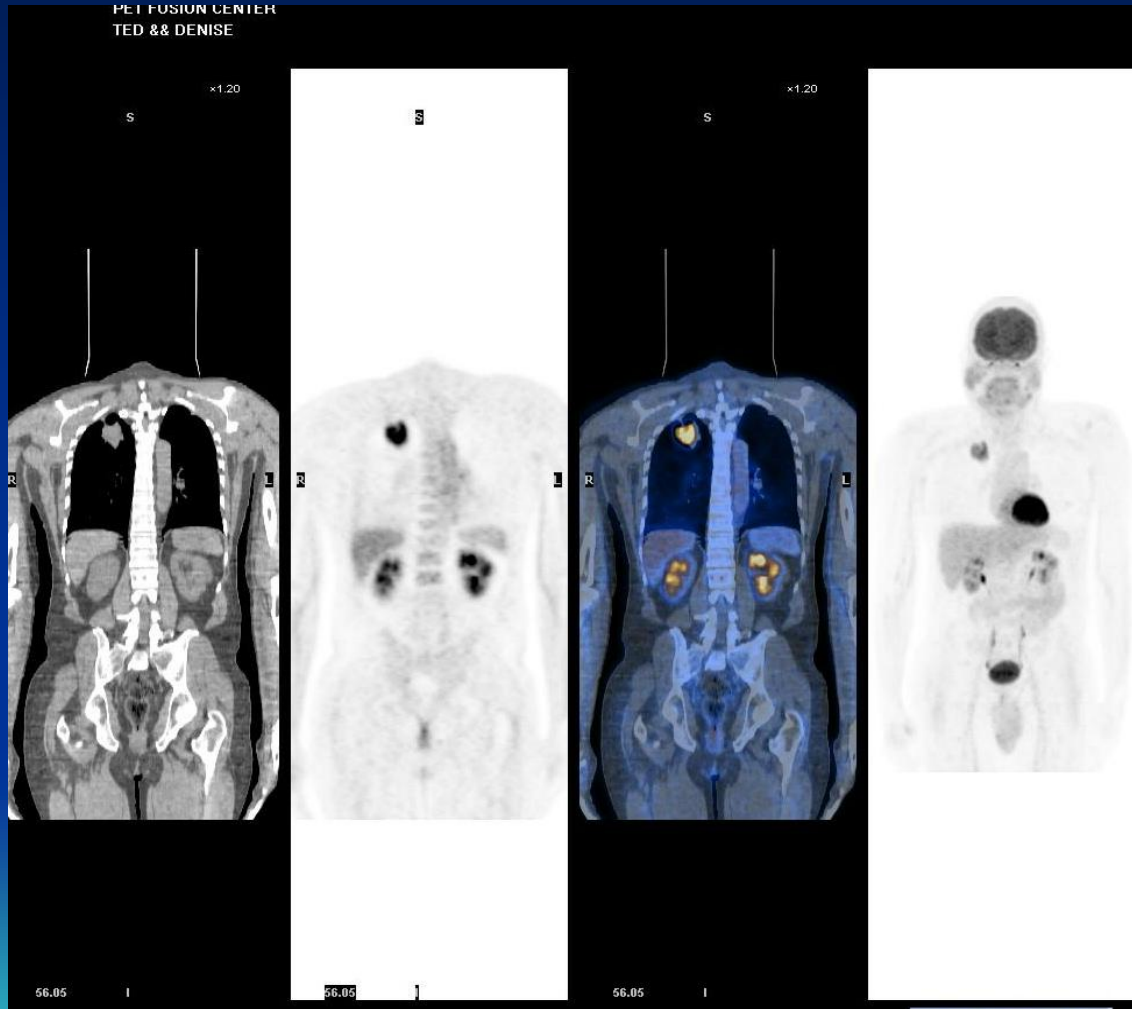
Melanoma



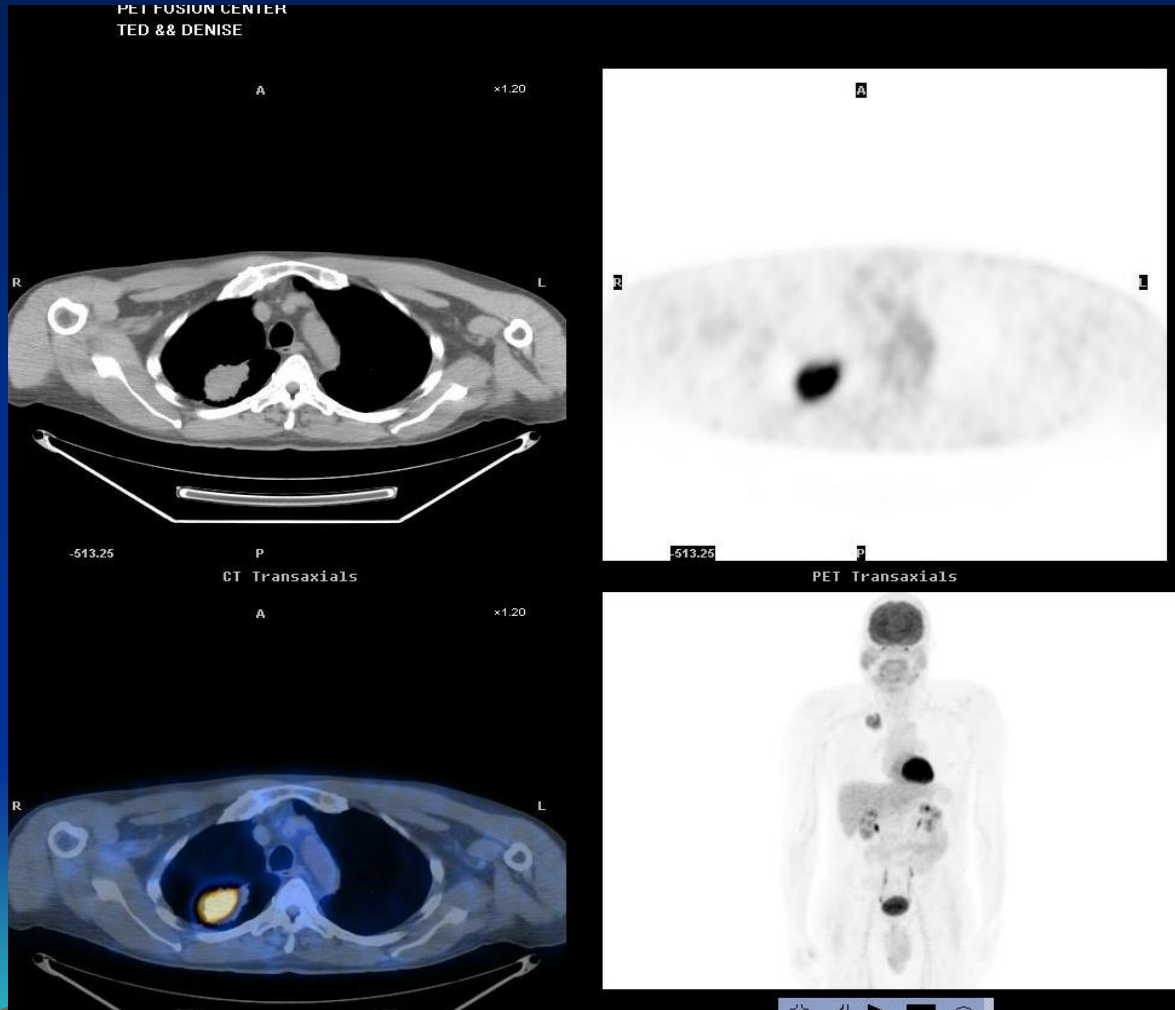
Melanoma



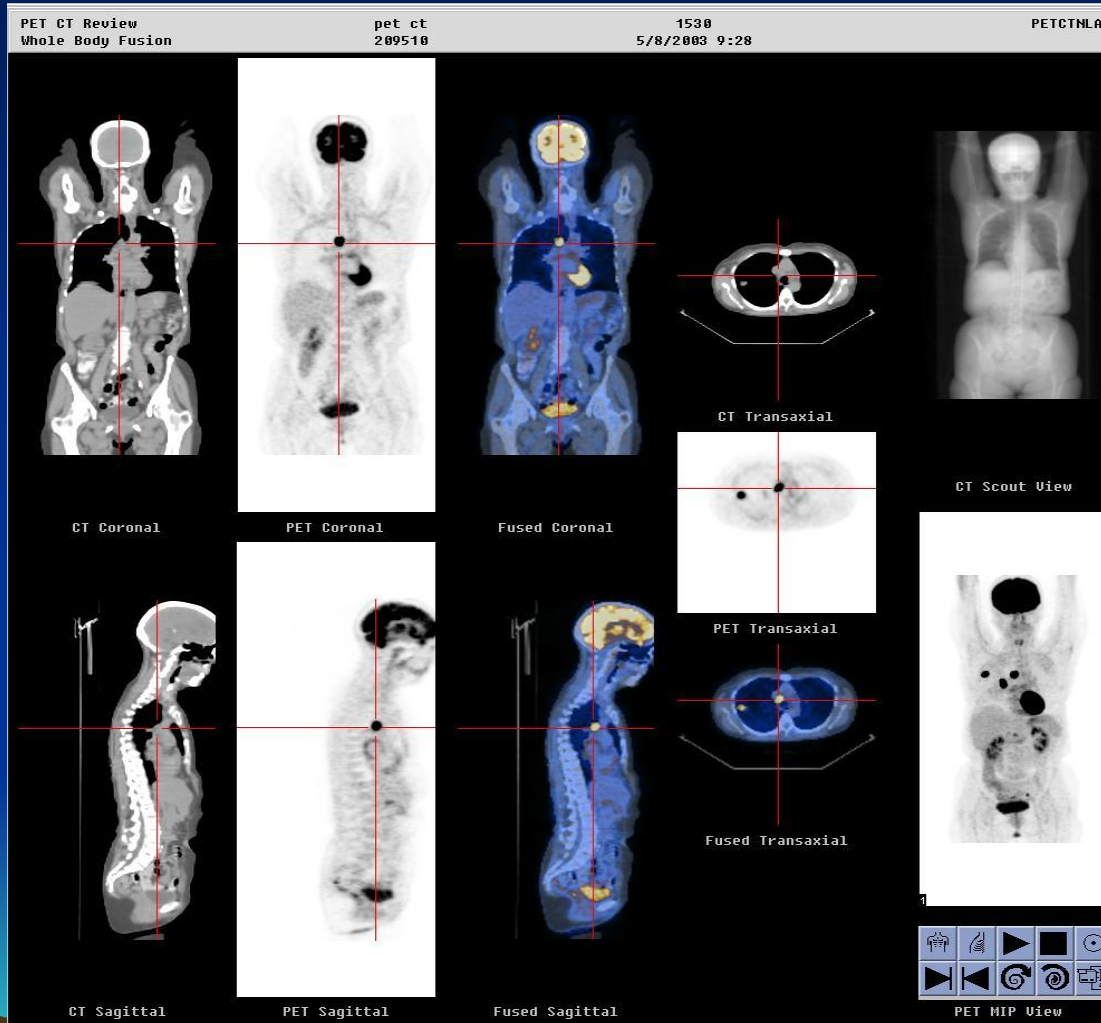
Lung Carcinoma



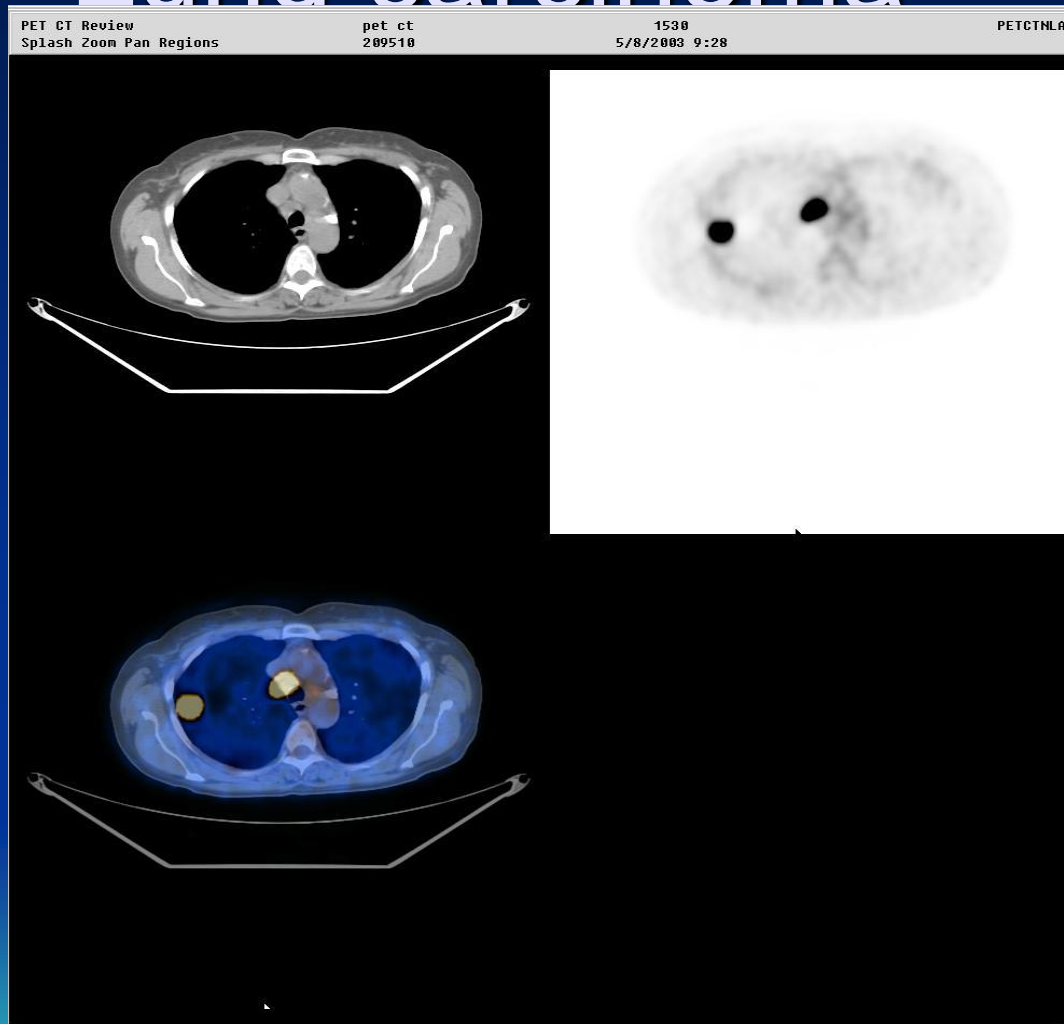
Lung Carcinoma



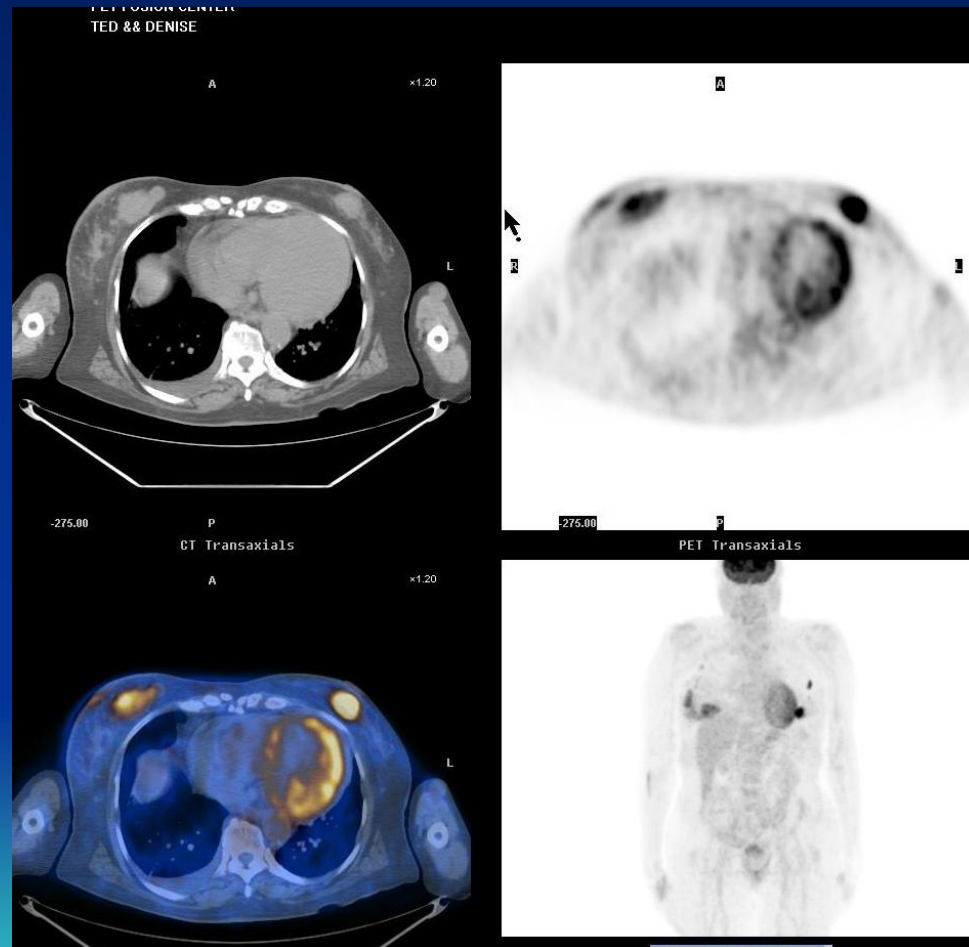
Lung cancer



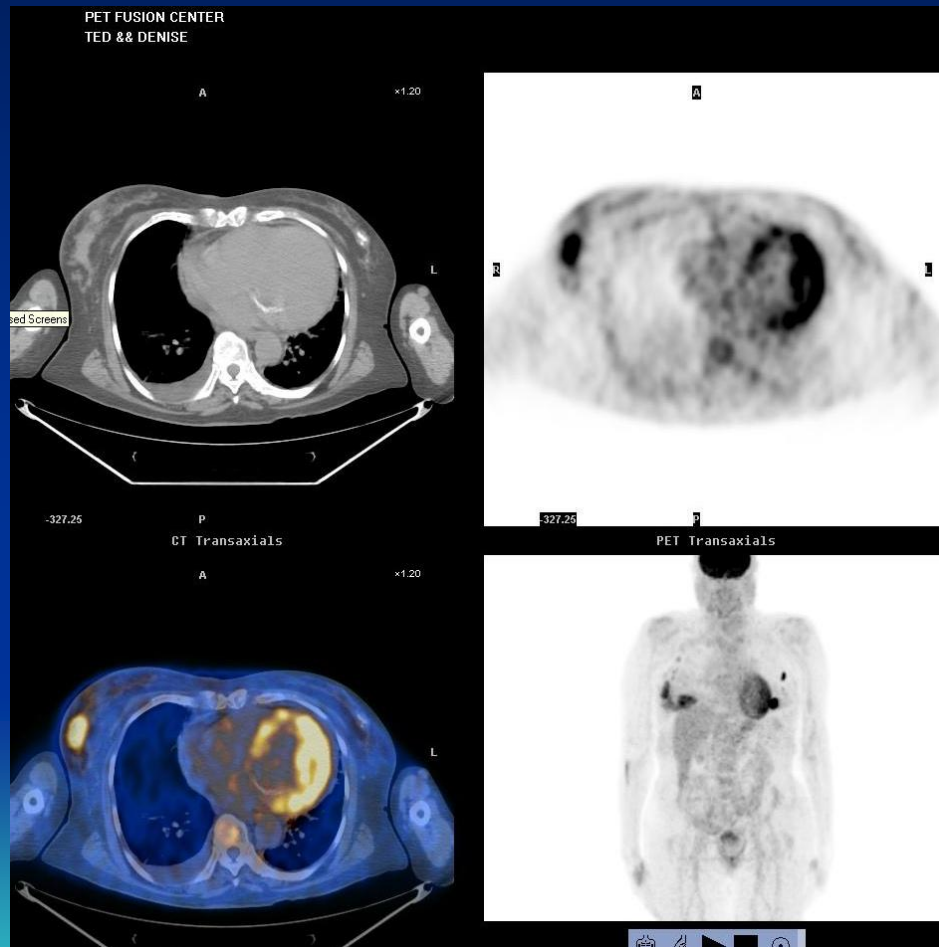
Lung carcinoma



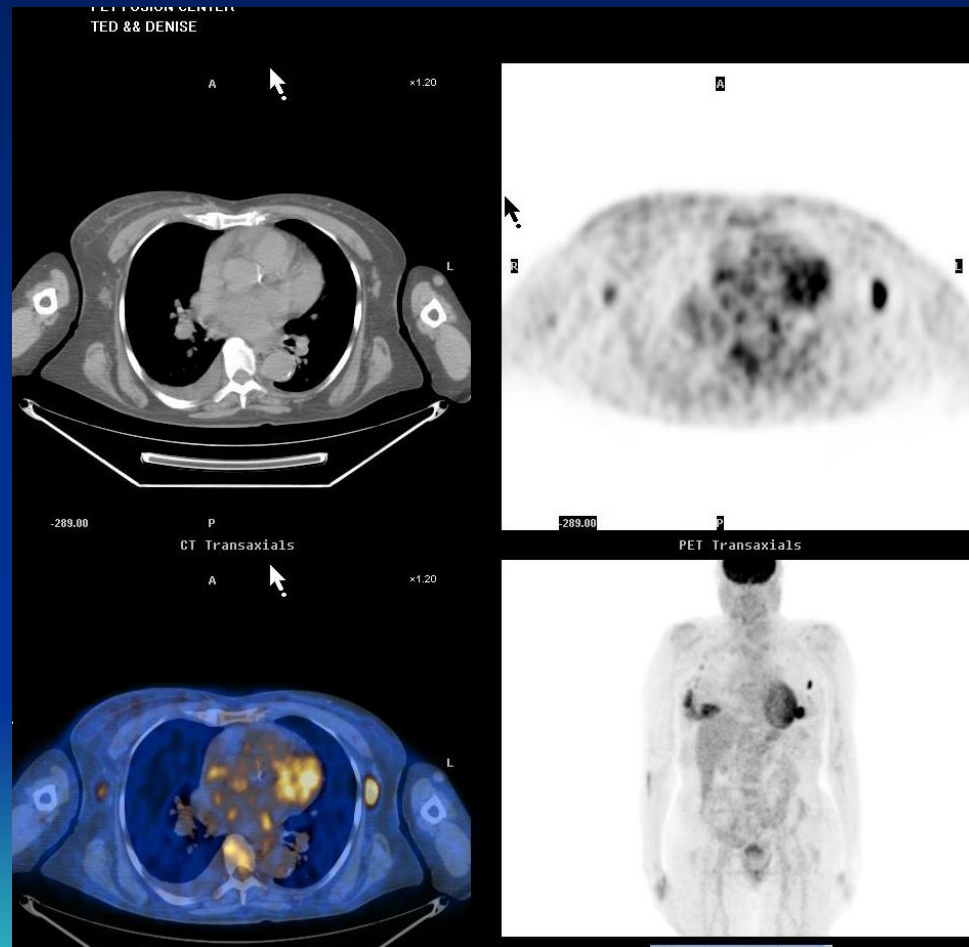
Breast carcinoma



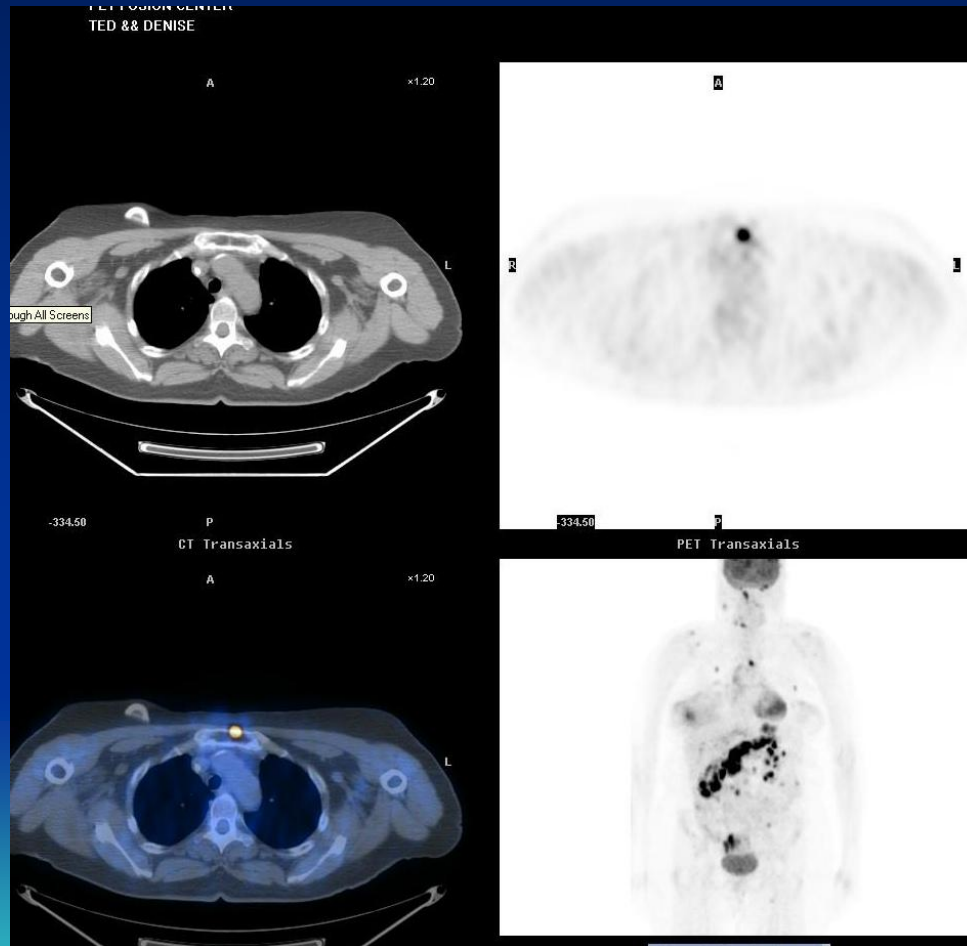
Breast carcinoma



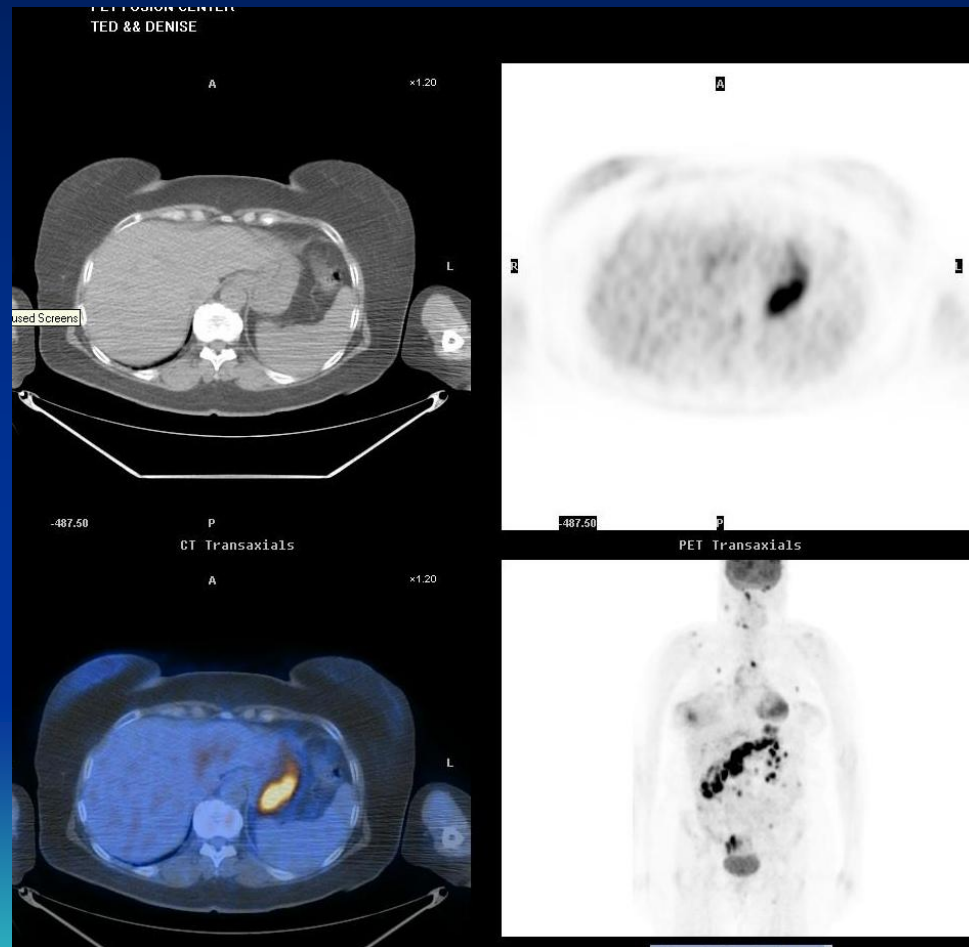
Breast carcinoma



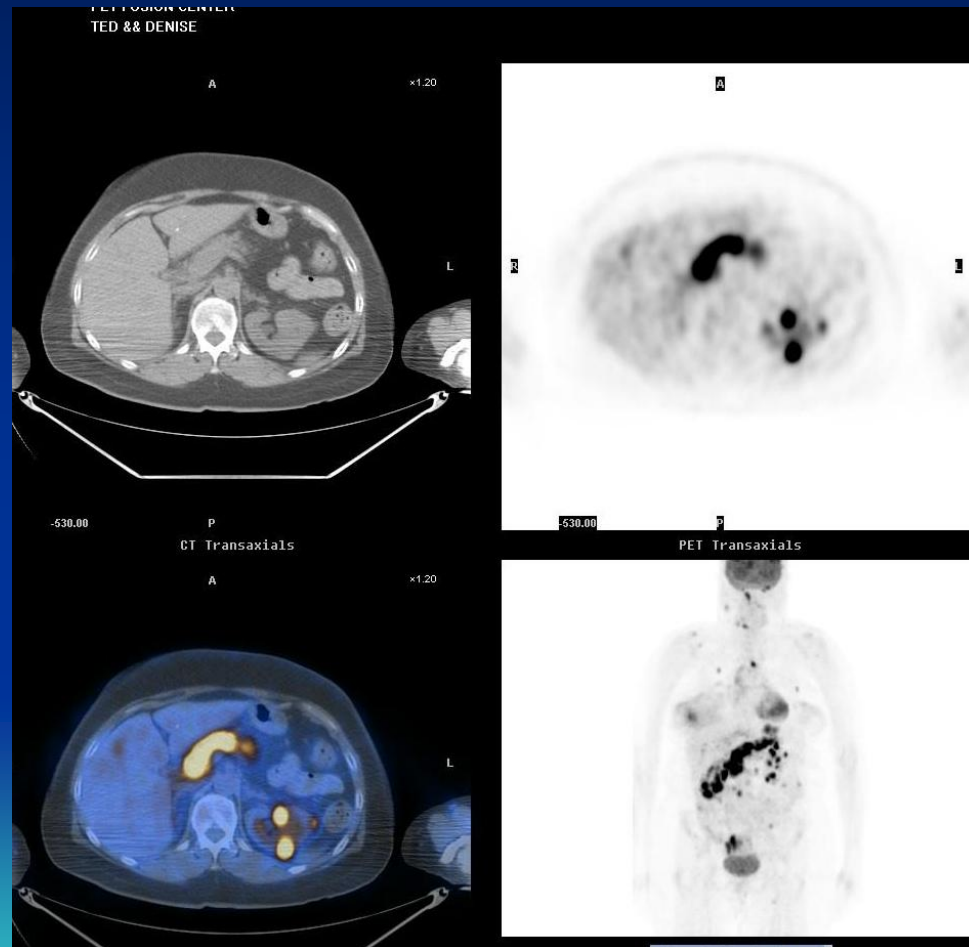
Lymphoma



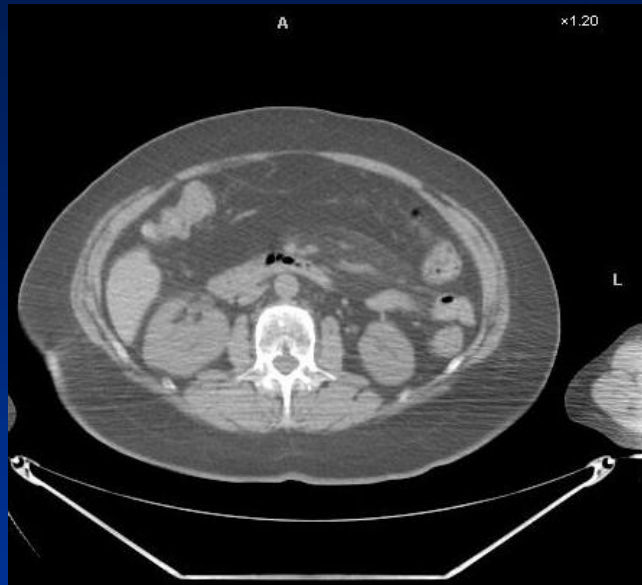Lymphoma



Lymphoma

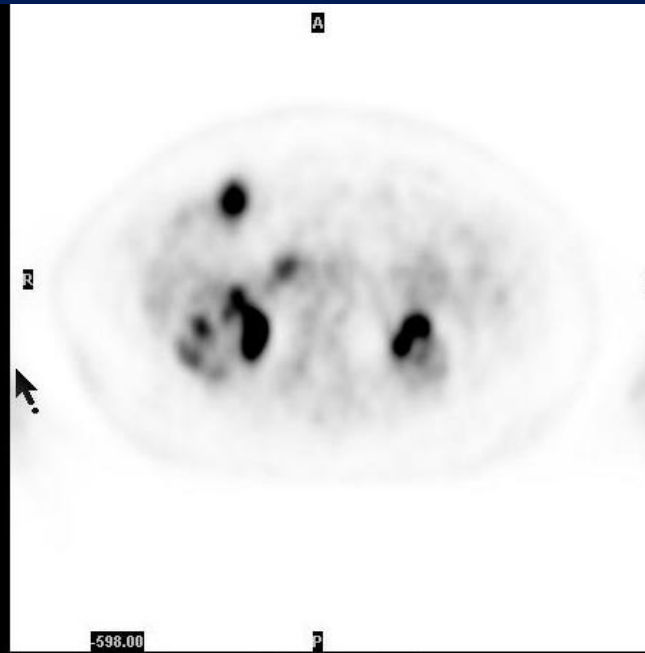
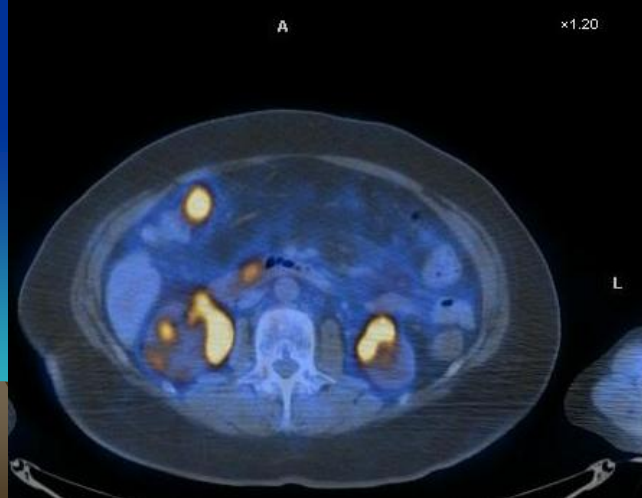


Lymphoma



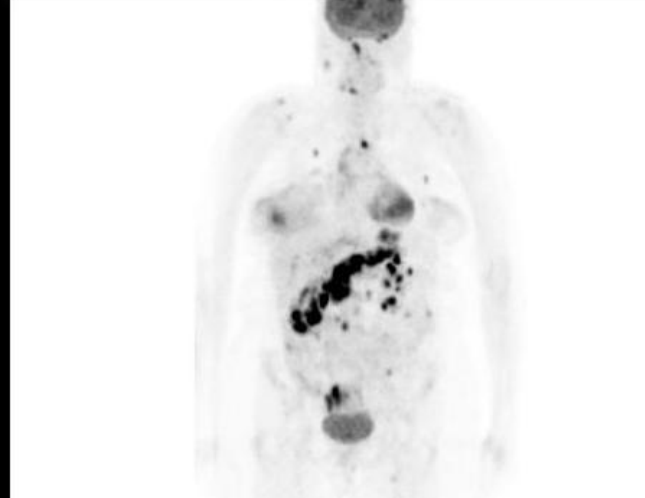
-598.00

P
CT Transaxials

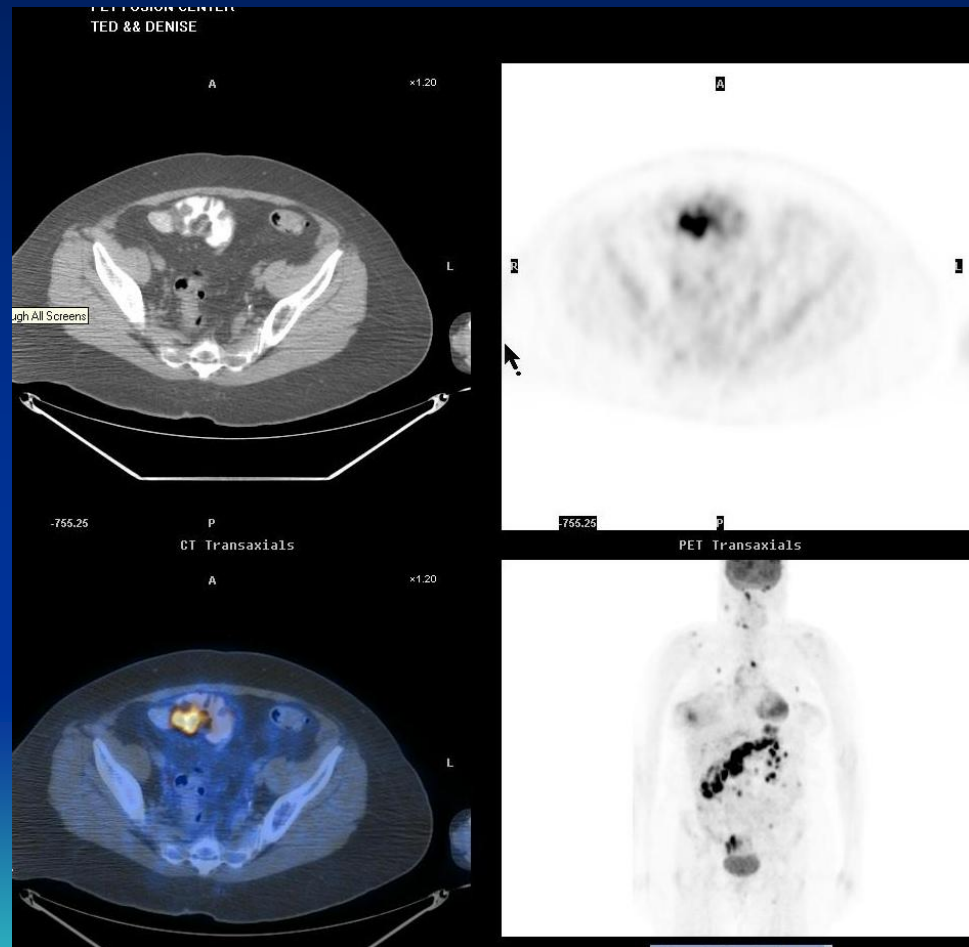


-598.00

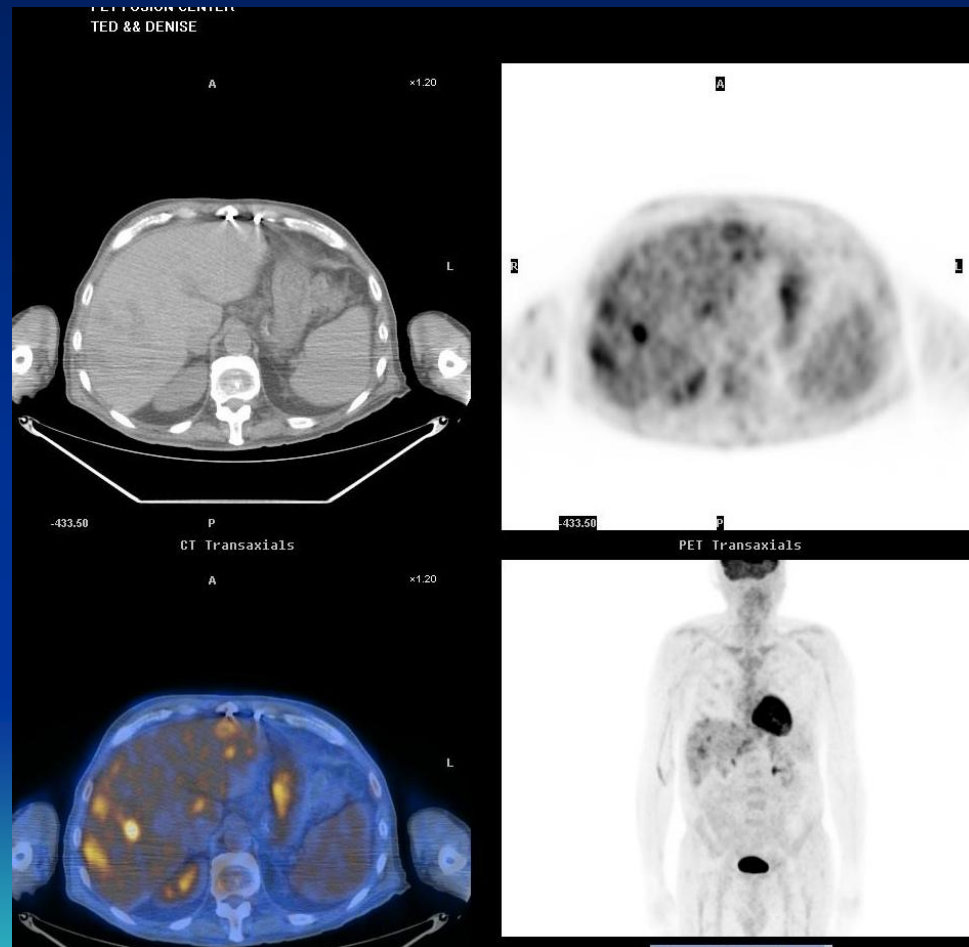
P
PET Transaxials



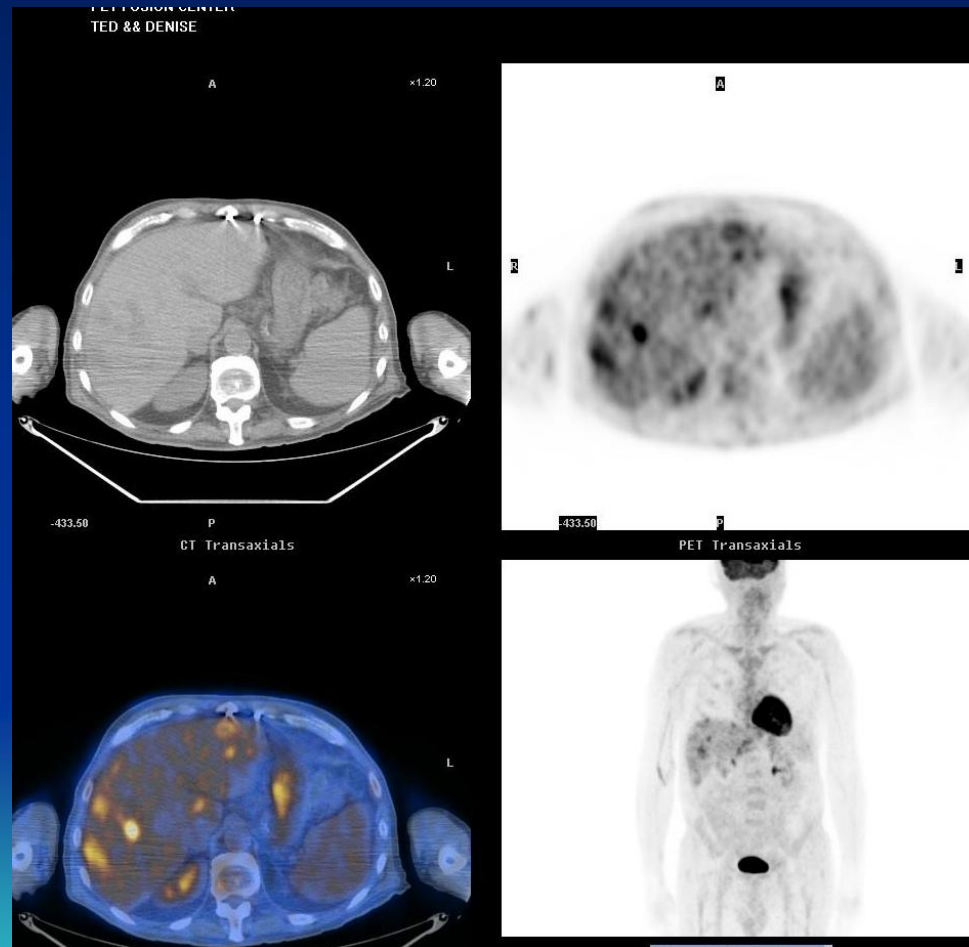
Lymphoma



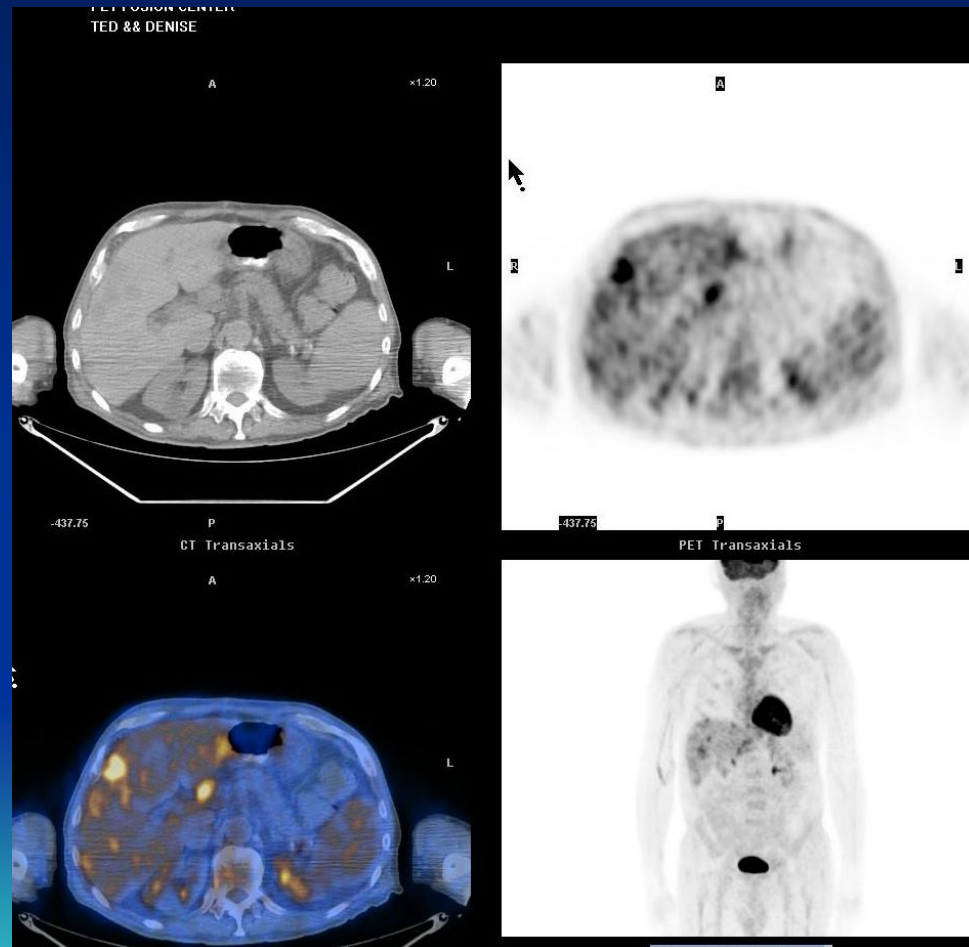
Liver Mets from Colon Ca



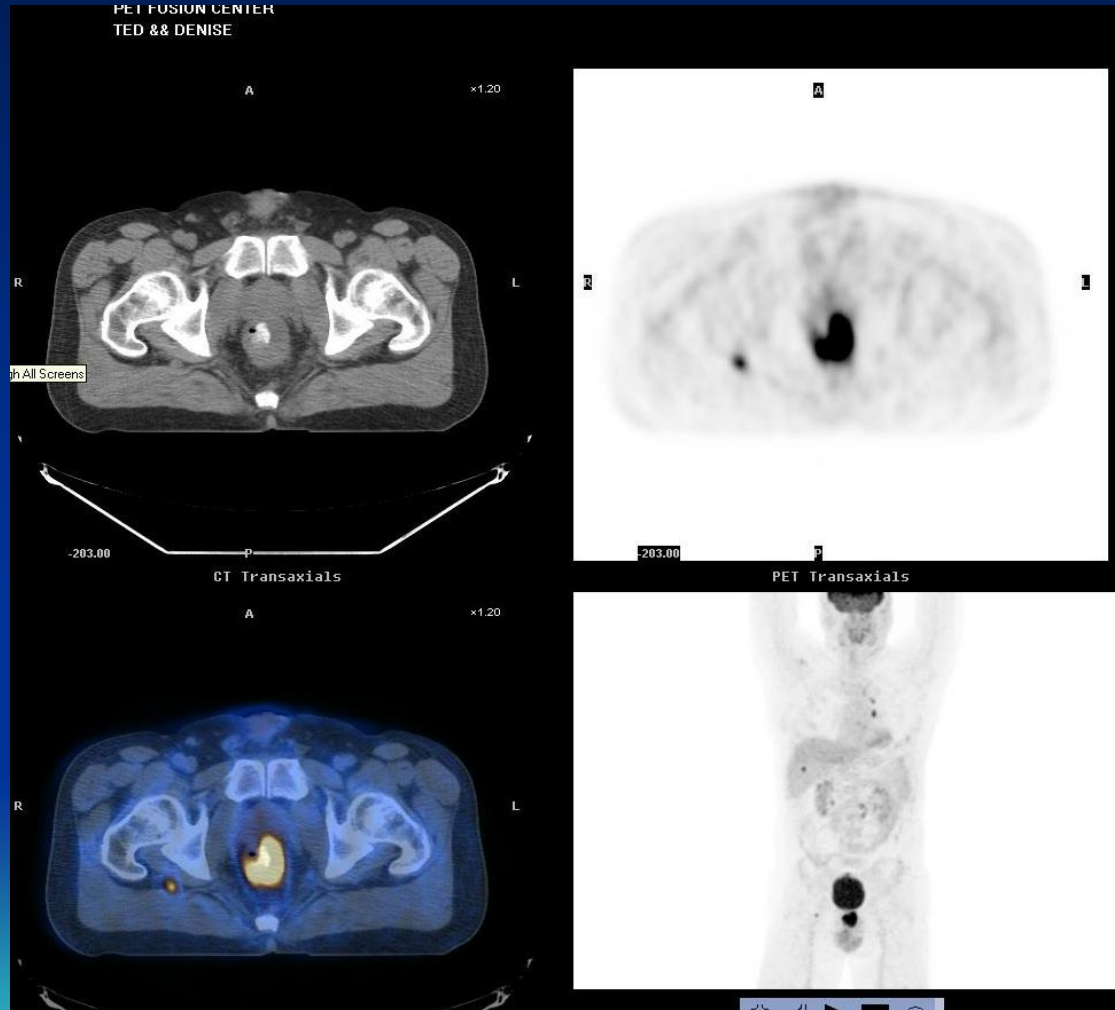
Liver Mets from Colon Ca



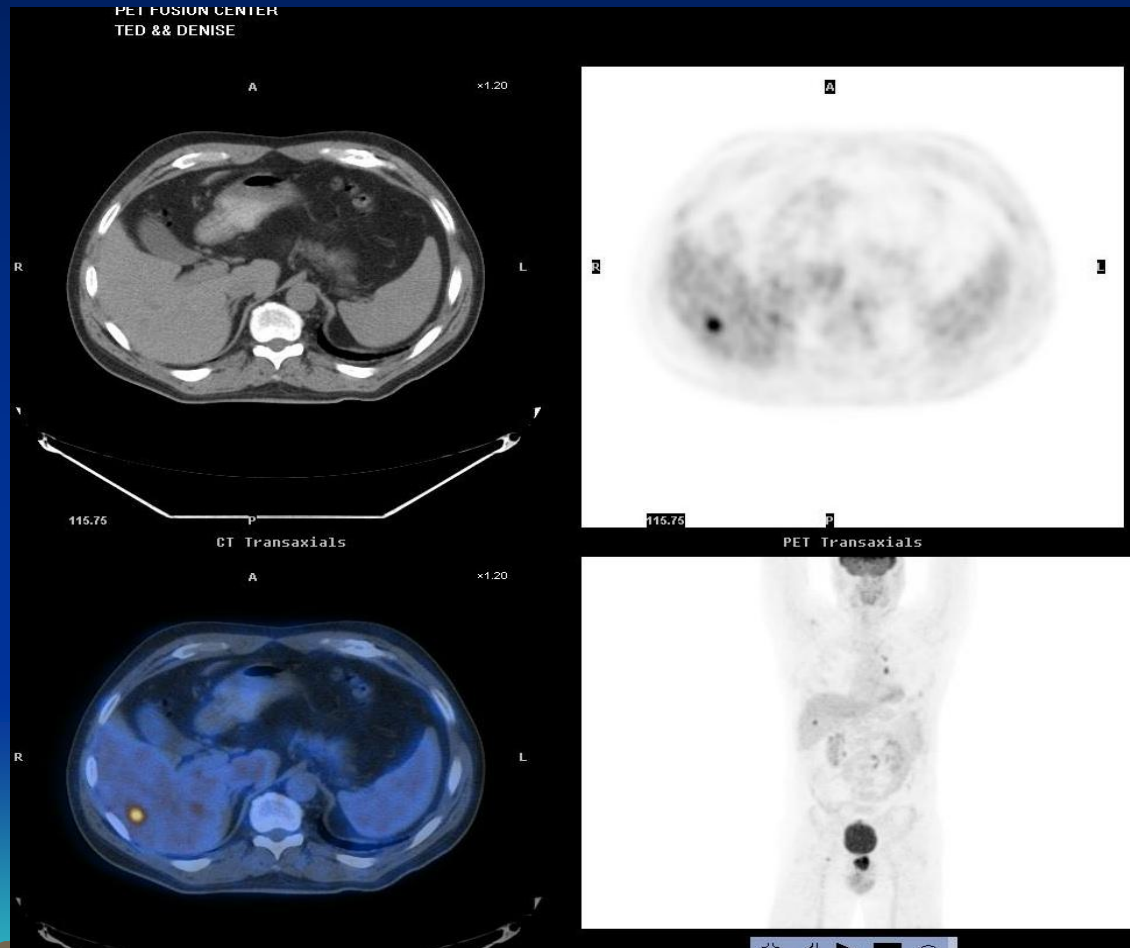
Liver Mets from Colon Ca



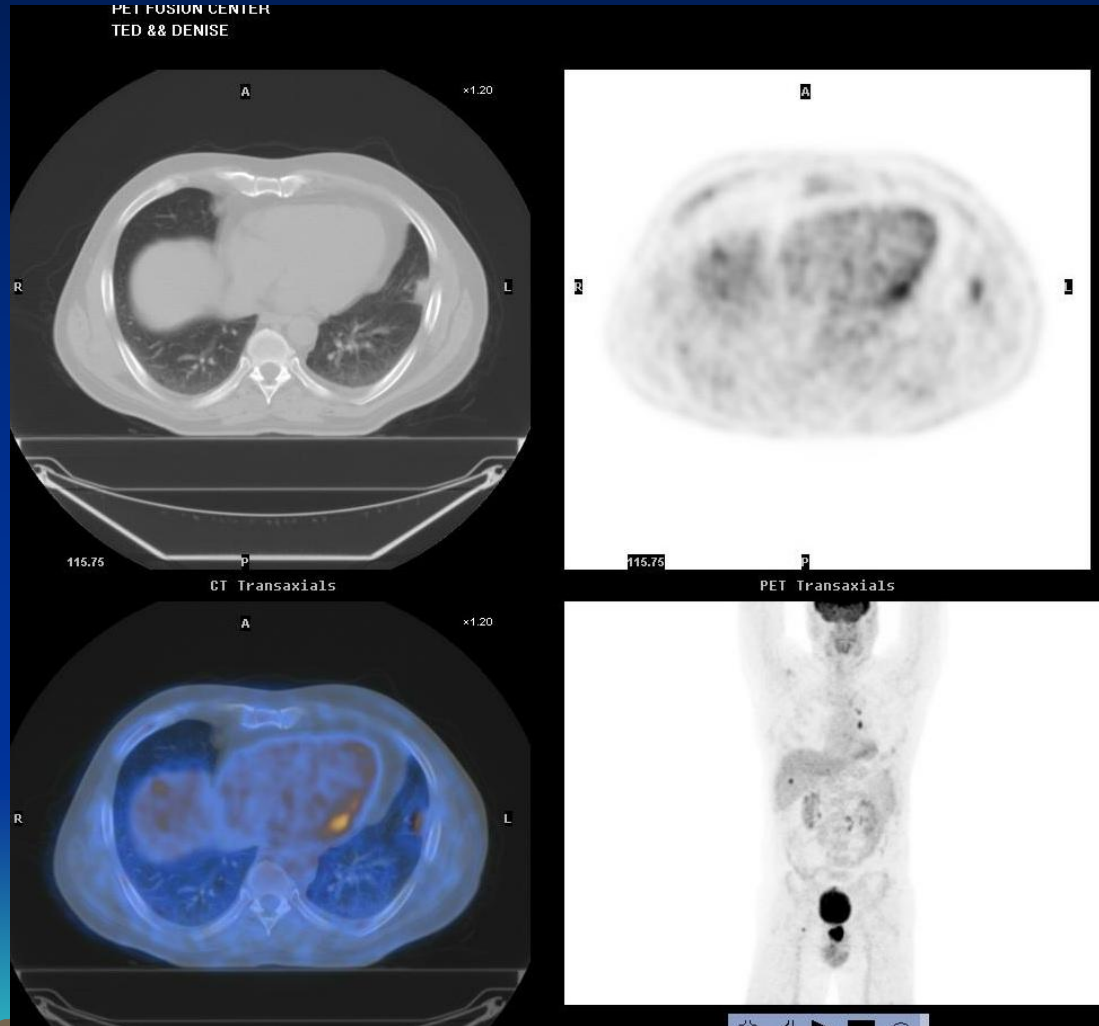
Rectal carcinoma



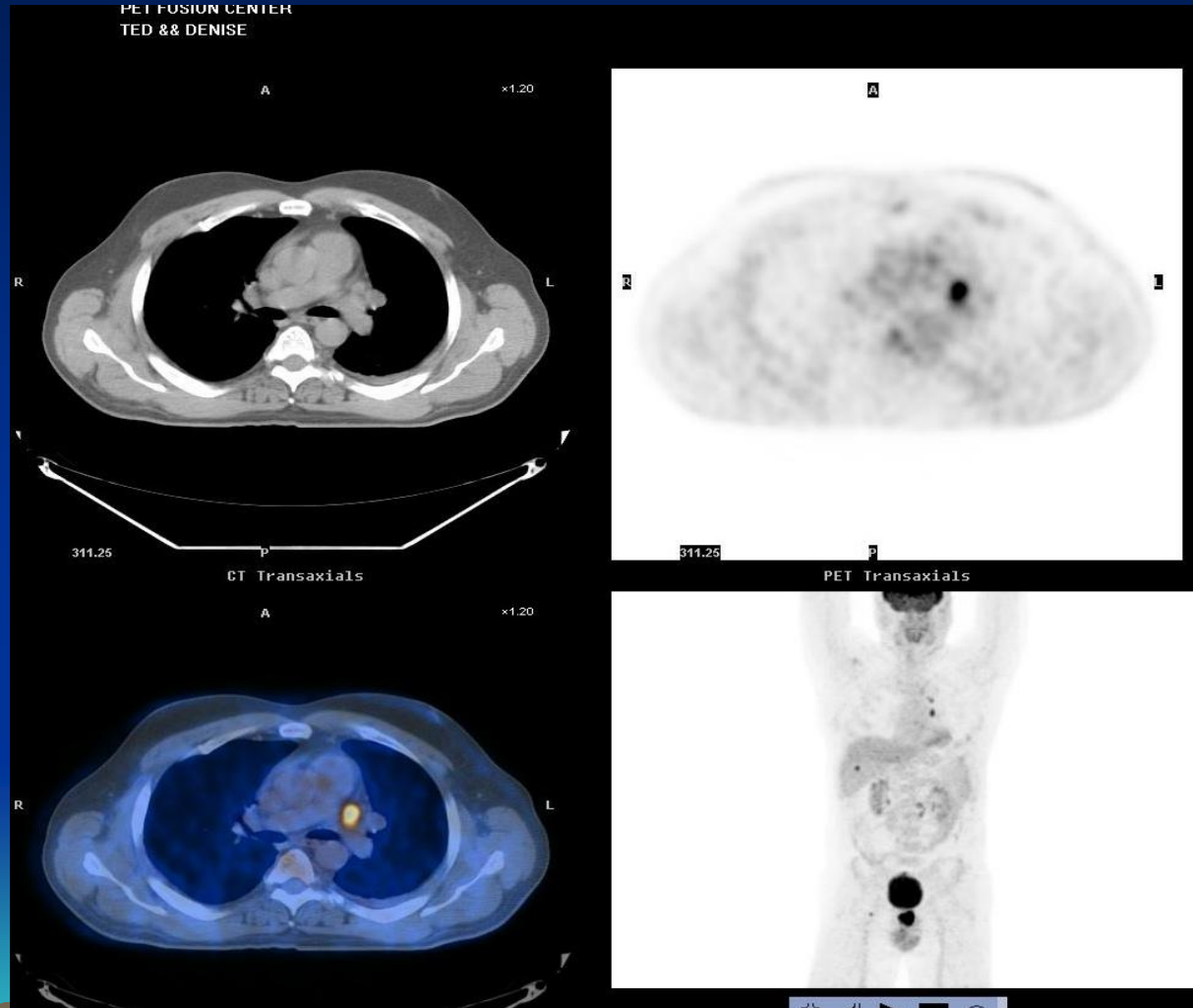
Rectal carcinoma



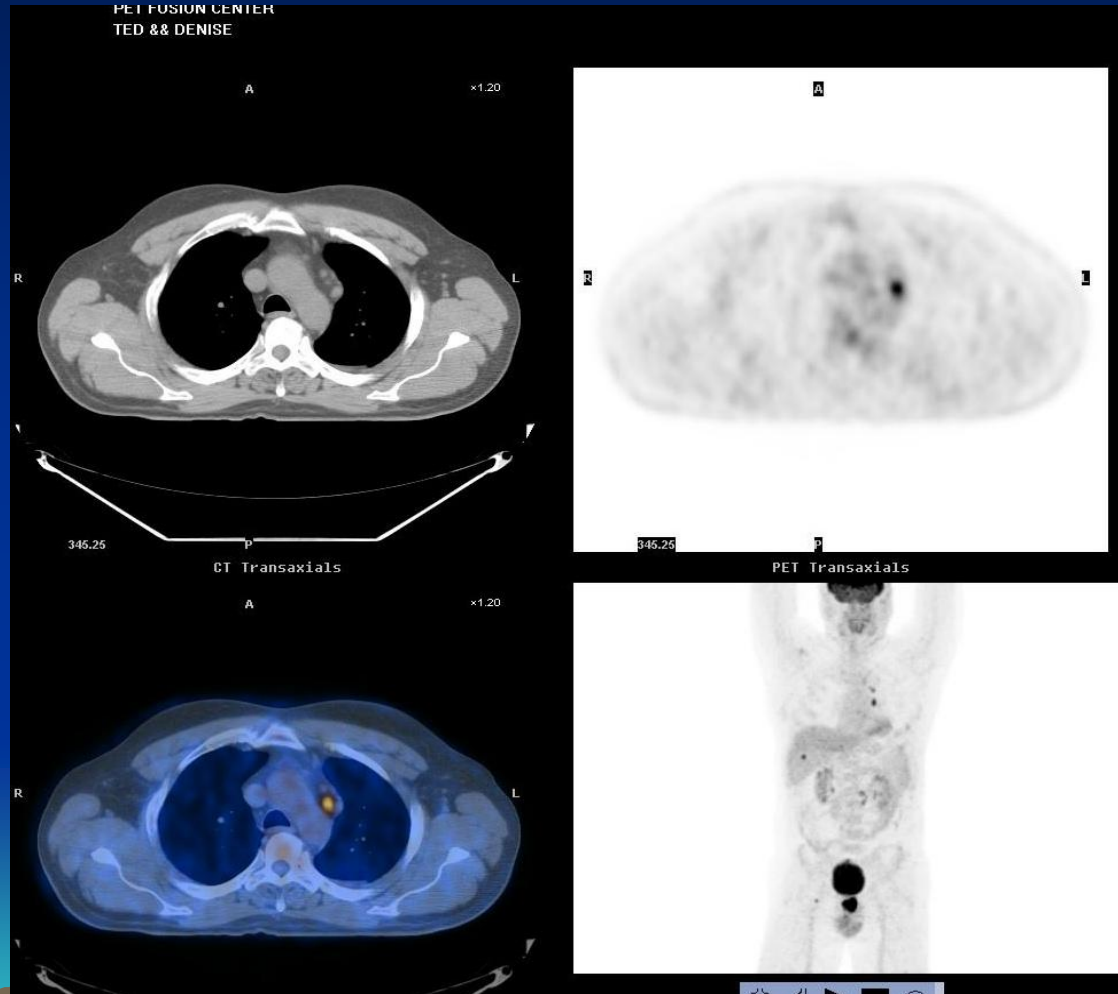
Rectal carcinoma



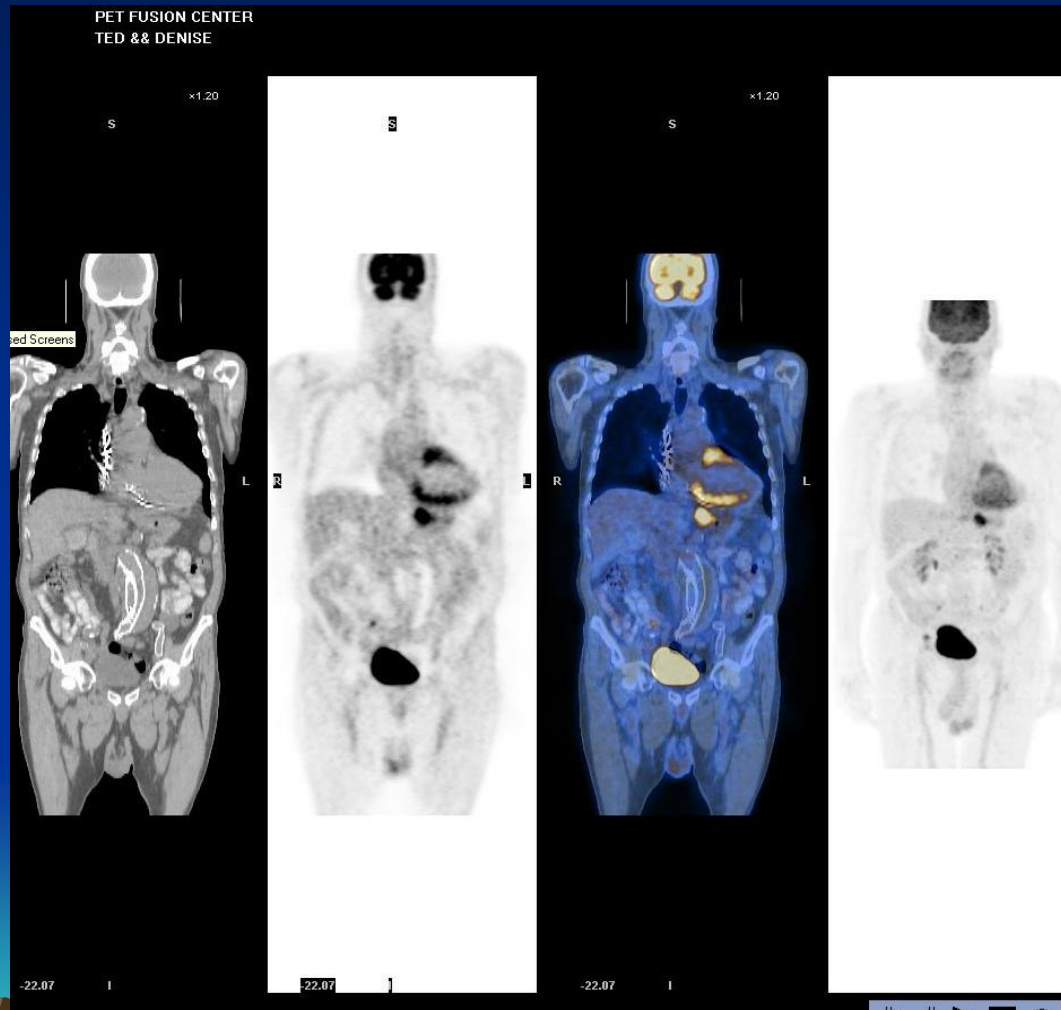
Rectal carcinoma



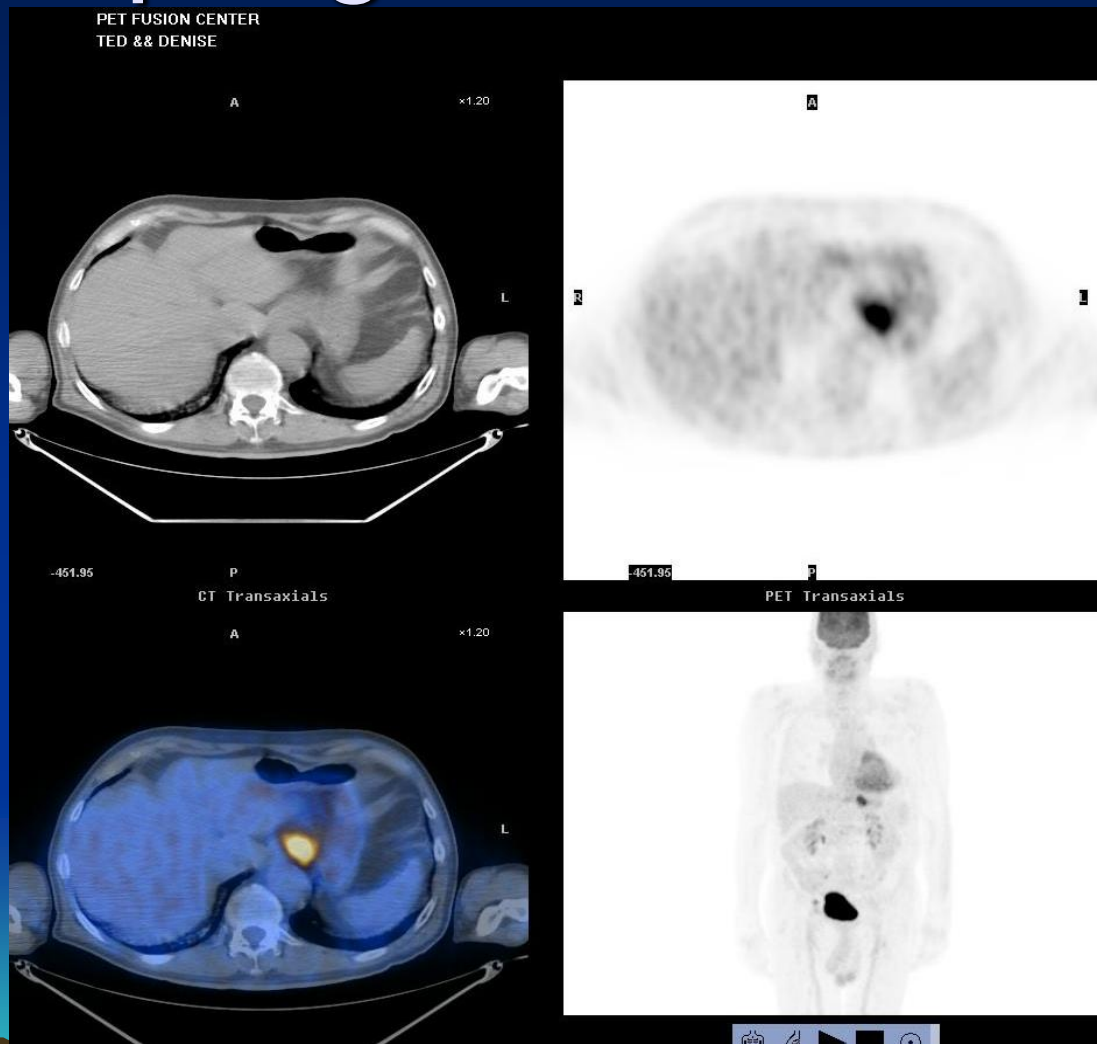
Rectal carcinoma



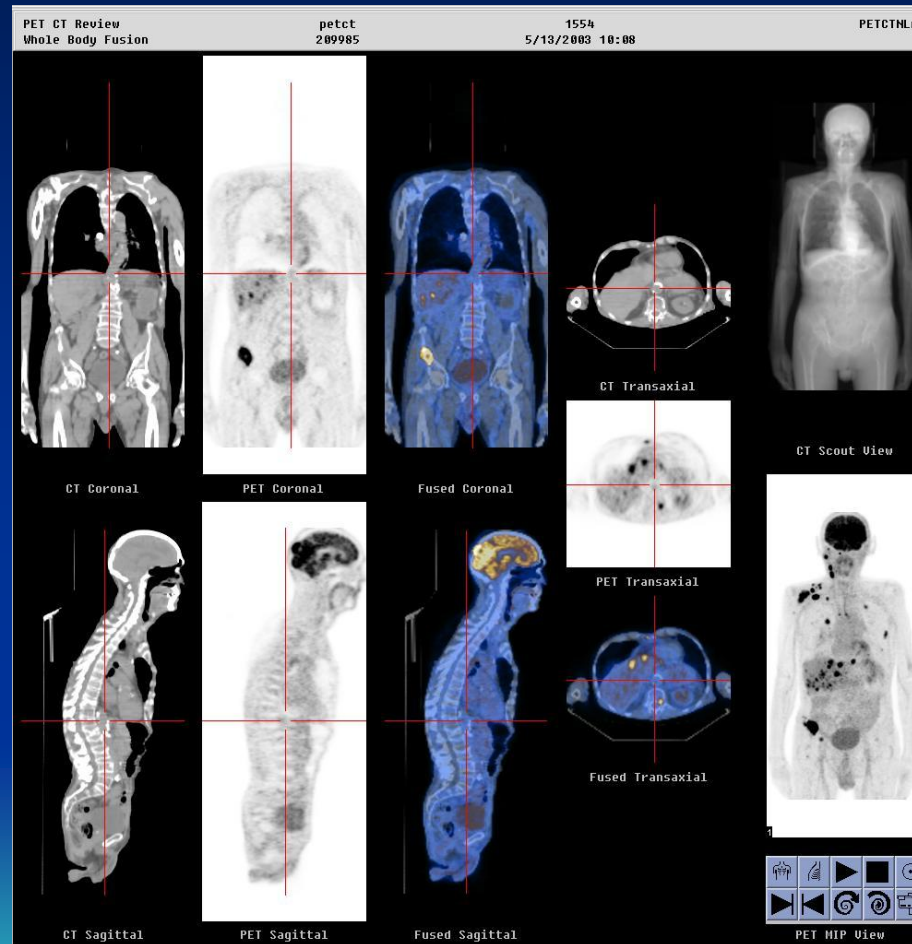
Esophageal carcinoma



Esophageal carcinoma



Diffuse Metastatic disease



Note

- Not all cancers have positive PET Scans
- Not all positive PET scans are cancers



