

Candida Esophagitis

Amanda Ritchie MD, Michael Millet MD, Fred Lopez MD
Department of Internal Medicine
LSU Health Sciences Center, New Orleans, LA

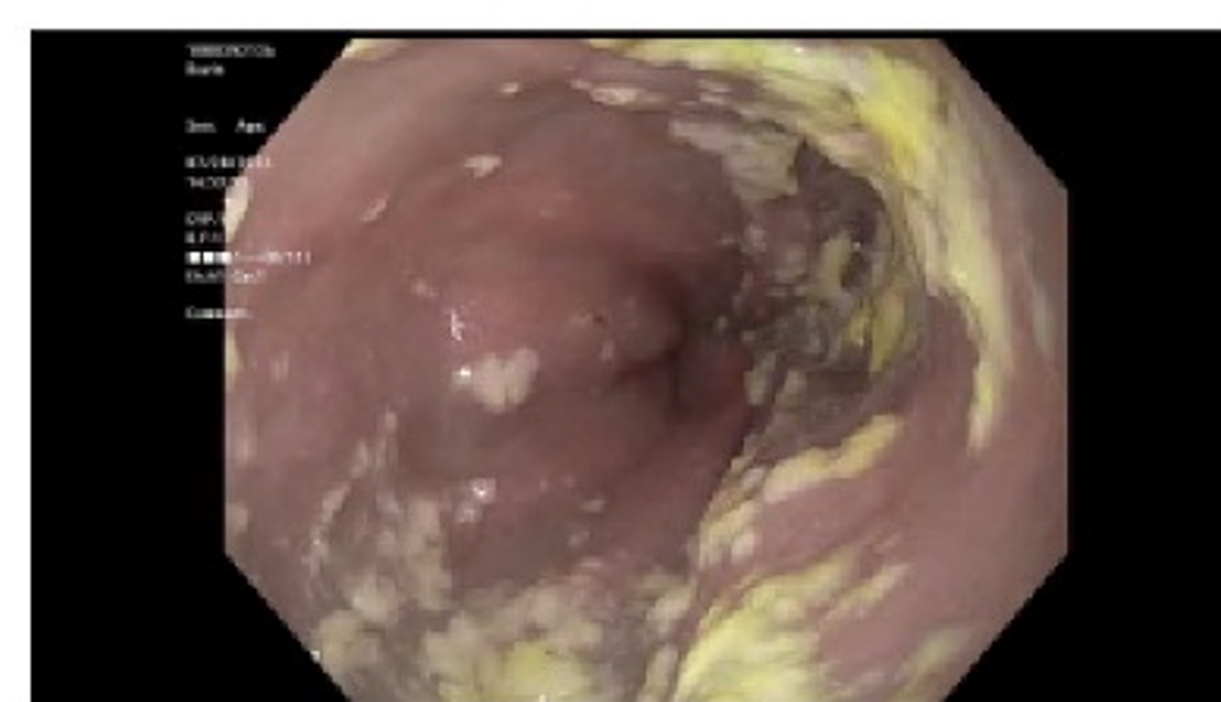Introduction

- ❖ Candida esophagitis is the most common cause of infectious esophagitis, responsible for 88% of all cases, followed by herpes simplex virus (10%) and cytomegalovirus (2%)
- ❖ Candida can be normal oral flora
- ❖ Many patients are asymptomatic, however symptoms can also range from dysphagia, odynophagia or even retrosternal chest pain

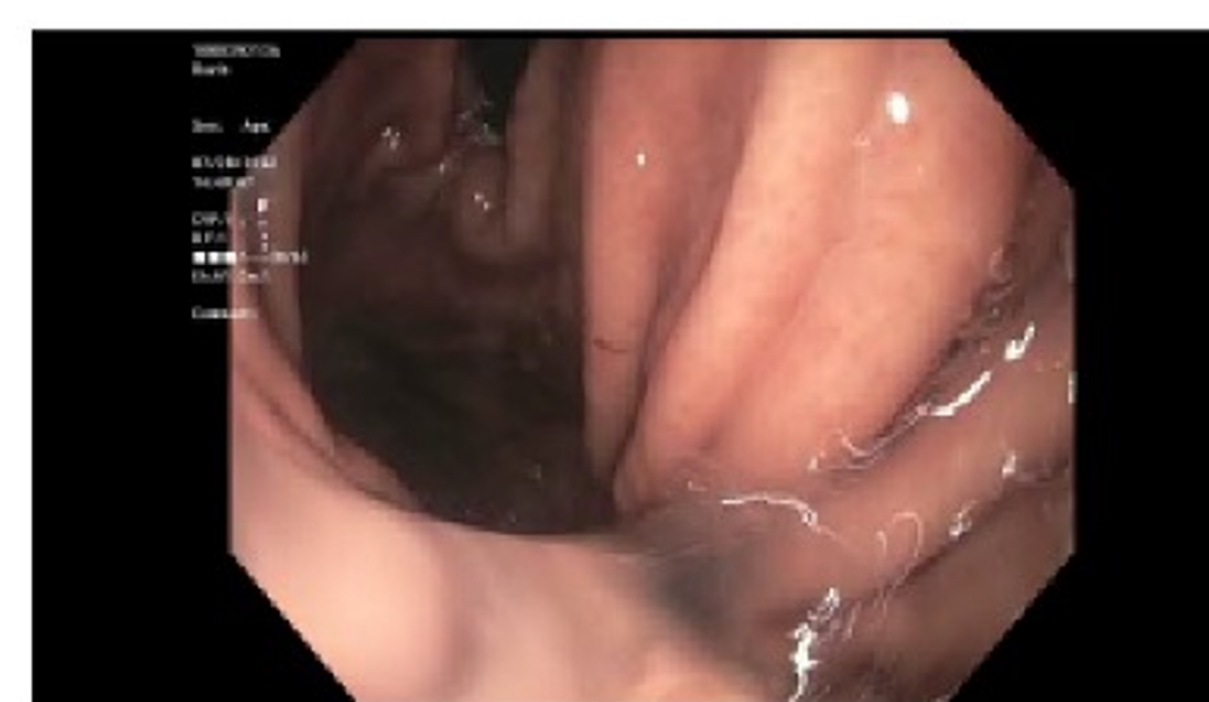Case Presentation

- ❖ A 45-year-old male with past medical history of hypertension, hyperlipidemia, human immunodeficiency virus (HIV) and intravenous drug use (IVDU) presented to the Emergency Department (ED) with 3 days of substernal chest pain
- ❖ At triage, his EKG was normal sinus with ST depression in the inferior leads with T wave inversion in lead III and aVF, however EKG six hours later was normal sinus with no evidence of ischemia
- ❖ High sensitivity troponin was 4 on arrival and when repeated (normal 0-20)
- ❖ Initial labs revealed a leukocytosis with no left shift, and were otherwise unremarkable, including BNP, CK, HbA1c, and urinalysis
- ❖ Physical exam was unremarkable, chest pain was not reproducible, and there were no pharyngeal erythema or tonsillar exudates
- ❖ He failed to improve following a GI cocktail and pepcid
- ❖ On further questioning, he described pain in the center of his chest, which was worse with swallowing especially with liquids, and that he could feel the food passing in the center of his chest
- ❖ In the ER, the patient was treated for suspected Acute Coronary Syndrome (ACS) and received aspirin 324 mg

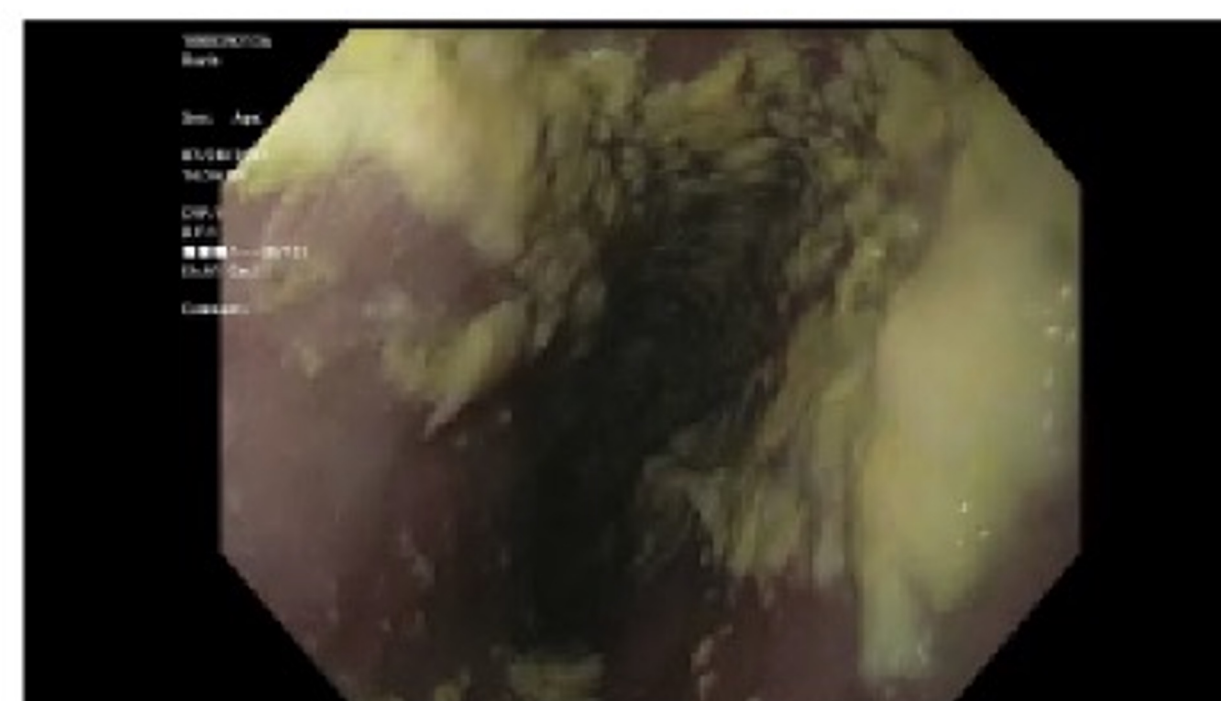Images



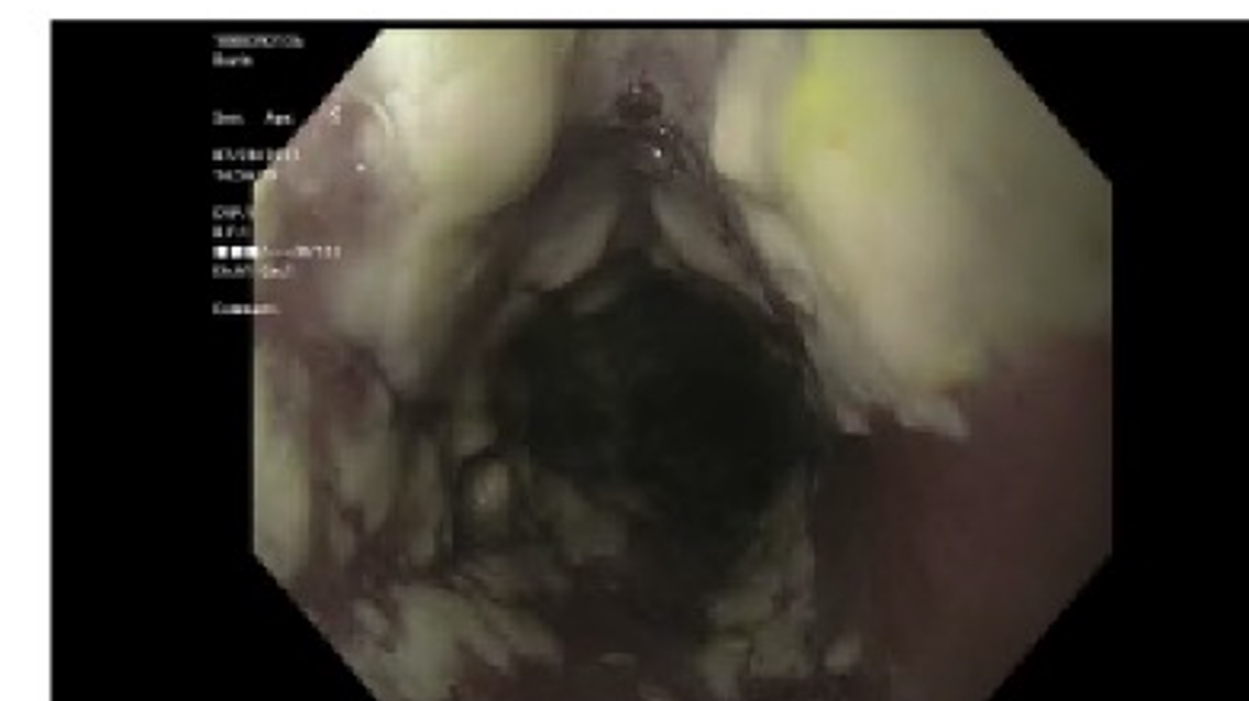1 Lower Third of the Esophagus



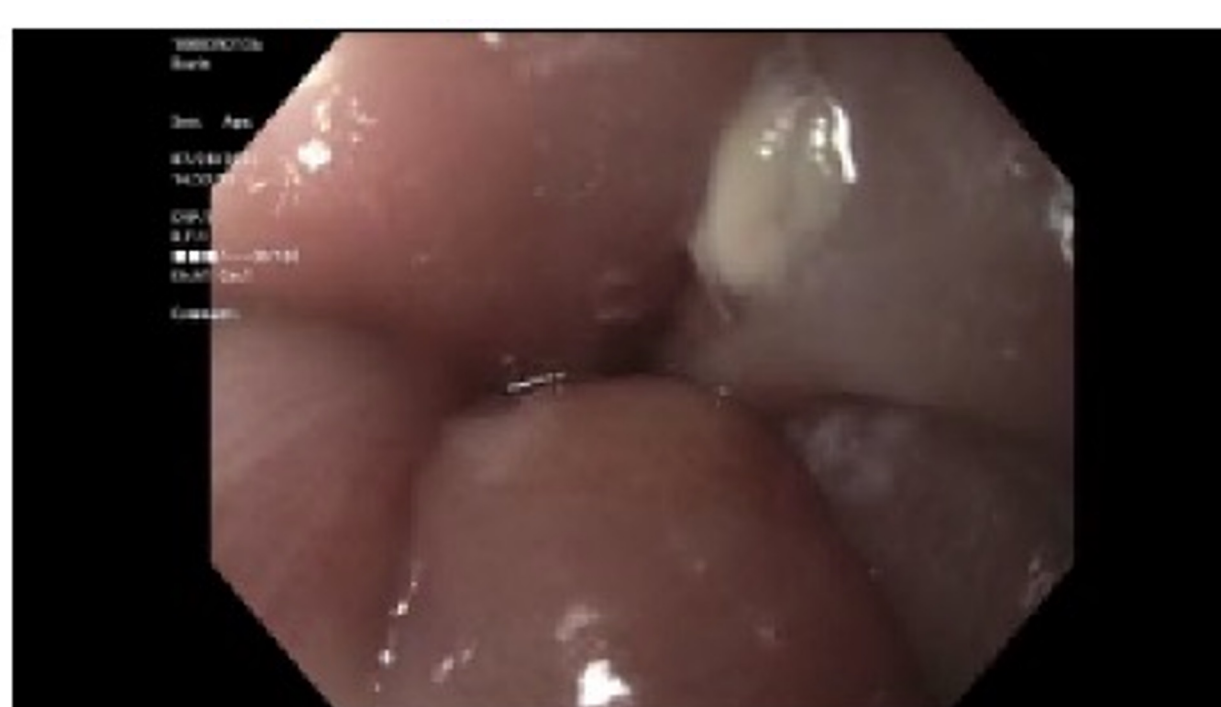
2 Gastric Body



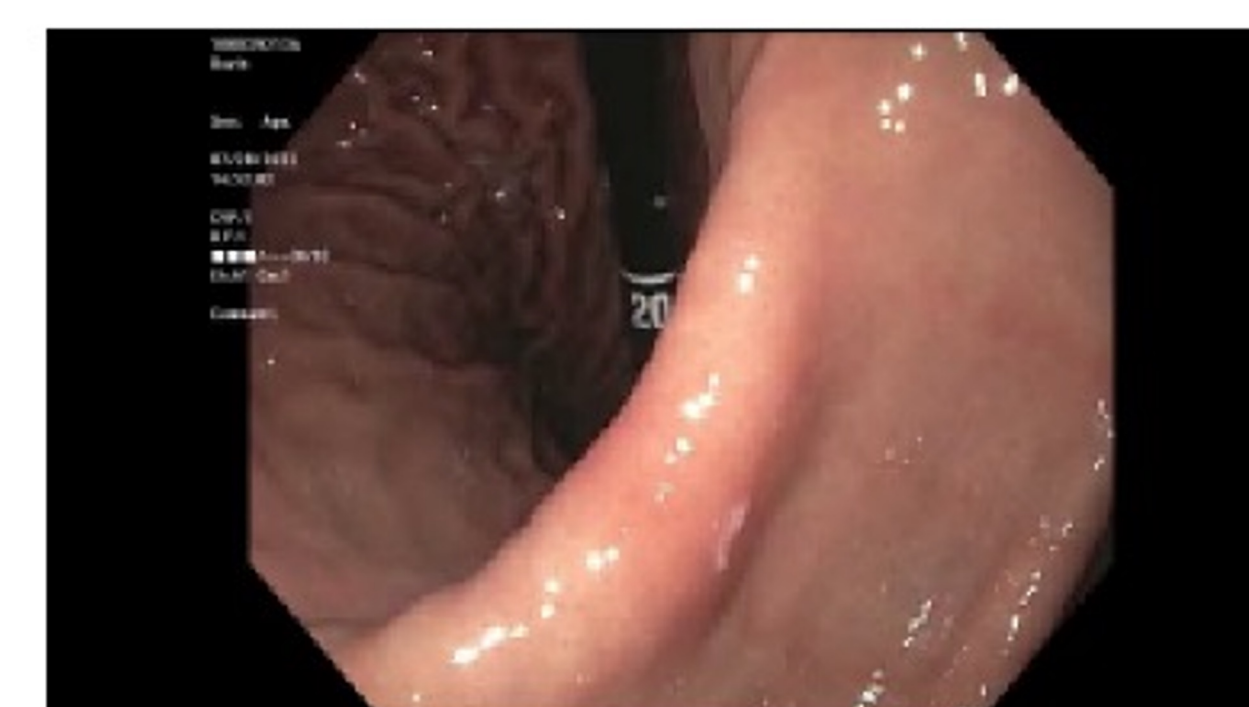4 Lower Third of the Esophagus



5 Middle Third of the Esophagus



6 Gastroesophageal Junction



7 Incisura of the Stomach

Fig. - Photographs taken during esophagogastroduodenoscopy, including the lower and middle third of the esophagus, gastric body, gastroesophageal junction, and incisura of the stomach

Hospital Course

- ❖ The patient was started on empiric fluconazole
- ❖ The day after his admission,, the patient then underwent an esophagogastroduodenoscopy which demonstrated diffuse candida esophagitis
- ❖ He improved with oral fluconazole and was discharged after a short hospitalization
- ❖ During admission his CD4 count resulted at 14, and he was referred to infectious disease for optimization of therapy

Discussion

- ❖ Esophagitis symptoms typically include dysphagia, odynophagia, or retrosternal chest pain; some patients are asymptomatic
- ❖ Candida is an opportunistic infection with impaired cell-mediated immunity a major risk factor, which includes HIV, chemotherapy, chronic immunosuppression with steroids, adrenal insufficiency, diabetes mellitus, and advanced age
- ❖ Esophageal candidiasis has a prevalence of 9.8% in HIV-positive patients, and 0.32-5.2% in the general population
- ❖ Physical exam will commonly reveal oral thrush, however 18% of patients had no oral thrush in one study, just like this patient
- ❖ In an immunocompromised patient presenting with odynophagia, it is acceptable to empirically treat with an antifungal such as fluconazole for 14-21 days
- ❖ If the patient reports no improvement within 3 days, then the patient should undergo esophagogastroduodenoscopy to determine the underlying cause

References

- Robertson KD, Nagra N, Mehta D. Esophageal Candidiasis. [Updated 2022 Aug 1]. In: StatPearls [Internet]. Treasure Island (FL): StatPearls Publishing; 2022 Jan-. Available from: <https://www.ncbi.nlm.nih.gov/books/NBK537268/>
- Bing-Syuan Zeng, Bing-Yan Zeng, Chao-Ming Hung, Tien-Yu Chen, Yi-Cheng Wu, Yu-Kang Tu, Pao-Yen Lin, Kuan-Pin Su, Brendon Stubbs, Cheuk-Kwan Sun, Yu-Shian Cheng, Dian-Jeng Li, Chih-Sung Liang, Chih-Wei Hsu, Yen-Wen Chen, Ping-Tao Tseng & Chang-Hua Chen (2021) Efficacy and acceptability of different anti-fungal interventions in oropharyngeal or esophageal candidiasis in HIV co-infected adults: a pilot network meta-analysis, Expert Review of Anti-infective Therapy, 19:11, 1469-1479, DOI: [10.1080/14787210.2021.1922078](https://doi.org/10.1080/14787210.2021.1922078)