

Mucus! What is it good for? Absolutely Something!

Tania Kohal, MD¹

¹Louisiana State University Health Sciences Center

Abstract

Introduction: Berlin criteria specifies bilateral opacities as a criterion for diagnosing acute respiratory distress syndrome (ARDS). Prior case literature has identified unilateral ARDS in patients with prior lobectomy, trauma, radiation, pulmonary agenesis and rare lung infections. Relatively little has been written about patients who lack these risk factors and the development of unilateral ARDS.

Case description: Here we present a patient with a past medical history of chronic obstructive pulmonary disease (COPD), who was admitted for shortness of breath and respiratory failure with viral prodrome symptoms. On admission, she was noted on computed tomography (CT) to have near-total atelectasis of her left lung with concern for mucus plugging and surrounding pleural effusion, but was maintained on her home oxygen dose. She developed worsening hypoxemia during her admission, and was found to be COVID-19 positive several days into her hospitalization. A new CT of her chest showed diffuse interstitial and ground glass changes in the right lung while the left lung remained collapsed. The patient was eventually intubated for worsening respiratory failure and a bronchoscopy was done with very thick mucus plug removal from the left mainstem bronchus and segmental airways. Post-bronchoscopy, the patient had significantly improved oxygen saturation and overall pulmonary compliance, and was extubated within a few days. Repeat CT imaging showed right sided predominant airspace disease with developing fibrosis and interstitial thickening with re-inflation of the left lung and sparing of the parenchyma on this side. A follow up chest X-ray a month later demonstrated persistence of right lung fibrotic changes and clear lung parenchyma on the left.

Discussion: This case highlights an interesting phenomenon of lung protection that resulted from a mechanical obstruction with mucus, which is normally considered a pathological condition. In this patient, it is possible that simple obstruction prevented a large viral load entering into the left lung, or diminished the severity of insult. Moreover, there may be altered physiology in the atelectatic or obstructed lung, leading to changes in infiltration by immune cells and cytokine responses are different in the deranged lung. Further investigation of patients with unilateral ARDS could have implications for future development of lung protection strategies in ARDS and a better understanding of molecular physiology in this pathological state.

Introduction

Berlin criteria specifies bilateral opacities as a criterion for diagnosing acute respiratory distress syndrome (ARDS). Prior case literature has identified unilateral ARDS in patients with prior lobectomy, trauma, radiation, pulmonary agenesis and rare lung infections.¹²³ Relatively little has been written about patients who lack these risk factors and the development of unilateral ARDS.

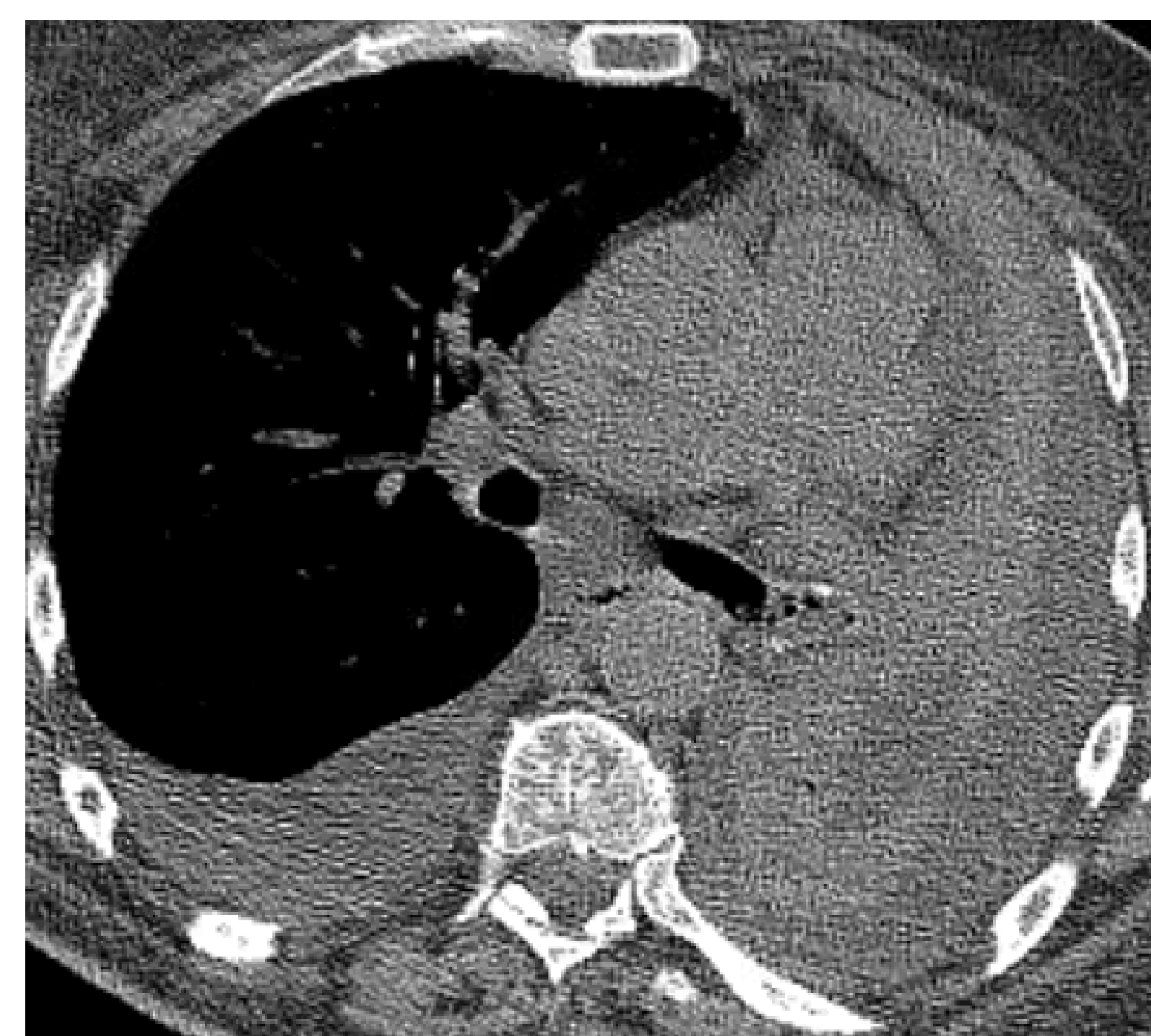
Case Description

A 57 year old patient with a past medical history of chronic obstructive pulmonary disease (COPD) on home oxygen of 3-4 liters per minute who was admitted for shortness of breath and respiratory failure with viral prodrome symptoms.

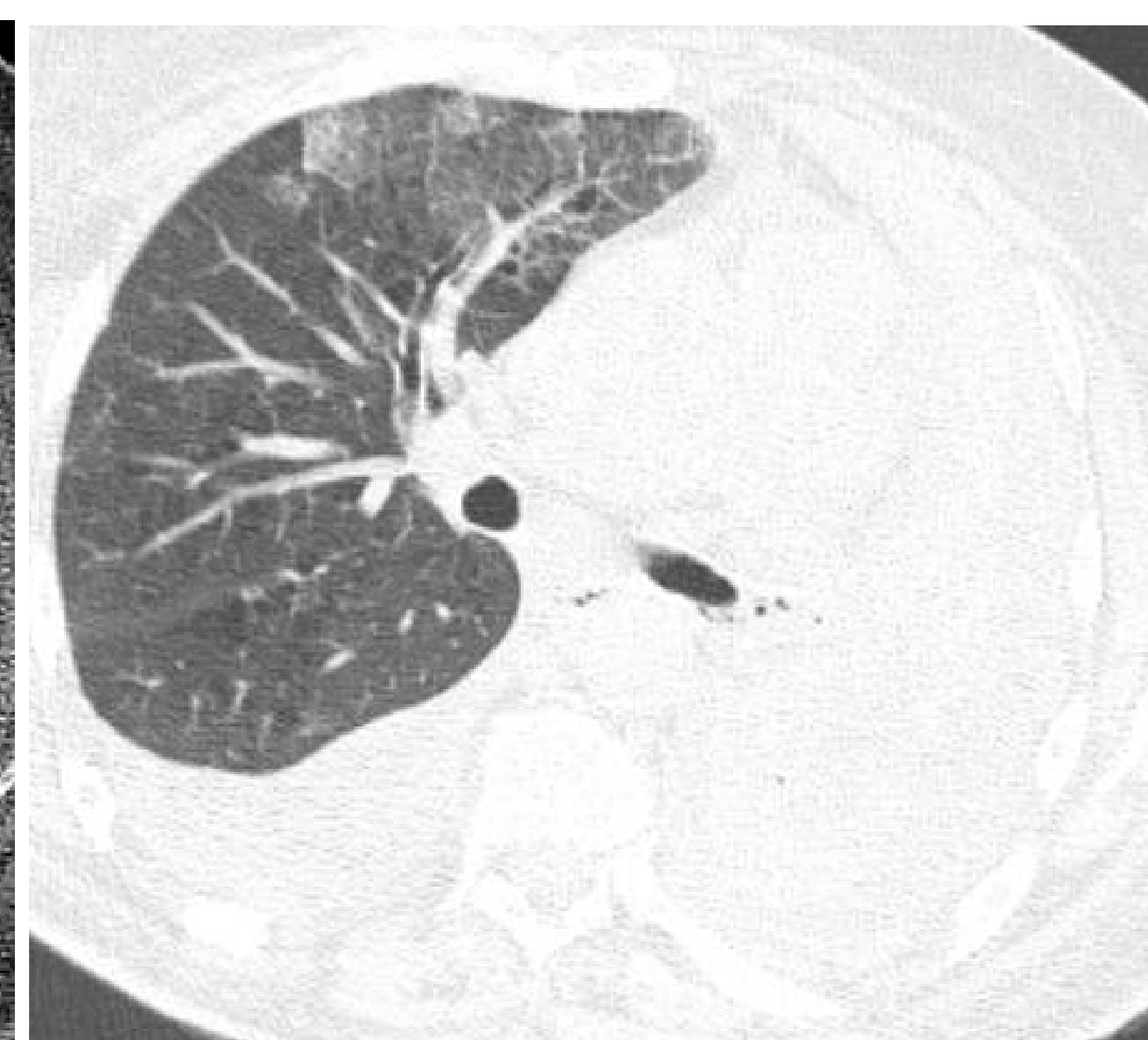
- Covid-19 test positive several days into admission
- CT chest (#1) done given worsening hypoxemic respiratory failure
- Patient continued to have worsening respiratory failure requiring admission to the intensive care unit (ICU) and intubation
- Bronchoscopy was done with very thick mucus plug removal from the left mainstem bronchus and segmental airways.

Images

#1 CT Chest



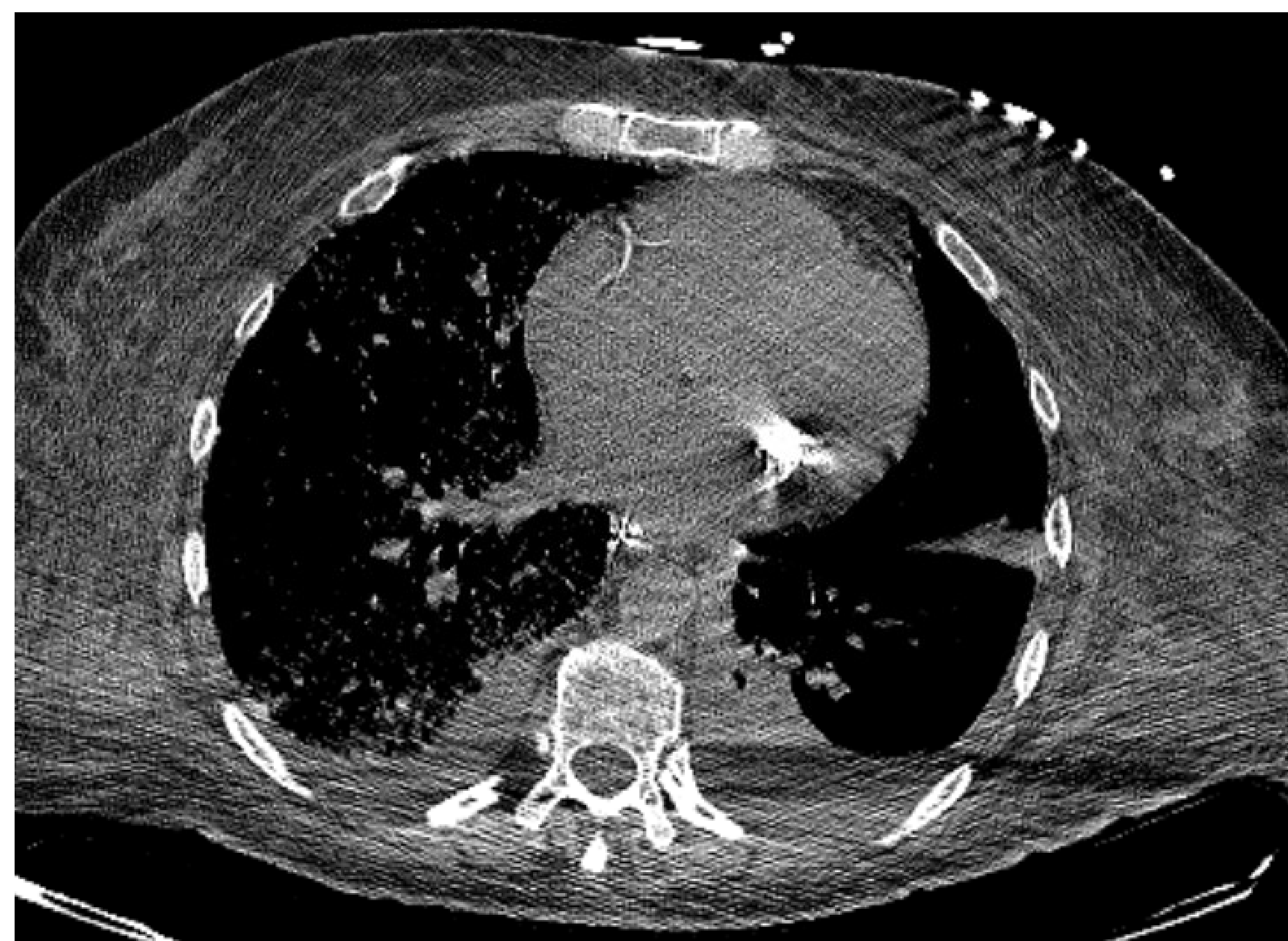
Soft tissue window



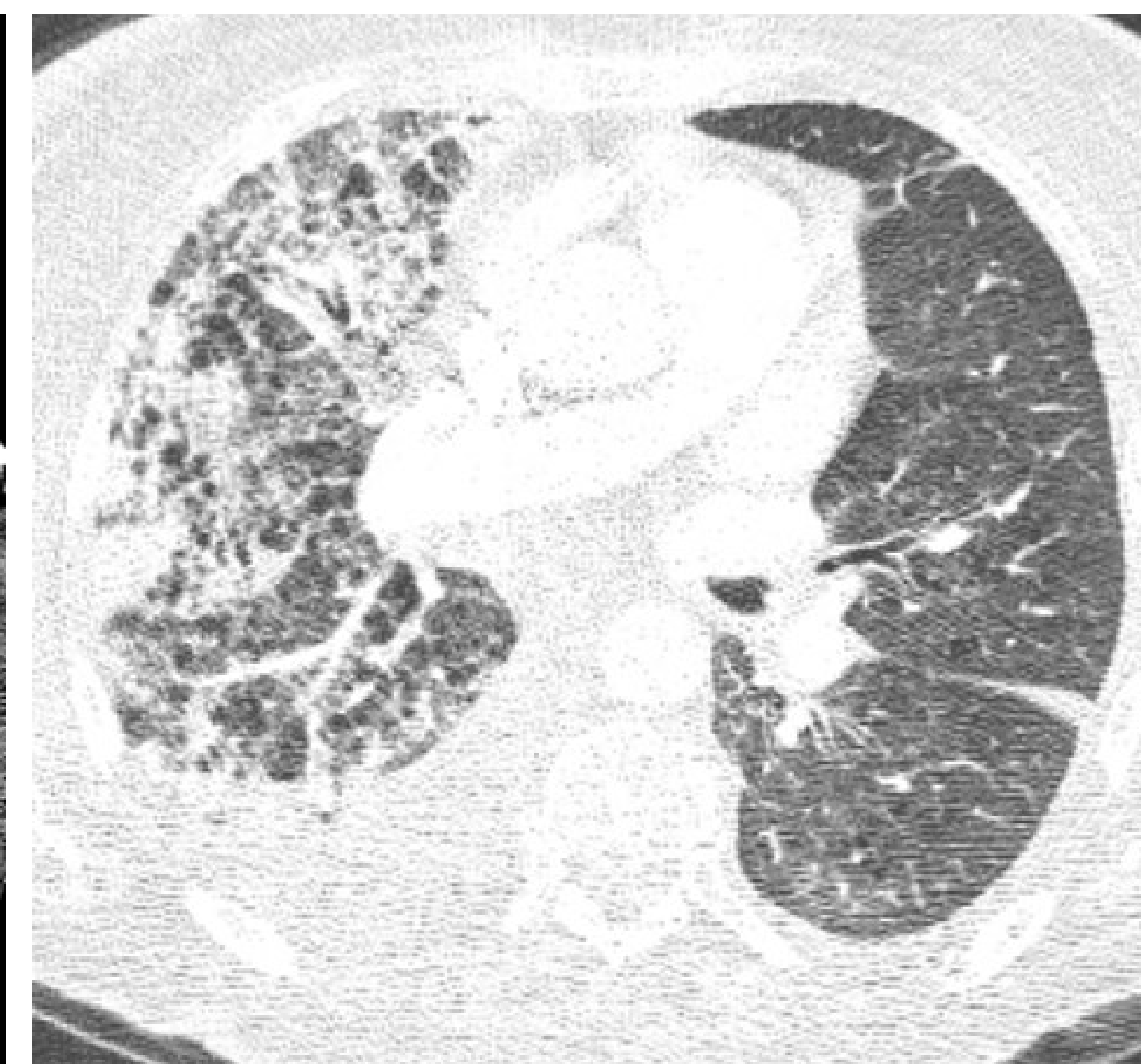Lung window

Bronchoscopy performed

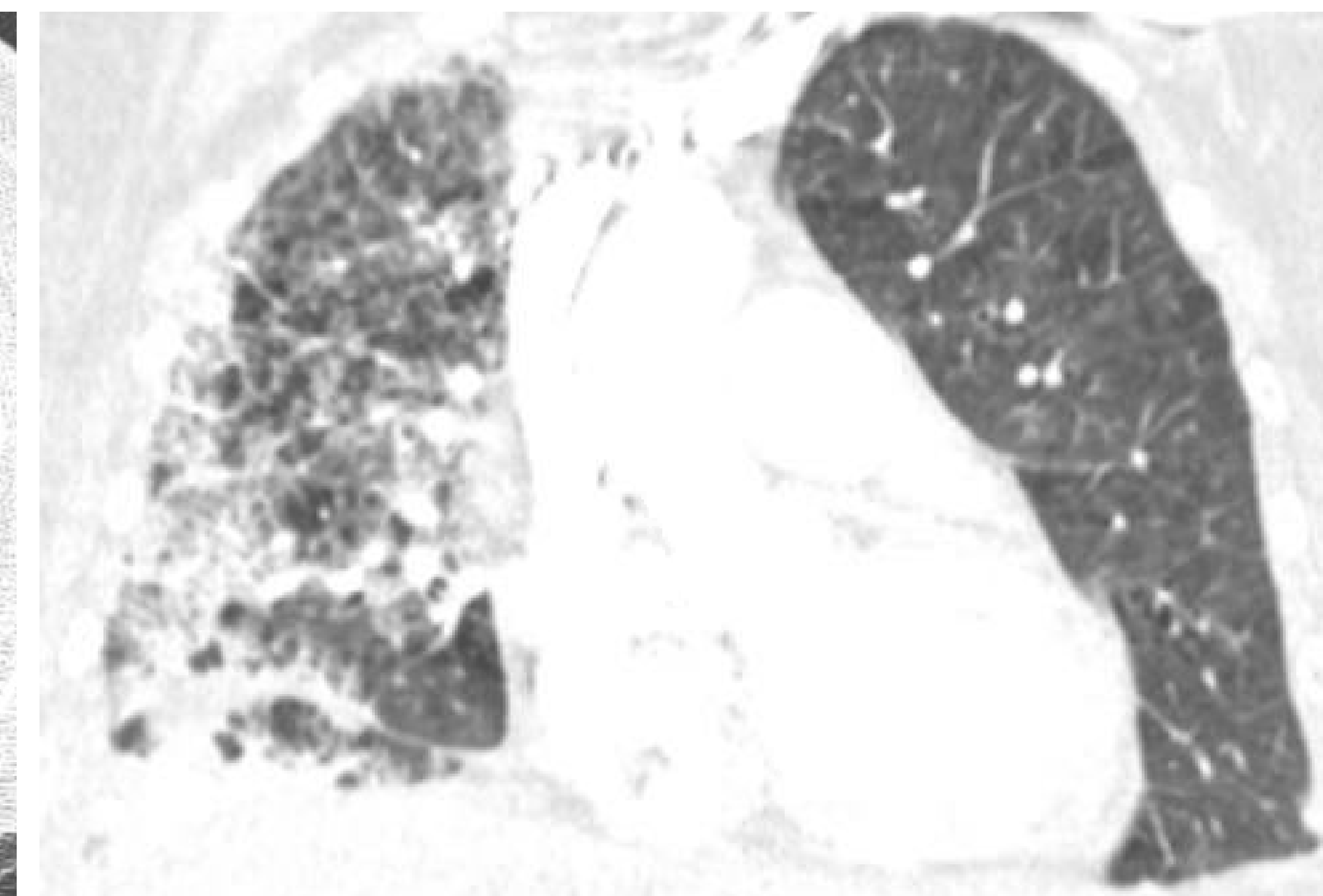
#2 CT Chest



Soft tissue window



Lung window - axial



Lung window - coronal

Patient had dramatic improvement in oxygenation over the subsequent 24 hours and was able to be extubated



References

Discussion

This case highlights an interesting phenomenon of lung protection from mucus plugging, normally a pathological condition. It is possible that simple obstruction prevented a large viral load entering into the left lung, or diminished the severity of insult. Moreover, there may be altered physiology in the atelectatic or obstructed lung, leading to changes in infiltration by immune cells and cytokine responses.

Conclusions

Further investigation of patients with unilateral ARDS could have implications for future development of lung protection strategies in ARDS and a better understanding of molecular physiology in this pathological state.