

A rare case of immunotherapy-induced hemolytic anemia post-nivolumab

Donnell White, III¹ and Dr. Agustin Garcia²

¹ School of Medicine, LSU Health Sciences Center, New Orleans, LA, USA

² Section of Hematology/Oncology, LSU Health Sciences Center, New Orleans, LA, USA

BACKGROUND

- Immunotherapy has been widely used to treat numerous solid and hematologic malignancies, showing dramatic clinical benefits compared to traditional chemotherapeutics (1-2, 4).
- Antibodies such as nivolumab (a PD-1 inhibitor) target various immune checkpoints, initiating a T-cell anti-tumor response (1-3).

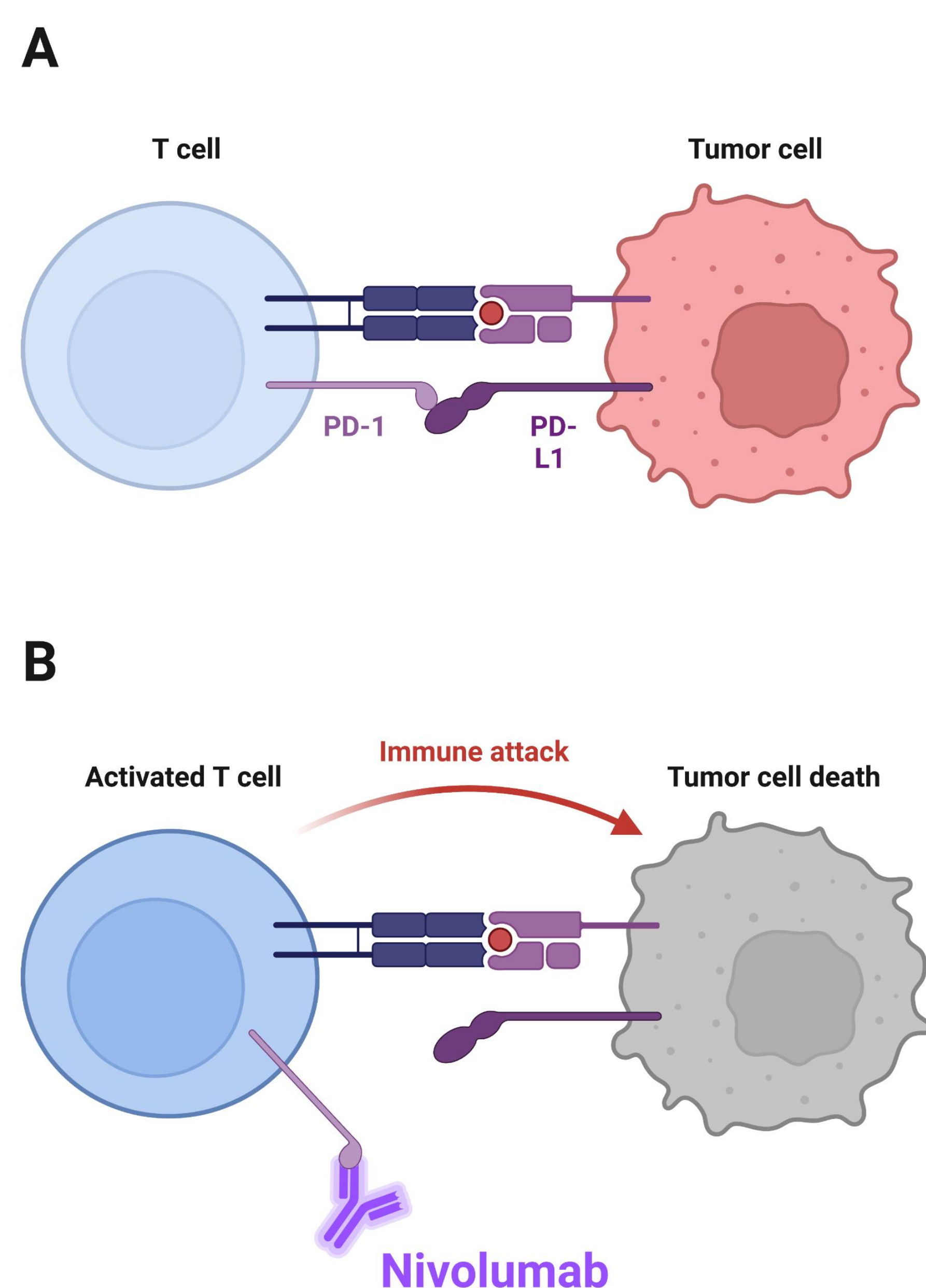


Figure 1. A) PD-L1 expression on tumor cells results in cancer cell evasion from immune attack. B) Nivolumab, an antiPD-1 antibody, prevents the T-cell interaction with PD-L1-expressing tumor cells, thus rendering an immune attack, effectively killing the cancer cell.

- Drug-induced hemolytic anemia (DIHA) is rare.
- The drugs most frequently associated with DIHA are antibiotics (beta-lactamase inhibitors, cephalosporins) and less commonly anti-inflammatories and cytotoxic chemotherapy agents (fludarabine, platinum) (1,4).
- DIHA may be seen after nivolumab therapy and is commonly mediated through IgG or C3.
- Few cases of associated DIHA secondary to immunotherapy have been reported. Here we present a case of anemia associated with nivolumab.

CASE REPORT

- This patient is an 80-year-old female with dementia, history of breast cancer 10 years ago, and history of stage I left upper lobe lung cancer 2 years ago.
- On April 2022 she underwent routine surveillance imaging studies that showed interval development of hypermetabolic nodules in the right upper lung lobe, right hilar and mediastinal lymphadenopathy, and bone metastases.
- She underwent an endobronchial ultrasound, and a biopsy showed metastatic adenocarcinoma consistent with lung cancer.
- Molecular profiling showed that the tumor was negative for PD-L1, EGFR, ROS1, ALK, RET, and MET mutations.
- She started treatment with nivolumab on May 2022.
- After 3 cycles of treatment, she reported shortness of breath and fatigue.
- Laboratory findings showed new onset of normochromic normocytic anemia, elevated reticulocytes, bilirubin and LDH, and low haptoglobin. DAT negative.
- A peripheral blood smear review showed schistocytes indicated by the black arrows (Figure 2).
- The patient was admitted to the hospital and transfused. CT scans showed the progression of lung cancer.
- She elected to go into home hospice.

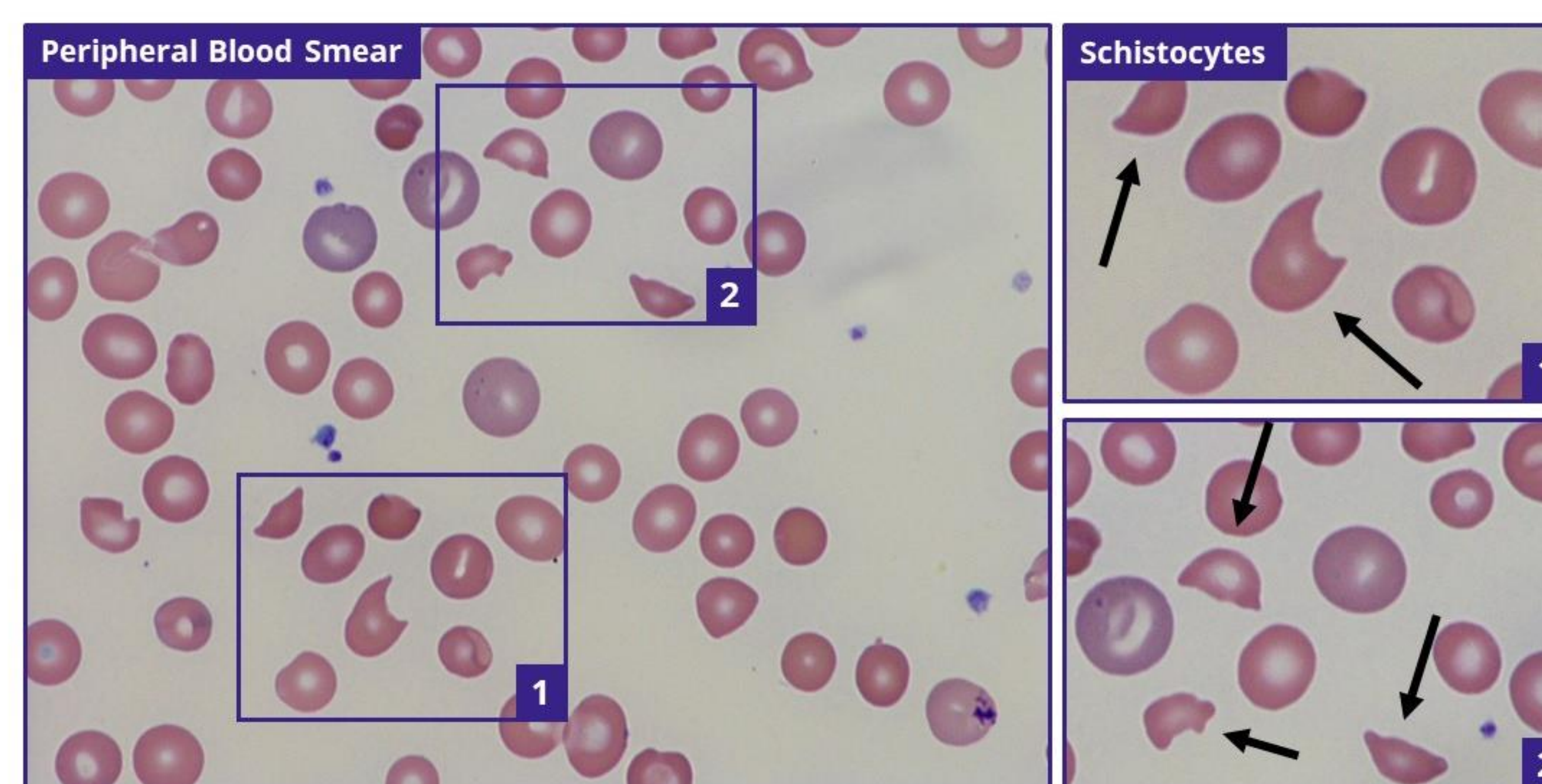


Figure 2. The patient's peripheral blood smear showed numerous schistocytes, consistent with her hemolytic anemia diagnosis secondary to immunotherapy.

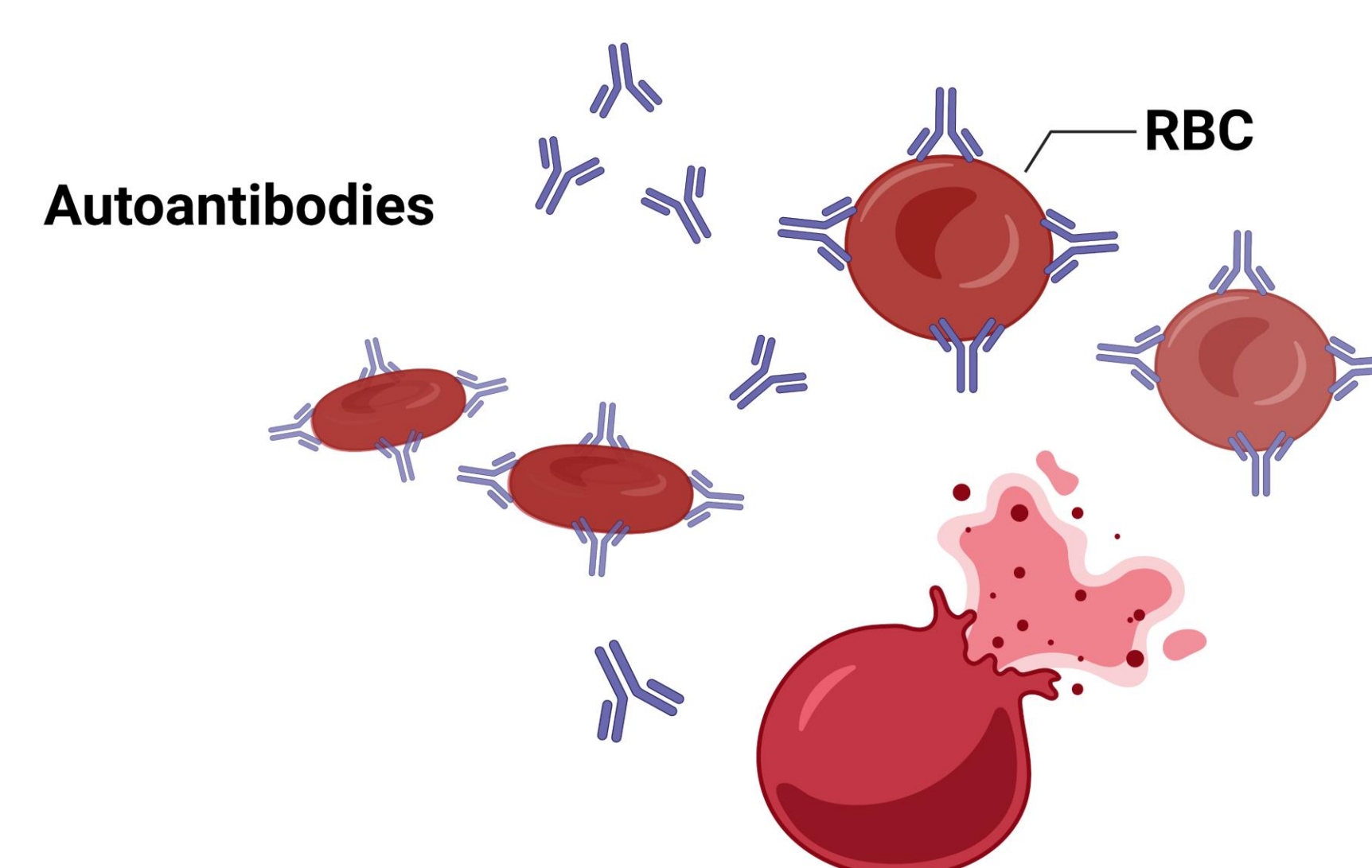


Figure 3. In immunotherapy-related DIHA, antibody therapy renders the red blood cells as foreign substances, initiating hemolysis throughout the body.

DISCUSSION

- Although rare, several hematological severe immune-mediated adverse effects are associated with immunotherapy (1, 5, 6).
- Drug-induced hemolytic anemia (DIHA) remains poorly characterized and should be a concern when treating cancer patients with immunotherapy regimens.
- Principle treatment for drug-induced hemolytic anemia is removing the exposure by discontinuing the implicated drug(s).
- Can also be treated with immunomodulatory therapies including glucocorticoids and/or intravenous immune globulin (IVIG).
- Based on this patient's clinical presentation, her hemolytic anemia is most likely due to her nivolumab treatment.

CONCLUSION

- The risk of immune-mediated hematologic adverse effects should be considered in all patients receiving immunotherapy.
- Identifying the early signs and symptoms of therapy-related DIHA is vital so the patient can receive appropriate management, such as a high-dose steroid and plasma exchange.
- Although immunotherapy has drastically improved cancer treatments, it is crucial for healthcare professionals to be familiar with the adverse effects of immunotherapy, allowing healthcare professionals to recognize DIHA better and manage these potentially life-threatening side effects.

REFERENCES

- Akkin S, Varan G, Bilensoy E. A Review on Cancer Immunotherapy and Applications of Nanotechnology to Chemoimmunotherapy of Different Cancers. *Molecules*. 2021; 26(11):3382. <https://doi.org/10.3390/molecules26113382>
- Carbó-Bagué A, Fort-Cuillas R, Pla-Juher H, Rubió-Casadevall J: Nivolumab-Induced Autoimmune Hemolytic Anaemia and Safety of Subsequent Use of Ipilimumab: A Case Report. *Case Rep Oncol* 2021;1289-1294. doi: 10.1159/000518530
- Johnson, D.B., Nebhan, C.A., Moslehi, J.J. et al. Immune-checkpoint inhibitors: long-term implications of toxicity. *Nat Rev Clin Oncol* 19, 254-267 (2022). <https://doi.org/10.1038/s41571-022-00600-w>
- Khan, U., Ali, F., Khurram, M.S. et al. Immunotherapy-associated autoimmune hemolytic anemia. *J. immunotherapy cancer* 5, 15 (2017). <https://doi.org/10.1186/s40425-017-0214-9>
- R. Nair, S. Gheith and S. G. Nair. Immunotherapy-Associated Hemolytic Anemia with Pure Red-Cell Aplasia. *New England Journal of Medicine* 2016 Vol. 374 Issue 11 Pages 1096-1097, DOI: 10.1056/nejmc1509362
- Yang Y, Jin G, Pang Y, Huang Y, Wang W, Zhang H, Tuo G, Wu P, Wang Z, Zhu Z. Comparative Efficacy and Safety of Nivolumab and Nivolumab Plus Ipilimumab in Advanced Cancer: A Systematic Review and Meta-Analysis. *Front Pharmacol*. 2020 Feb 14;11:40. doi: 10.3389/fphar.2020.00040. PMID: 32116716; PMCID: PMC7033417.

