

## Toxic Encephalopathy and Associations with Calcineurin Inhibitors

Josh FitzPatrick BSc<sup>1</sup>, Gurtaj Mahil D.O.<sup>2</sup>, Hanna Almoaswes M.D.<sup>2</sup>, Caroline Neck M.D.<sup>2</sup>, Salena Sinnasonne<sup>1</sup>, Philip Doyle<sup>1</sup>, Dr. Daniel Holmes M.D.<sup>2</sup>

<sup>1</sup>School of Medicine, Louisiana State University Health Sciences Center, New Orleans, LA; <sup>2</sup>Department of Medicine, Louisiana State University Health Sciences Center, New Orleans, LA

**Introduction:** Immunosuppressive encephalopathy is a syndrome of acute altered mentation often associated with fevers, focal deficits, and aphasia. Common causes include anti-neoplastic agents and calcineurin inhibitors. Laboratory findings include pleocytosis and elevated protein on lumbar puncture with a negative infectious workup. Pertinent imaging includes T2/FLAIR hyperintensities in white matter particularly in the frontal and parietal lobes and corpus callosum.

**Case:** This is a 39-year-old female with systemic lupus erythematosus, bilateral blindness due to lupus, and chronic kidney disease who presented with altered mentation and fevers following an arteriovenous fistula (AVF) procedure. Pertinent medications include voclosporin, azathioprine, hydroxychloroquine, and steroids. Concern was given for sepsis related infection from AVF graft, but investigation showed no signs of infection surrounding the surgical site. A lumbar puncture was performed showing pleocytosis, elevated protein, and no microorganisms. The patient became increasingly febrile and lethargic leading to her being intubated, requiring cooling blankets, and stepped up to the intensive care unit. The patient was treated with antibiotics and steroids out of concern for both infectious and autoimmune causes. A full infectious workup was negative. Autoimmune workup showed a positive ANA and elevated C4 complement, but the remaining workup was negative or inconclusive. A magnetic resonance image of the brain showed T2 hyperintensities throughout the periventricular white matter, external capsule, and corpus callosum. She briefly underwent hemodialysis for uremia with subsequent improvement in her mental status. The patient showed improving mental and physical function following extubation and returned to her mental baseline after a few days.

**Discussion:** We had a broad differential that included lupus cerebritis, infection, and adverse drug effect. Infection, lupus cerebritis, and anti-NMDA encephalitis were ruled out due to a negative laboratory work up. Our top differential is medication- induced encephalopathy due to imaging and lab findings. While other calcineurin inhibitors such as cyclosporine and tacrolimus have been associated with toxic leukoencephalopathy, there is no documented literature showing an association between voclosporin and toxic leukoencephalopathy. Voclosporin has been shown in studies to have neurotoxic effects, specifically with the development of headaches, migraines, seizures, and posterior reversible encephalopathic syndrome in higher doses of either 23.7mg or 39.5mg twice daily. Voclosporin is a next generation analog of cyclosporine that was FDA approved in 2021 for the treatment of lupus nephritis. While there are no current studies

suggesting a link between toxic encephalopathy and voclosporin, it should still be considered when working up toxic leukoencephalopathy.

<b>Autoimmune Workup</b>	<b>Result</b>	<b>Meningitis/encephalitis panel</b>	<b>Result</b>
RNP Antibodies	3.3 High	Escherichia coli K1	Not detected
Smith Antibodies	0.4	Haemophilus influenzae	Not detected
Antiscleroderma-70Antibodies	0.3	Listeria monocytogenes	Not detected
Sjogren's Anti-SS-A	<0.2	Neisseria meningitidis	Not detected
Sjogren's Anti-SS-B	<0.2	Streptococcus agalactiae	Not detected
Antichromatin Antibodies	2.9 High	Streptococcus pneumoniae	Not detected
Anti-Jo-1	<0.2	Cytomegalovirus	Not detected
Anti-Centromere B Antibodies	<0.2	Enterovirus	Not detected
ANA Positive	Positive	Herpes simplex virus 1	Not detected
Anti-dsDNA Ab 8	8 (equivocal)	Herpes simplex virus 2	Not detected
C4 complement 48 (WNL)	48 (normal)	Human herpesvirus 6	Not detected
C3 complement 138 (WNL)	138 (normal)	Human parechovirus	Not detected
Cryptococcal Ag normal	normal	Varicella zoster	Not detected
ADAMTS13 activity 39.9 (abnormal)	39.9 (abnormal)	Cryptococcus neoformans	Not detected
Histoplasma capsulatum Ab negative	negative		
<b>Oligoclonal Band Profile</b>			
<b>IgG, Quant, CSF</b>	<b>Result</b>	<b>CSF labs</b>	<b>Result</b>
IgG, Quant, CSF	56.6 High	Clarity	Xanthrochromia
Albumin, CSF	181 High	CSF glucose	44
Albumin	3.1 Low	CSF protein	>200
Immunoglobulin G, Qn, Serum	1476	CSF TNC	75
IgG/Alb Ratio, CSF	0.31 High	CSF RBC	126
CSF IgG Index	0.7	CSF gram stain	many WBC, no organisms
IgG, Syn Rate, CSF	91.5 High	CSF Number of Cells Counted	100
Oligoclonal band profile	zero detected	CSF Neutrophils Relative	59 High
		CSF Lymphocytes Relative	31 Low
		CSF Monocytes Relative	10
		CSF Mononuclear Cells	11

Table 1: Infectious and autoimmune workup lab values

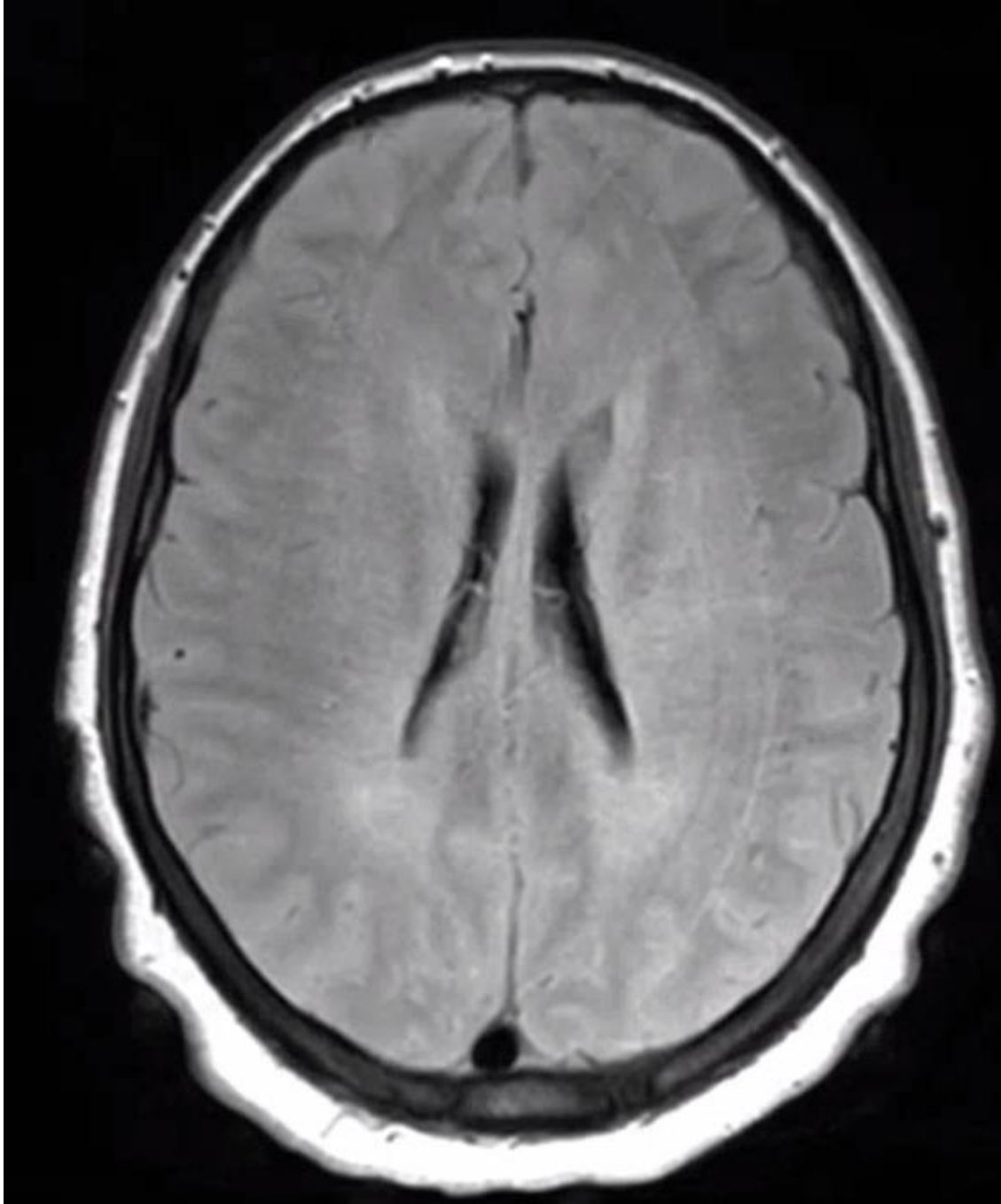


Figure 1: MRI T2 axial flair view of exhibiting T2 hyperintensities of the periventricular white matter, external capsule, and corpus callosum

## Citations

1. Arriens, C. *et al.* Update on the Efficacy and Safety Profile of Voclosporin: An Integrated Analysis of Clinical Trials in Lupus Nephritis. *Arthritis Care & Research* **75**, 1399–1408 (2023).
2. Filley, C. M. & Kleinschmidt-DeMasters, B. K. Toxic Leukoencephalopathy. *N Engl J Med* **345**, 425–432 (2001).
3. Gu, B., Lv, B. & Tang, J. Phase IV safety evaluation of voclosporin in lupus nephritis patients using the FAERS database for a 42-month period (2021 – 2024). *CP* (2025) doi:[10.5414/CP204726](https://doi.org/10.5414/CP204726).
4. Inoha, S. *et al.* Magnetic resonance imaging in cases with encephalopathy secondary to immunosuppressive agents. *Journal of Clinical Neuroscience* **9**, 305–307 (2002).
5. Mammoser, A. Calcineurin Inhibitor Encephalopathy. *Semin Neurol* **32**, 517–524 (2013).
6. Rovin, B. H. *et al.* A randomized, controlled double-blind study comparing the efficacy and safety of dose-ranging voclosporin with placebo in achieving remission in patients with active lupus nephritis. *Kidney International* **95**, 219–231 (2019).
7. Rubio, J. & Kytтарыs, V. Journal Club: Efficacy and Safety of Voclosporin Versus Placebo for Lupus Nephritis (AURORA 1): A Double-Blind, Randomized, Multicenter, Placebo-Controlled, Phase 3 Trial. *ACR Open Rheumatology* **3**, 827–831 (2021).
8. Shah, V. R. & Bankole, A. Voclosporin. in *StatPearls* (StatPearls Publishing, Treasure Island (FL), 2025).
9. Smeralda, C. L., Gigli, G. L., Vogrig, A., Marini, A. & Valente, M. Tacrolimus-induced severe headache associated with diffuse leukoencephalopathy: Evidence for an immune-mediated pathogenesis. *Journal of Neuroimmunology* **330**, 55–58 (2019).
10. Wang, Z., Lang, Y., Liu, X., Wang, Y. & Shao, L. Post-marketing safety surveillance of voclosporin: an observational, pharmacovigilance study leveraging faers database study on the safety of voclosporin. *Front Pharmacol* **16**, 1506760 (2025).
11. Zhang, J. *et al.* Clinical adverse events to voclosporin: a real-world drug safety study based on FDA Adverse Event Reporting System. *Clinical and Experimental Rheumatology* (2025) doi:[10.55563/clinexprheumatol/qhyux8](https://doi.org/10.55563/clinexprheumatol/qhyux8).