

## INDICATIONS FOR COMPUTED TOMOGRAPHY IN PATIENTS WITH MINOR HEAD INJURY

MICELLE J. HAYDEL, M.D., CHARLES A. PRESTON, M.D., TREVOR J. MILLS, M.D., SAMUEL LUBER, B.A., ERICK BLAUDEAU, M.D., AND PETER M.C. DEBLIEUX, M.D.

### ABSTRACT

**Background** Computed tomography (CT) is widely used as a screening test in patients with minor head injury, although the results are often normal. We performed a study to develop and validate a set of clinical criteria that could be used to identify patients with minor head injury who do not need to undergo CT.

**Methods** In the first phase of the study, we recorded clinical findings in 520 consecutive patients with minor head injury who had a normal score on the Glasgow Coma Scale and normal findings on a brief neurologic examination; the patients then underwent CT. Using recursive partitioning, we derived a set of criteria to identify all patients who had abnormalities on CT scanning. In the second phase, the sensitivity and specificity of the criteria for predicting a positive scan were evaluated in a group of 909 patients.

**Results** Of the 520 patients in the first phase, 36 (6.9 percent) had positive scans. All patients with positive CT scans had one or more of seven findings: headache, vomiting, an age over 60 years, drug or alcohol intoxication, deficits in short-term memory, physical evidence of trauma above the clavicles, and seizure. Among the 909 patients in the second phase, 57 (6.3 percent) had positive scans. In this group of patients, the sensitivity of the seven findings combined was 100 percent (95 percent confidence interval, 95 to 100 percent). All patients with positive CT scans had at least one of the findings.

**Conclusions** For the evaluation of patients with minor head injury, the use of CT can be safely limited to those who have certain clinical findings. (N Engl J Med 2000;343:100-5.)

©2000, Massachusetts Medical Society.

**T**HE question of which patients with head trauma should undergo scanning has remained controversial since the introduction of computed tomography (CT) in the early 1970s. Initially, CT was a scarce resource reserved for severely injured patients. As CT scanners became more widely available, numerous studies of CT have focused on patients with minor head injury who have intracranial lesions. In the early 1990s, several retrospective studies of patients with minor head injury reported substantial proportions with intracranial lesions on CT (17 to 20 percent). These studies included patients with scores of 13 to 15 on the Glasgow Coma Scale, indicating little or no impair-

ment in consciousness. (The scores on the scale range from 3, indicating no motor or verbal response and no opening of the eyes, to 15, indicating normal motor and verbal responses and normal eye opening.) The authors concluded that CT was indicated in all patients with minor head injury.<sup>1-3</sup> In subsequent prospective studies of patients with a score of 15 on the Glasgow Coma Scale, the rate of intracranial lesions on CT was much lower (6 to 9 percent).<sup>4-6</sup>

The use of clinical findings as predictors of intracranial lesions in patients with minor head injury has been evaluated in several studies.<sup>4,5,7</sup> In two studies, selective use of CT on the basis of clinical findings identified 96 percent and 98 percent of patients with abnormalities on CT scanning,<sup>5,7</sup> and none of the patients with abnormalities who did not have the specified clinical findings required neurosurgery.<sup>4,5</sup> However, some physicians are not willing to accept the risk of missing an abnormality. In a survey of emergency physicians, more than half insisted that a clinical decision rule for minor head injury must have a sensitivity of 100 percent.<sup>8</sup> Thus, the use of CT to screen patients with minor head injury for intracranial lesions has become routine, but such screening is expensive. According to one estimate, even a 10 percent reduction in the number of CT scans in patients with minor head injury would save more than \$20 million per year.<sup>9</sup> We conducted a study to derive and validate a set of clinical criteria that could be used to identify patients with minor head injury in whom CT could be forgone. The study was conducted in two phases at a large, inner-city, level 1 trauma center from December 1997 to June 1999.

### METHODS

#### Phase 1

In phase 1 of the study, 520 consecutive patients who had minor head injury, who were at least three years old, and who presented within 24 hours after the injury were prospectively evaluated to determine which clinical findings identified patients with positive findings on CT studies of the head. In phase 2, the set of findings found to have predictive value in phase 1 was prospectively evaluated in a separate group of 909 consecutive patients with minor head injury who were similar to the patients in phase 1 with respect to age and the interval between injury and presentation. Since all patients with minor head injury and loss of con-

From the Sections of Emergency Medicine (M.J.H., C.A.P., T.J.M., S.L., P.M.C.D.) and Emergency Radiology (E.B.), Louisiana State University Health Science Center at New Orleans, New Orleans. Address reprint requests to Dr. Haydel at the Emergency Medicine Offices, Charity Hospital, 13th Fl., 1532 Tulane Ave., New Orleans, LA 70112, or at micellehaydel@yahoo.com.

sciousness or amnesia for the traumatic event, regardless of other symptoms or signs, routinely undergo CT at our center, no additional CT scans were ordered for the purpose of the study. The institutional review board approved the study and waived the requirement to obtain informed consent because we planned to record data ordinarily obtained in the evaluation of patients with minor head injury.

Minor head injury was defined as loss of consciousness in patients with normal findings on a brief neurologic examination (normal cranial nerves and normal strength and sensation in the arms and legs) and a score of 15 on the Glasgow Coma Scale, as determined by a physician on the patient's arrival at the emergency department. Advanced emergency-medicine residents, under faculty supervision, performed the initial evaluation of all patients, including the determination of whether the patient had lost consciousness and of the score on the Glasgow Coma Scale and the neurologic examination. Patients were considered to have lost consciousness if a witness or the patient reported loss of consciousness by the patient or if the patient could not remember the traumatic event. Patients with isolated deficits in short-term memory and an otherwise normal score on the Glasgow Coma Scale were considered to have a normal score on the scale. All patients included in the study underwent CT scanning. Patients who declined CT, had concurrent injuries that precluded the use of CT, or reported no loss of consciousness or amnesia for the traumatic event were excluded from the study. The CT scan was considered to be positive if it showed the presence of an acute traumatic intracranial lesion (a subdural, epidural, or parenchymal hematoma; subarachnoid hemorrhage; cerebral contusion; or depressed skull fracture). All patients with positive CT scans were admitted by the neurosurgical team and were followed until discharge in order to document any neurosurgical interventions.

All questionnaires and clinical assessments were completed before the CT studies were performed. All physicians participating in the study received an explanation of the questionnaire, including the definition of each criterion. The items included in the phase 1 questionnaire, which were selected after an extensive review of the literature on minor head injury, included age and the presence or absence of headache, vomiting, drug or alcohol intoxication, deficits in short-term memory, post-traumatic seizure, history of coagulopathy, and physical evidence of trauma above the clavicles.

Headache was defined as any head pain, whether diffuse or local. Vomiting was defined as any emesis after the traumatic event. Drug or alcohol intoxication was determined on the basis of the history obtained from the patient or a witness and suggestive findings on physical examination, such as slurred speech or the odor of alcohol on the breath. Measurements of blood alcohol and toxicologic tests were ordered at the discretion of the physician. A deficit in short-term memory was defined as persistent anterograde amnesia in a patient with an otherwise normal score on the Glasgow Coma Scale. Physical evidence of trauma above the clavicles was defined as any external evidence of injury, including contusions, abrasions, lacerations, deformities, and signs of facial or skull fracture. Seizure was defined as a suspected or witnessed seizure after the traumatic event. Coagulopathy was defined as a history of bleeding or a clotting disorder or current treatment with warfarin. We did not ask about aspirin therapy or order studies of coagulation factors or platelet counts. Questionnaire responses, examination data, and CT results from phase 1 were entered into a data base. The patients who had normal CT findings were compared with those who had abnormalities on CT. Chi-square analysis and likelihood ratios were determined for each criterion, and sensitivity and specificity were calculated for the best combinations of criteria. Chi-square recursive-partitioning analysis was performed with the use of SPSS software, version 8.0,<sup>10</sup> in order to select a set of criteria that identified all patients with positive CT scans.

## Phase 2

In phase 2 of the study, the seven findings that had predictive value in phase 1 were prospectively validated in a separate group

of 909 consecutive patients with minor head injury. The phase 2 questionnaire, also completed before CT was performed, included items on headache, vomiting, age, drug or alcohol intoxication, deficits in short-term memory, physical evidence of trauma above the clavicles, and seizure. The patients were separated into two groups: those who had at least one of the seven findings, and those who had none. The frequency of positive CT scans was determined for each group and then entered in a two-by-two table. The sensitivity, specificity, and negative predictive value of the criteria, with 95 percent confidence intervals, were then calculated.

## Interpretation of CT Scans

In both phases of the study, the CT scanning was performed with the use of a Somatom Plus 4 or Somatom Plus S scanner (Siemens), and the results were interpreted by staff neuroradiologists. An independent staff radiologist who was unaware of the original interpretations reviewed 50 randomly selected CT scans. Agreement between the two sets of readings was analyzed with the use of Cohen's kappa test and SPSS software, version 8.0.<sup>10</sup> There was agreement between the two interpretations for 49 scans (98 percent,  $\kappa=0.94$ ). The finding on one scan was interpreted as a contusion or an infarct initially and as an artifact by the independent radiologist. To determine the reproducibility of the clinical data, 50 patients were interviewed and examined by a second physician at the time of the initial evaluation. There was agreement between the two sets of evaluations for 46 patients (92 percent,  $\kappa=0.78$ ).

## RESULTS

The mean age of the 520 patients in phase 1 was 36 years (range, 3 to 97), and 65 percent were male. Thirty-six patients (6.9 percent; 95 percent confidence interval, 4.2 to 9.6 percent) had positive CT scans (Table 1). Three clinical findings (deficits in short-term memory, drug or alcohol intoxication, and physical evidence of trauma above the clavicles) were significantly associated with a positive CT scan. If patients without the combination of these three findings had not undergone CT scanning, the number of scans would have been reduced by 31 percent, although abnormalities would have been missed in two patients (sensitivity, 94 percent) (Table 2). Recursive-partitioning analysis yielded a set of seven findings that identified all patients with positive CT scans: headache, vomiting, an age over 60 years, drug or alcohol intoxication, deficits in short-term memory, physical evidence of trauma above the clavicles, and seizure (Fig. 1).

Among the 909 patients in phase 2, the mean age was 36 years (range, 3 to 94), and 65 percent were male. Fifty-seven patients had positive CT scans (6.3 percent; 95 percent confidence interval, 4.7 to 7.8 percent). All patients with positive scans had at least one of the seven findings (Table 3), resulting in a sensitivity of 100 percent (95 percent confidence interval, 95 to 100 percent), a negative predictive value of 100 percent (95 percent confidence interval, 99 to 100 percent), and a specificity of 25 percent (95 percent confidence interval, 22 to 28 percent). The 212 patients without any of the seven findings (23.3 percent; 95 percent confidence interval, 20.4 to 26.2 percent) all had normal CT scans.

Specific abnormalities detected on CT scanning

**TABLE 1.** ASSOCIATION BETWEEN CLINICAL FINDINGS AND CT RESULTS IN 520 PATIENTS WITH MINOR HEAD INJURY (PHASE 1).

FINDING*	TOTAL (N=520)	POSITIVE CT SCAN (N=36)	NEGATIVE CT SCAN (N=484)	P VALUE†	LIKELI- HOOD RATIO‡
		no. (%)			
Short-term memory deficits	9 (2)	5 (14)	4 (1)	<0.001	15.0
Drug or alcohol intoxication	180 (35)	22 (61)	158 (33)	0.001	11.0
Physical evidence of trauma above clavicles	338 (65)	32 (89)	306 (63)	0.002	11.0
Age >60 yr	42 (8)	6 (17)	36 (7)	0.05	3.0
Seizure	24 (5)	4 (11)	20 (4)	0.05	3.0
Headache	123 (24)	12 (33)	111 (23)	0.16	2.0
Vomiting	47 (9)	4 (11)	43 (9)	0.65	0.2
Coagulopathy	1 (<1)	0	1 (<1)	0.78	0.15

\*Some patients had more than one finding.

†P values were determined by chi-square analysis.

‡The likelihood ratio indicates the likelihood of a positive CT scan in patients with the finding in question as compared with the likelihood in patients without the finding.

**TABLE 2.** SENSITIVITY, SPECIFICITY, AND ESTIMATED REDUCTION IN THE USE OF CT WITH VARIOUS COMBINATIONS OF FINDINGS (PHASE 1).\*

FINDING	SENSITIVITY	SPECIFICITY	REDUCTION IN USE OF CT†
	percent		
Short-term memory deficits	14	99	94
Short-term memory deficits and intoxication	67	67	62
Short-term memory deficits, intoxication, and trauma	94	34	31
Short-term memory deficits, intoxication, trauma, and age >60 yr	97	32	29
Short-term memory deficits, intoxication, trauma, age >60 yr, and seizure	97	31	28
Short-term memory deficits, intoxication, trauma, age >60 yr, seizure, and headache	97	25	23
Short-term memory deficits, intoxication, trauma, age >60 yr, seizure, headache, and vomiting	100	24	22

\*All data are based on the P values and likelihood ratios shown in Table 1.

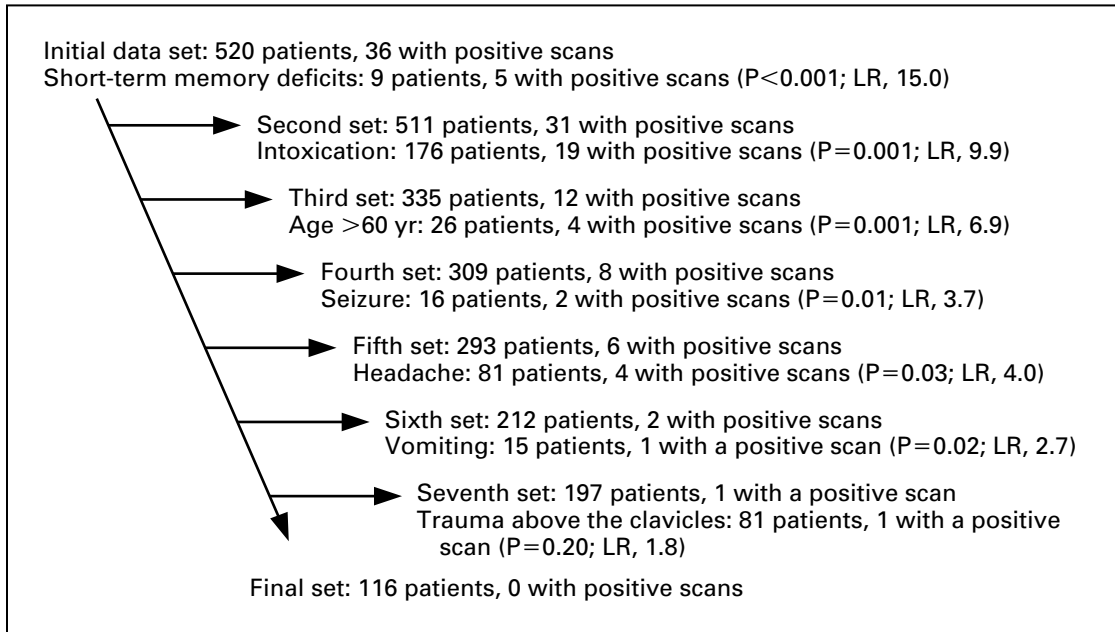
†The reduction in the use of CT is the percent reduction in the number of CT scans that would have resulted if patients without the finding or combination of findings had not undergone scanning.

are shown in Table 4. Of the 1429 patients in both phases of the study combined, 93 had positive CT scans (6.5 percent; 95 percent confidence interval, 5.2 to 7.7 percent), and 6 underwent surgery (0.4 percent; 95 percent confidence interval, 0.1 to 0.7 percent).

## DISCUSSION

Approximately two thirds of patients with head trauma in the United States are classified as having minor head injury<sup>11</sup>; less than 10 percent of patients with minor head injury have positive findings on CT scanning, and less than 1 percent require neurosurgical intervention.<sup>5,6</sup> Historically, the options for evaluation have included skull radiography, CT scanning, and observation in the emergency department or hospital. Several studies have concluded that patients with normal findings on neurologic examination and CT scanning can be safely discharged from the emergency department.<sup>7,12-14</sup> CT is the preferred imaging study for patients with minor head injury, although magnetic resonance imaging (MRI) is more sensitive in detecting subtle lesions.<sup>15,16</sup> As MRI becomes more widely available, it may have a greater role in the evaluation of patients with minor head injury.

The goal of our study was to develop and validate a simple set of clinical criteria for identifying patients with minor head injury who should undergo CT scanning. In phase I of the study, demographic data, symptoms, and the results of physical examination were prospectively recorded. In prior studies, the demographic data associated with abnormalities on CT in patients with minor head injury have included an age over 60 years,<sup>6,17,18</sup> alcohol intoxication,<sup>9,19,20</sup> and coagulopathy.<sup>21,22</sup> Symptoms associated with positive CT scans have included headache,<sup>5</sup> nausea and vomiting,<sup>5,7</sup> amnesia,<sup>9,19,22</sup> and seizures.<sup>7,23</sup> The findings with respect to minimal confusion are controversial.<sup>24</sup> Although most patients with loss of consciousness do not subsequently remember the traumatic event, some patients also have persistent anterograde am-



**Figure 1.** Results of Recursive-Partitioning Analysis.

Starting with the initial set of data on 520 patients, 36 of whom had positive CT scans, we repeatedly removed the data on patients who had the finding with the highest P value (by chi-square analysis) for the comparison between patients with positive scans and those with negative scans, until there was a set with no positive scans. The likelihood ratio (LR) indicates the likelihood of a positive CT scan in patients with the finding in question as compared with the likelihood in patients without the finding.

nesia, as evidenced by deficits in short-term memory, but are oriented and can follow commands. Such patients are considered to have a score of 15 on the Glasgow Coma Scale.<sup>6,25</sup> We included deficits in short-term memory as a criterion in order to account for patients with persistent anterograde amnesia and an otherwise normal score on the Glasgow Coma Scale. Findings on physical examination that have been associated with a positive CT scan include signs of linear, basilar, or depressed skull fracture<sup>6,18,26</sup> and scalp hematoma or soft-tissue injury.<sup>18</sup>

Of the 520 patients in phase 1, 36 (6.9 percent) had positive CT scans, a finding that is consistent with the results of other studies.<sup>4-6</sup> Recursive partitioning revealed that the presence of one or more of seven findings — headache, vomiting, an age over 60 years, drug or alcohol intoxication, deficits in short-term memory, physical evidence of trauma above the clavicles, and seizure — was associated with a positive CT scan. In previous studies, the presence of coagulopathy has been associated with a positive CT scan and a poor outcome.<sup>21,22</sup> Since patients with coagulopathy were underrepresented in our study, we could not evaluate this criterion.

In phase 2, the criteria derived from the findings in phase 1 were applied to a separate group of patients with minor head injury to determine their sensitivity in predicting the results of CT. Several stud-

**TABLE 3.** ASSOCIATION BETWEEN THE SEVEN CLINICAL FINDINGS AND CT RESULTS IN 909 PATIENTS WITH MINOR HEAD INJURY (PHASE 2).

FINDING	POSITIVE CT SCAN	NEGATIVE CT SCAN	TOTAL
		no. (%)	
One or more findings present	57 (6.3)	640 (70.4)	697
All seven findings absent	0	212 (23.3)	212
Total	57	852	909

ies have evaluated various combinations of clinical findings as predictors of positive CT scans in patients with minor head injury, but none of the combinations had a sensitivity of 100 percent.<sup>4-7,9,18,27-29</sup> In a study of 2143 patients, 96 percent of those with positive scans were identified on the basis of a finding of nausea, vomiting, or severe headache or evidence of a depressed skull fracture.<sup>5</sup> In a study of 1448 patients, 92 percent of those with positive CT scans were identified on the basis of the presence of cranial soft-tissue injury, evidence of a basilar skull fracture, abnormalities on neurologic examination, or an age over 60 years.<sup>18</sup> In a study of 373 patients,

**TABLE 4.** ABNORMALITIES IN 93 PATIENTS WITH POSITIVE CT SCANS AND SUBSEQUENT HOSPITAL COURSE (PHASES 1 AND 2).

CT FINDINGS*	TOTAL	OBSERVATION ONLY	SURGERY
		no. (%)	
Cerebral contusion	44 (47)	44 (100)	0
Subdural hematoma	35 (38)	33 (94)	2 (6)
Subarachnoid hemorrhage	13 (14)	13 (100)	0
Epidural hematoma	9 (10)	7 (78)	2 (22)
Depressed skull fracture	10 (11)	8 (80)	2 (20)

\*Some patients had more than one abnormality on CT scanning.

90 percent of those with positive CT scans were identified on the basis of the presence of alcohol intoxication, abnormal findings on neurologic examination, or amnesia.<sup>9</sup> Some authors have argued that the failure to identify intracranial lesions in some patients with minor head injury who do not require neurosurgical intervention is an acceptable risk of selective CT scanning,<sup>5,30</sup> but others consider the risk unacceptable because of the potential morbidity associated with missed lesions.<sup>2</sup> In our study, we considered a lower specificity acceptable in order to obtain 100 percent sensitivity in identifying patients with positive CT scans.

In phase 2 of our study, all 57 patients with a positive CT scan had one or more of the seven findings; all 212 patients in whom none of the findings were present had negative scans. The presence of all seven findings had a sensitivity of 100 percent (95 percent confidence interval, 95 to 100 percent) for identifying patients with positive CT scans, and the absence of all seven findings had a negative predictive value of 100 percent. Despite this high sensitivity, the lower limit of the confidence interval indicates the possibility of missing an intracranial lesion that would be detected by CT scanning. Application of the criteria to the patients in phase 2 would have reduced the use of CT by 22 percent. Even a 10 percent reduction in the number of CT scans ordered for patients with minor head injury would result in a substantial decrease in health care expenditures.<sup>9</sup>

Of the 1429 patients in phases 1 and 2 combined, 93 had positive CT scans. Cerebral contusions and subdural hematomas were the most common injuries, a finding that is consistent with the results of other studies.<sup>5,18</sup> Only 6 patients (0.4 percent) underwent neurosurgery, a finding that is also consistent with the results of other studies.<sup>5,6</sup> Since the patients in our study were not followed after discharge, data on possible delayed complications were not available. There have been a few reported cases in which patients with initially normal CT findings were sub-

sequently found to have intracranial lesions.<sup>31,32</sup> However, several groups have concluded that patients with normal findings on both neurologic examination and CT scanning can be safely discharged from the emergency department.<sup>7,12-14,33</sup>

The goal of our study was to derive and validate a set of clinical findings that could be used to identify patients with minor head injury who should undergo CT. Our results suggest that such patients can be identified by the presence of one or more of the following seven findings: headache, vomiting, an age over 60 years, drug or alcohol intoxication, deficits in short-term memory, physical evidence of trauma above the clavicles, and seizure. Although the combination of these findings had a sensitivity of 100 percent for identifying patients with positive CT scans, they should be validated at other centers.

*We are indebted to Hilary Thompson, Ph.D., Ted Glassman, M.D., Michael Volner, M.D., Roy Brandhurst, M.D., and Dauphinot Piper, M.D., for their help with the study.*

## REFERENCES

- Stein SC, Ross SE. The value of computed tomographic scans in patients with low-risk head injuries. *Neurosurgery* 1990;26:638-40.
- Idem*. Mild head injury: a plea for routine early CT scanning. *J Trauma* 1992;33:11-3.
- Harad FT, Kerstein MD. Inadequacy of bedside clinical indicators in identifying significant intracranial injury in trauma patients. *J Trauma* 1992;32:359-61.
- Miller EC, Derlet RW, Kinsler D. Minor head trauma: is computed tomography always necessary? *Ann Emerg Med* 1996;27:290-4.
- Miller EC, Holmes JF, Derlet RW. Utilizing clinical factors to reduce head CT scan ordering for minor head trauma patients. *J Emerg Med* 1997;15:453-7.
- Jeret JS, Mandell M, Anziska B, et al. Clinical predictors of abnormality disclosed by computed tomography after mild head trauma. *Neurosurgery* 1993;32:9-15.
- Nagy KK, Joseph KT, Krosner SM, et al. The utility of head computed tomography after minimal head injury. *J Trauma* 1999;46:268-70.
- Graham ID, Stiell IG, Laupacis A, O'Connor AM, Wells GA. Emergency physicians' attitudes toward and use of clinical decision rules for radiography. *Acad Emerg Med* 1998;5:134-40.
- Reinus WR, Wippold FJ II, Erickson KK. Practical selection criteria for noncontrast cranial computed tomography in patients with head trauma. *Ann Emerg Med* 1993;22:1148-55.
- SPSS for Windows, version 8.0 (statistical package for the social sciences). Chicago: SPSS, 1997 (software).
- Kraus J, Nourjah P. The epidemiology of mild uncomplicated brain injury. *J Trauma* 1988;28:1637-43.
- Livingston DH, Loder PA, Koziol J, Hunt CD. The use of CT scanning to triage patients requiring admission following minimal head injury. *J Trauma* 1991;31:483-7.
- Stein SC, O'Malley KF, Ross SE. Is routine computed tomography scanning too expensive for mild head injury? *Ann Emerg Med* 1991;20:1286-9.
- Shackford SR, Wald SL, Ross SE, et al. The clinical utility of computed tomographic scanning and neurologic examination in the management of patients with minor head injuries. *J Trauma* 1992;33:385-94.
- Kelly AB, Zimmerman RD, Snow RB, Gandy SE, Heier LA, Deck MD. Head trauma: comparison of MR and CT — experience in 100 patients. *AJNR Am J Neuroradiol* 1988;9:699-708.
- Doezema D, King JN, Tandberg D, Espinosa MC, Orrison WW. Magnetic resonance imaging in minor head injury. *Ann Emerg Med* 1991;20:1281-5.
- Nagurney JT, Borczuk P, Thomas SH. Elder patients with closed head trauma: a comparison with nonelder patients. *Acad Emerg Med* 1998;5:678-84.
- Borczuk P. Predictors of intracranial injury in patients with mild head trauma. *Ann Emerg Med* 1995;25:731-6.

19. Duss BR, Boesen T, Krusc KV, Nielsen KB. Prognostic signs in the evaluation of patients with minor head injury. *Br J Surg* 1993;80:988-91.
20. Cook LS, Levitt MA, Simon B, Williams VL. Identification of ethanol-intoxicated patients with minor head trauma requiring computed tomography scans. *Acad Emerg Med* 1994;1:227-34.
21. Stein SC, Young GS, Talucci RC, Greenbaum BH, Ross SE. Delayed brain injury after head trauma: significance of coagulopathy. *Neurosurgery* 1992;30:160-5.
22. Gomez PA, Lobato RD, Ortega JM, De La Cruz J. Mild head injury: differences in prognosis among patients with a Glasgow Coma Scale score of 13 to 15 and analysis of factors associated with abnormal CT findings. *Br J Neurosurg* 1996;10:453-60.
23. Lee ST, Lui TN. Early seizures after mild closed head injury. *J Neurosurg* 1992;76:435-9.
24. Vollmer DG, Dacey RG Jr. The management of mild and moderate head injuries. *Neurosurg Clin North Am* 1991;2:437-55.
25. Feuerman T, Wackym PA, Gade GF, Becker DP. Value of skull radiography, head computed tomographic scanning, and admission for observation in cases of minor head injury. *Neurosurgery* 1988;22:449-53.
26. Moran SG, McCarthy MC, Uddin DE, Poelstra RJ. Predictors of positive CT scans in the trauma patient with minor head injury. *Am Surg* 1994;60:533-5.
27. Madden C, Witzke D, Sanders A. High-yield selection criteria for cranial computed tomography after acute trauma. *Acad Emerg Med* 1995;2:248.
28. Hsiang JN, Yeung T, Yu AL, Poon WS. High-risk mild head injury. *J Neurosurg* 1997;87:234-8.
29. Stein SC, Spettell C, Young G, Ross SE. Limitations of neurological assessment in mild head injury. *Brain Inj* 1993;7:425-30.
30. Mohanty SK, Thompson W, Rakower S. Are CT scans for head injury patients always necessary? *J Trauma* 1991;31:801-4.
31. Brown FD, Mullan S, Duda EE. Delayed traumatic intracerebral hematomas: report of three cases. *J Neurosurg* 1978;48:1019-22.
32. DiRocco A, Ellis SJ, Landes C. Delayed epidural hematoma. *Neuroradiology* 1991;33:253-4.
33. Taheri PA, Karamanoukian H, Gibbons K, Waldman N, Doerr RJ, Hoover EL. Can patients with minor head injuries be safely discharged home? *Arch Surg* 1993;128:289-92.

---

FULL TEXT OF ALL *JOURNAL* ARTICLES ON THE WORLD WIDE WEB

---

Access to the complete text of the *Journal* on the Internet is free to all subscribers. To use this Web site, subscribers should go to the *Journal's* home page ([www.nejm.org](http://www.nejm.org)) and register by entering their names and subscriber numbers as they appear on their mailing labels. After this one-time registration, subscribers can use their passwords to log on for electronic access to the entire *Journal* from any computer that is connected to the Internet. Features include a library of all issues since January 1993, a full-text search capacity, a personal archive for saving articles and search results of interest, and free software for downloading articles so they can be printed in a format that is virtually identical to that of the typeset pages.

---