

Case Series: Safety and Effectiveness of 3-Level Lumbar Percutaneous Decompression with an Interspinous Spacer



Author: Casey Murphy, M.D., F.A.A.P.M.R., D.A.A.P.M., Co-Author: E. Thomas Fincke, M.D., LSU Pain Medicine Chief Fellow

LSU Health Sciences Center in New Orleans and Veterans Affairs Medical Center of New Orleans



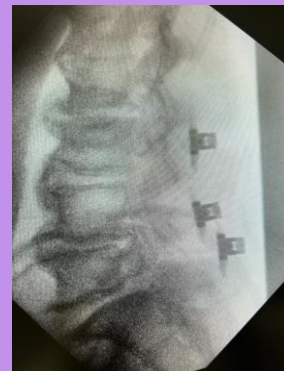In this case series, we review 4 patients who had 3 levels of lumbar spinal stenosis treated with Vertiflex at the Veterans Affairs Medical Center of New Orleans. All patients did not benefit from medications, therapy, or injections/RFA. All patients were seen by neurosurgery and opted out of laminectomy +/- fusion.



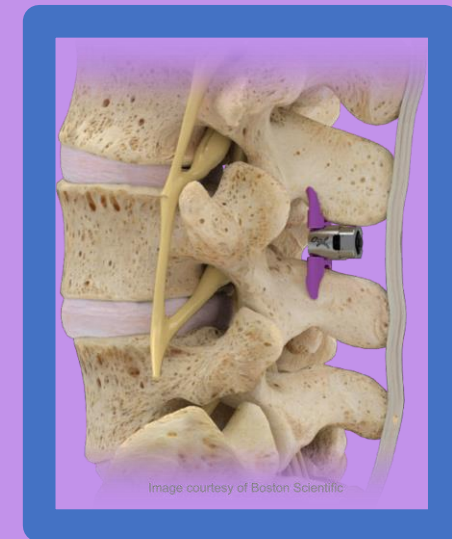
Patient A was an 80-year-old male with L2-3 severe, L3-4 mild, and L4-5 moderate stenosis and pain for 25 years. 4-months post-operatively, the patient would not recommend this procedure for a fellow veteran with the same symptomatology, reporting he experienced zero relief from his pain which was still rated as a 10/10. It should be noted that post-operatively he stated his pain was always predominantly in the back and not the legs; this description is different from the chart.

Patient B was a 72-year-old male with L2-3 severe, L3-4 severe, L4-5 severe stenosis with pain for more than 10 years. 2-months post-operatively, he states that he would recommend this procedure for a fellow veteran with the same symptoms as his leg pain was decreased by 50% from a 10/10 to a 5/10. Additionally, his distance of ambulation post-operatively was increased from 2.5 blocks to 3.5 blocks.

Patient C was a 77-year-old male with L2-3 moderate, L3-4 severe, L4-5 severe stenosis with pain for 20 years. One-month post-operatively, he stated he would recommend this procedure for a fellow veteran with the same symptoms as it decreased his left leg pain from a 9/10 to a 1/10 and his right leg pain from a 9/10 to a 6/10. He also stated he had doubled his walking distance from 75 feet to 150 feet.



Patient D was a 77-year-old male with L2-3 severe, L3-4 severe, and L4-5 severe stenosis with pain for 10 years. 10-day post-operatively, he would recommend this procedure to a fellow veteran with the same symptoms and reports his pain was decreased from a 10/10 to a 4/10 post-operatively. He also states his ambulation distance was doubled, from 0.5 block to 1 block post-operatively.



Results: 3-level IPD has been shown to increase ambulation distance and decrease leg pain in 3 out of 4 veterans with lumbar spinal central stenosis with neurogenic claudication. There were no complications noted in these four patients.

Conclusion: In a select population, 3-level percutaneous lumbar decompression appears to be safe and effective.