

Stage II Endometrial Carcinoma with False Positive Para-aortic Lymphadenopathy: the Importance of Pretest Probability

John Cooper BS, Dr. Agustin A. Garcia MD

Department of Internal Medicine, Section of Hematology and Oncology Louisiana State University Health Sciences Center, New Orleans, LA



Introduction

- Endometrial carcinoma is the most common female pelvic malignancy in the United States
- Early and accurate assessment of disease status of gynecologic malignancies is vital for optimal treatment planning and outcome prediction
- PET/CT is a very sensitive and specific modality for the staging of endometrial carcinoma
- Pre-test probability should always be factored into the interpretation of PET/CT scans when staging endometrial carcinoma

Endometrial Carcinoma Staging

Stage	Description
I	Tumor confined to the uterus
IA	<50% invasion of the myometrium
IB	≥50% invasion of the myometrium
II	Tumor invades the cervical stroma but does not extend beyond the uterus
III	Local or regional spread of tumor
IIIA	Serosal or adnexal invasion
IIIB	Vaginal or parametrial involvement
IIIC	Metastasis to pelvic or paraaortic lymph nodes
IIIC1	Pelvic lymph node involvement
IIIC2	Para-aortic lymph node involvement (with or without pelvic nodes)
IV	Extension to the pelvic wall, lower one-third of the vagina, or hydronephrosis or nonfunctioning kidney
IVA	Invasion of bladder or bowel mucosa
IVB	Distant metastases, including abdominal, or involvement of inguinal lymph nodes

Case Presentation

- This is a 61-year-old female with a history of intermittent vaginal spotting since her early 50's. On physical exam, normal vaginal atrophy was observed, and bi-manual recto-vaginal exam showed normal-sized uterus without adnexal masses or nodularity
- Pap-smear with dilation and curettage revealed endometrial carcinoma, endometrioid type with squamous differentiation
- Pathology showed a grade 1 endometrioid carcinoma with greater than 50% myometrial invasion. All 18 pelvic lymph nodes were negative meriting a diagnosis of Stage II endometrial carcinoma. Vaginal cuff brachytherapy, a non-morbid treatment, was offered as adjuvant therapy
- Staging PET/CT scan showed a hypermetabolic left para-aortic lymph node at the renal level suspicious for active neoplastic disease
- Treatment plan was changed to extended field radiation and systemic chemotherapy; a treatment associated with significantly more toxicity, but this uncommon presentation required more testing before initiating treatment
- CT-guided biopsy of the left para-aortic lymph node was performed and showed no malignant cells
- Follow-up PET/CT three months later showed persistent, unchanged metabolically active left para-aortic lymphadenopathy
- The scan also showed persistent chronic nephrolithiasis and obstructive uropathy of the left kidney with severe parenchymal atrophy
- Uteroscopic stone extraction with holmium laser lithotripsy and stent placement was performed. Patient remains alive and well with no evidence of cancer recurrence 30 months after surgery

PET/CT Imaging

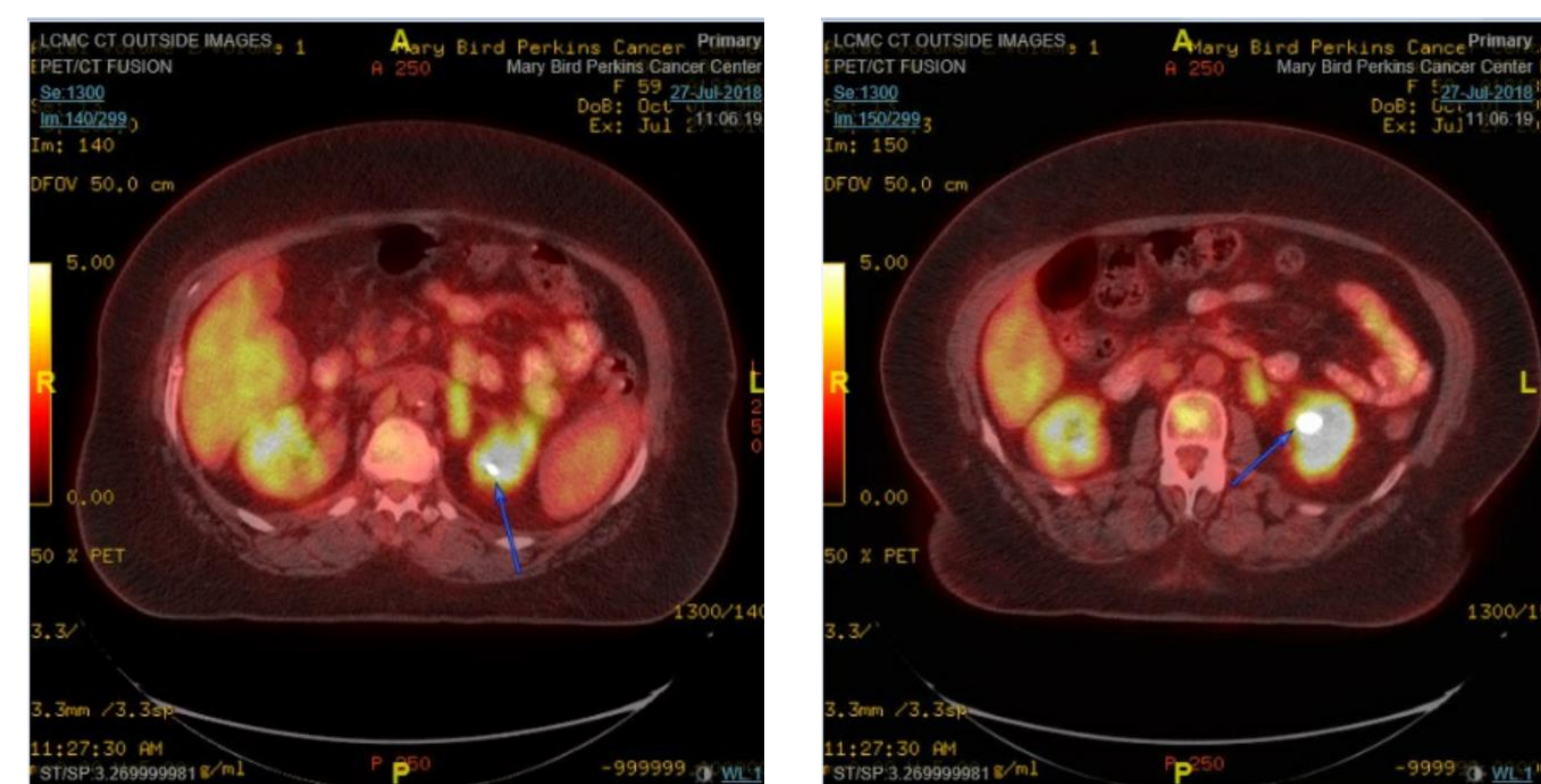


Figure 1

Figure 2

Figure 1 and 2 show a PET/CT with increased metabolic activity at the left renal pole due to nephrolithiasis

Discussion

- This case reports highlights the importance of using the pre-test probability when interpreting test results
- PET/CT scan is a highly sensitive and specific in endometrial cancer. However, para-aortic lymph node metastasis without pelvic lymph node metastasis from endometrial carcinoma is very rare (low pre-test probability)
- A study focused on evaluation of resected pelvic and para-aortic lymph nodes found that only 1.2% (2/171) of patients had isolated para-aortic lymph node metastasis (Chiang AJ).
- Another study of 14,398 patients found the incidence of isolated para-aortic lymph node metastasis to be 1.6% (Nasioudis D)
- This low pre-test probability raised the concern about the PET/CT findings
- The patient was spared the toxicity of unnecessary chemotherapy and extended field radiation
- The patient was spared the toxicity of unnecessary chemotherapy and extended field radiation
- The team concluded that the findings on PET scan were related to the inflammatory process in the kidney associated with the nephrolithiasis and chronic obstructive uropathy.

References

- Chiang AJ, Yu KJ, Chao KC, Teng NN. The incidence of isolated para-aortic nodal metastasis in completely staged endometrial cancer patients. *Gynecol Oncol.* 2011 Apr;121(1):122-5. doi: 10.1016/j.ygyno.2010.11.026. Epub 2010 Dec 30. PMID: 21194737.
- Nasioudis D, Holcomb K. Incidence of isolated para-aortic lymph node metastasis in early stage endometrial cancer. *Eur J Obstet Gynecol Reprod Biol.* 2019 Nov;242:43-46. doi: 10.1016/j.ejogrb.2019.09.003. Epub 2019 Sep 9. PMID: 31557556.