

Introduction

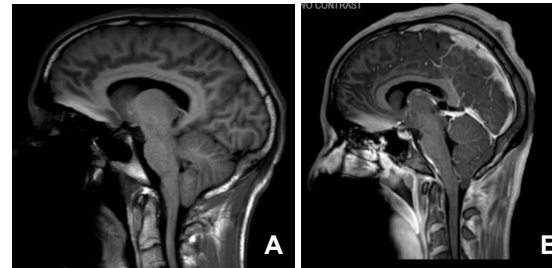
- *Cryptococcus neoformans* is a fungus that is commonly found in the environment worldwide
- Cryptococcal meningitis is a fungal infection causing inflammation of the membranes covering the brain and spinal cord.
- Worldwide, nearly 220,000 new cases of cryptococcal meningitis occur each year, resulting in an estimated 181,000 deaths.
- 90% of Cryptococcal Meningoencephalitis cases are present in immunocompromised patients with AIDS¹.
- In the remainder of cases, patients are most often immunocompromised from other conditions, including steroid use, malignancy, rheumatologic diseases, and use of immunosuppressive medications.

Case

- We present a case of a young, otherwise immunocompetent patient, with history of Chiari I malformation and recent COVID-19 infection, found to have cryptococcal meningitis.
- The patient presented with syncope following two weeks of headaches, generalized body aches and weakness after COVID-19 diagnosis, and was found to have an isolated CN VI palsy.
- Head imaging revealed new right caudate infarcts, and a cerebellar tonsillar descent compatible with history of Chiari I malformation.
- Initial lumbar puncture was deferred due to congenital brain herniation.
- Over the next few days, patient continued to show increasing neurological deficits such as truncal ataxia and increased mood instability.
- The patient was transferred to the Intensive Care Unit, and LP was obtained under special neuro-critical care direction.

- Due to increased opening pressures of up to 33 cm H2O and yeast on gram stain, cryptococcus was suspected and later confirmed. HIV/hep C/autoimmune workup labs were normal.
- Although anti-fungal therapy was initiated, the patient continued to deteriorate, leading to cardiac arrest, intubation, and placement of lumbar drain.
- He unfortunately did not demonstrate neurologic recovery following arrest and progressed to brain death.

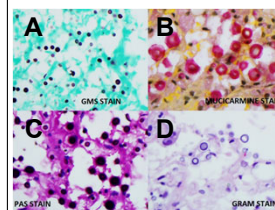
Imaging



A- Day 2- MRI Brain w/o contrast demonstrating 9mm cerebellar tonsillar descent compatible with history of Chiari I malformation. Evidence diffuse sulcal effacement and mild relative prominence of lateral ventricles concerning for degree of obstruction at foramen magnum

B- Day 9- MRI Brain w/o contrast demonstrating diffuse cortical edema and abnormal signal throughout the sulci consistent with meningoencephalitis

Pathology



- 4 different commonly used stains for cryptococcus²
- A- GMS Stain
- B- Mucicarmine Stain
- C- PAS Stain
- D- Gram Stain

Discussion

- While cryptococcal meningoencephalitis is largely a disease of the immunocompromised, studies have shown that in 22-35% of patients, there is still no identified underlying condition³
- Severe COVID-19 infections can lead to increased risk of fungal infections in hospitalized patients, however our patient had no symptoms of COVID-19 and his PCR upon hospitalization was negative.
- This patient also had known Chiari I malformation, diagnosed in 2018. While a handful of case reports have associated Chiari 1 malformations with a variety of inflammatory and infectious pathologies, the role played by a chiari malformation in these reports is unclear⁴⁻⁶.
- This patient's diagnosis may have been delayed due to inability to obtain cerebrospinal fluid via lumbar puncture due to his Chiari I malformation. Some relative contraindications to lumbar punctures include Chiari malformations due to increased susceptibility to tonsillar herniation following even small amount CSF removal and this has been described in some case reports⁷.
- In conclusion, the patient's only known possible risk factors include recent COVID-19 infection and Chiari Malformation. Oftentimes delay in treatment in immunocompetent individuals can lead to worse outcomes.

References

- 1- <https://www.cdc.gov/fungal/diseases/cryptococcosis/neoformans/index.html>
- 2- <https://link.springer.com/article/10.1007/s12288-020-01271-2#figure2>
- 3-Kienburanukul, S., Wirojananagoon, S., Prachartam, R., & Sungkanaporn, S. (2006). Cryptococcosis in human immunodeficiency virus-negative patients. *International Journal of Infectious Diseases*, 10(1), 72-78.
- 4-Eken V, Nilufer Yalçındağ F, Batıoğlu F, İşıkay CT. A case of bilateral uveitis and optic disc swelling with Chiari I malformation. *Saudi J Ophthalmol*. 2012 Jul;26(3):335-7. doi: 10.1016/j.sjo.2012.01.007. Epub 2012 Feb 6. PMID: 22861015. PMCid: PMC372656.
- 5-Solomou, E.K., Krepis, A., Kotsarini, C. et al. Co-existence of Chiari malformation type I and Epstein-Barr virus meningoencephalitis in a 2-year-old child: case report and review of the literature. *Neuroradiology* 47, 78–82 (2005). <https://doi.org/10.1007/s00234-004-1317-9>
- 6-Hochman, M.S. and Kobetz, S.A. (1981). Adult Arnold-Chiari malformation type I associated with an aseptic meningitis reaction. *Ann Neurol*. 10: 486-497. <https://doi.org/10.1002/ana.1100201022>
- 7-Erby SH, O'Callaghan MG, Bhadolia R. Is lumbar puncture contraindicated in patients with Chiari I malformation? *AJNR Am J Neuroradiol*. 2005 Apr;26(4):985. PMID: 15814957; PMCID: PMC77977140